



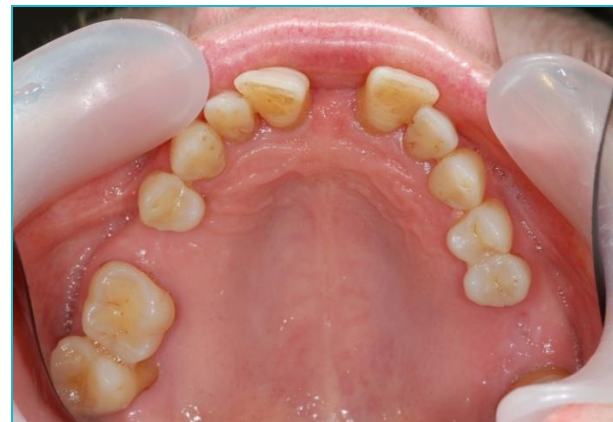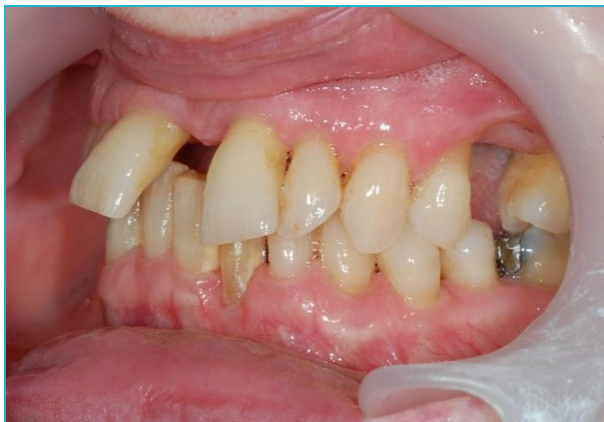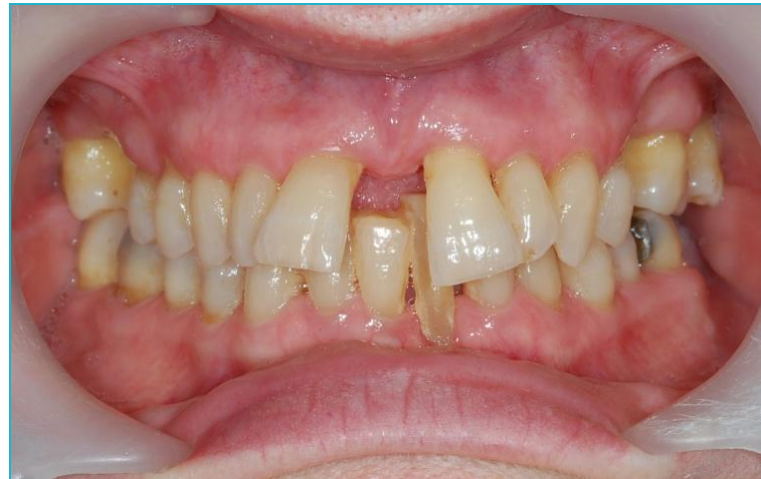*Confidence in your smile*

presents

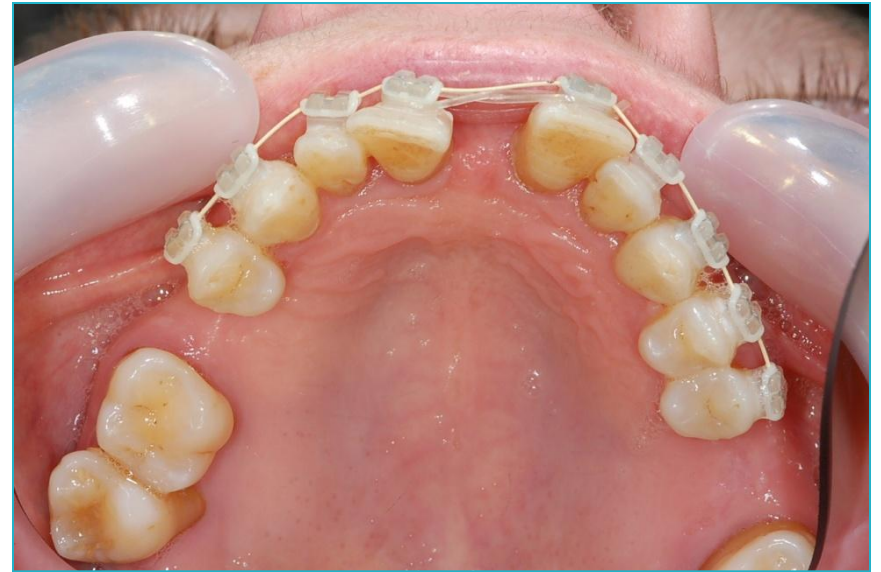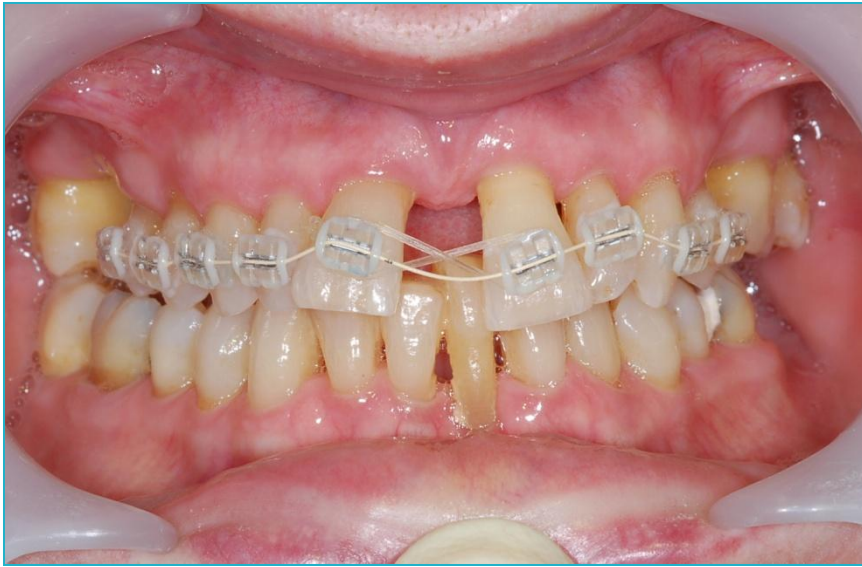**Ormco** Spirit<sup>®</sup> MB



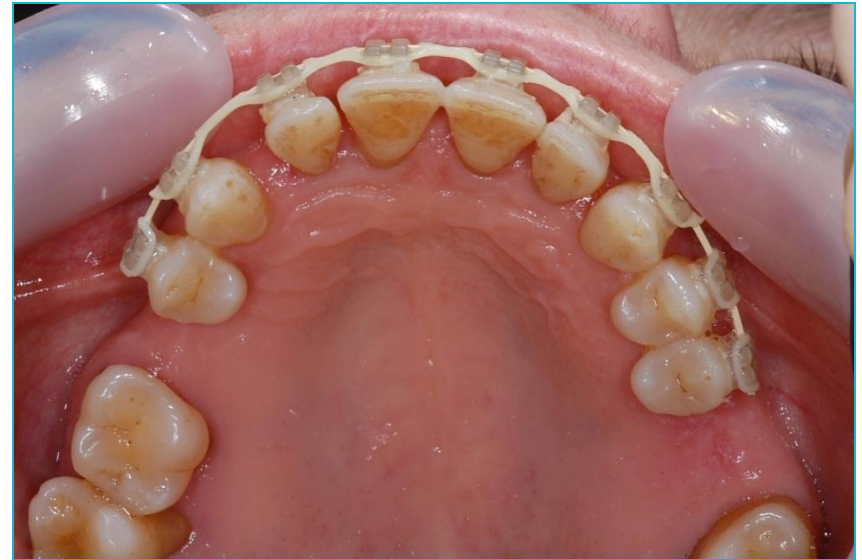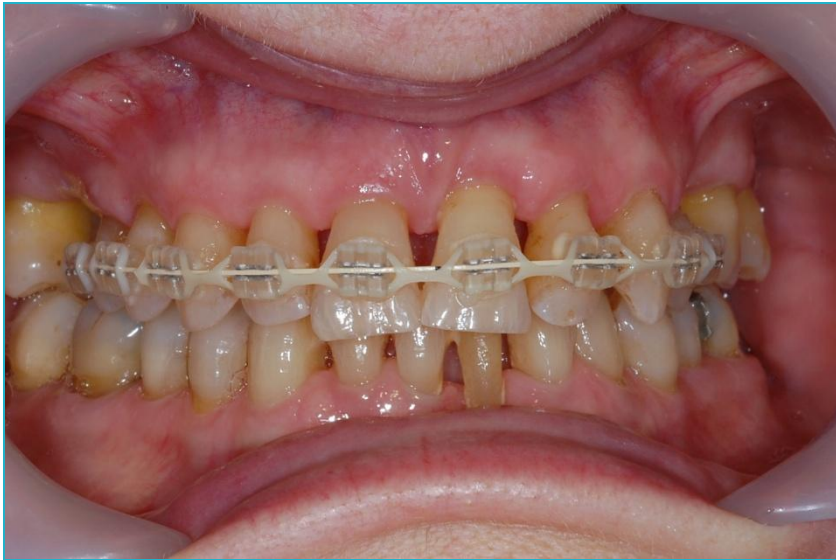
**Marianne presented at 61 years young with upper incisors which had drifted badly, due to periodontal disease.**



**Dr David Horobin used an aesthetic upper fixed brace to close the midline gap**

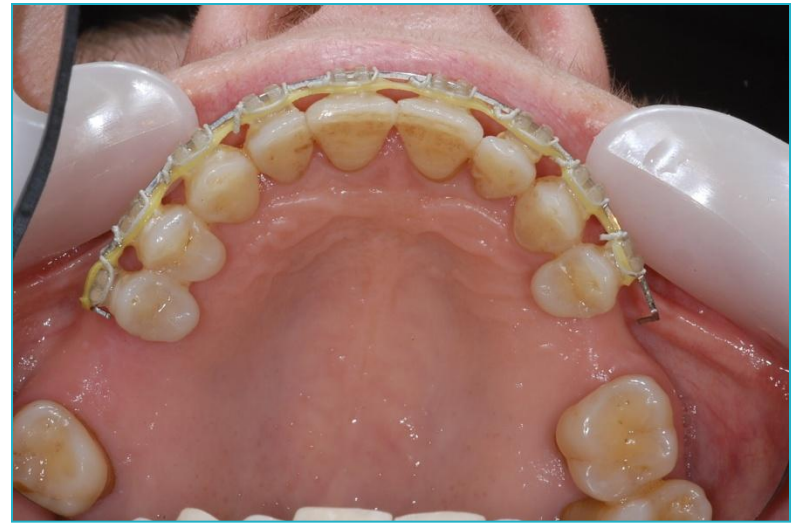
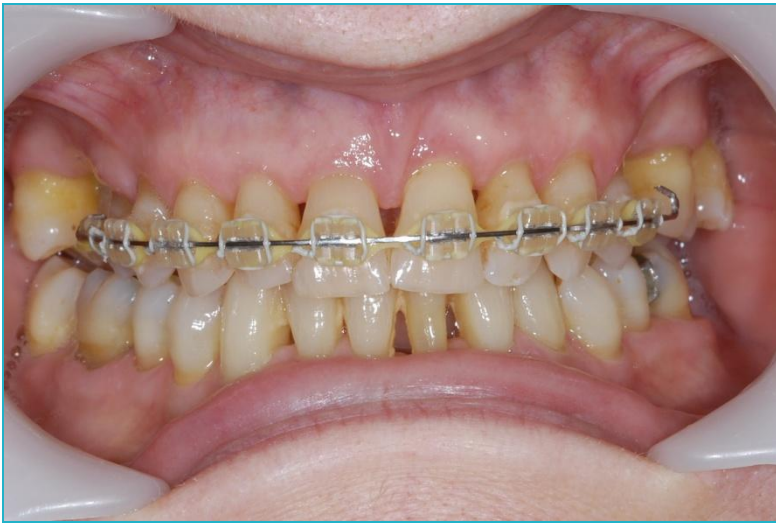
## Progress after 5 months



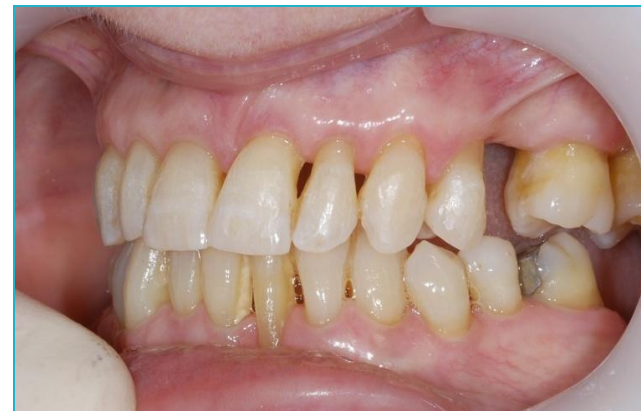
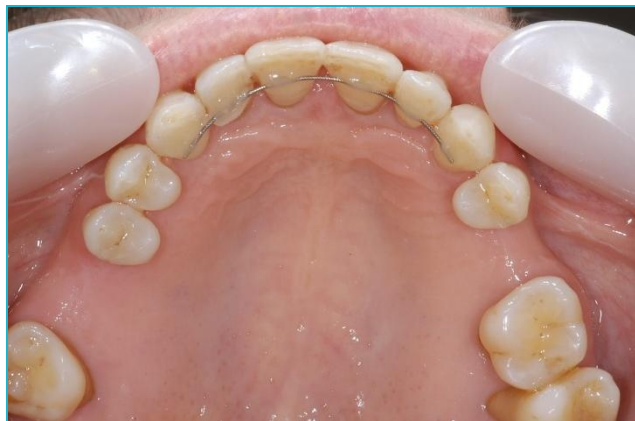
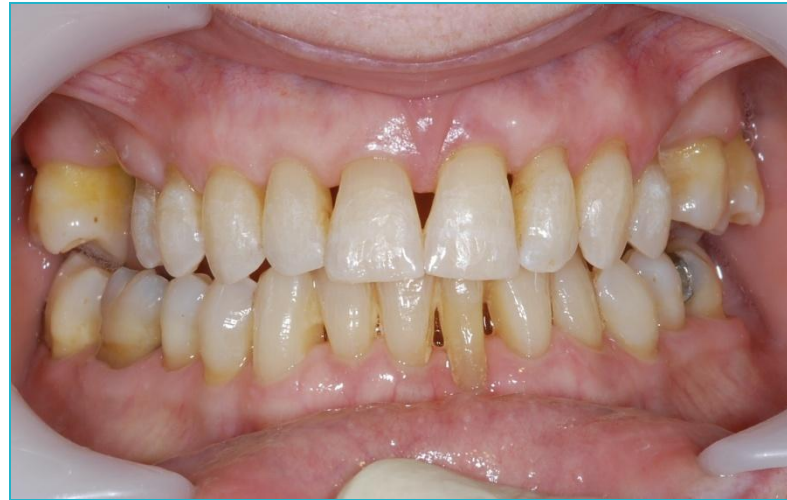**All anterior space closed**

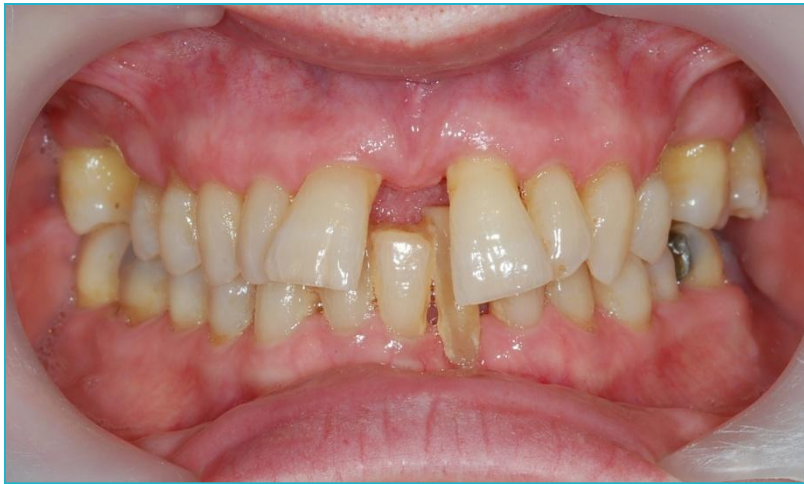



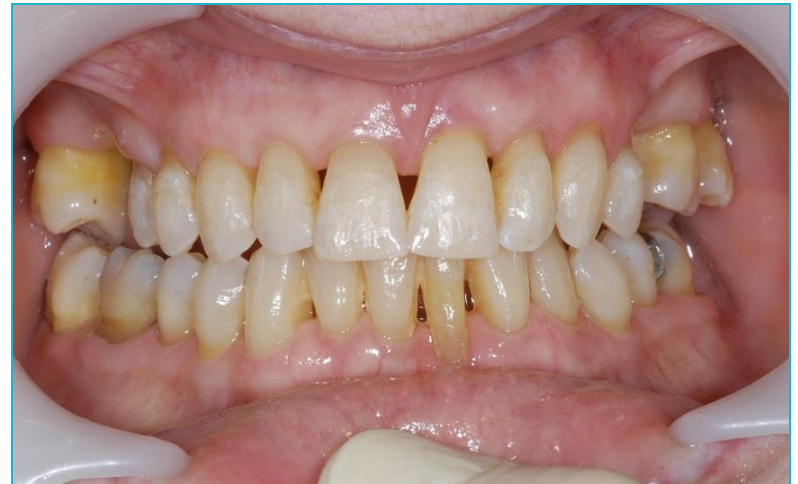## Finished Results after 14 months



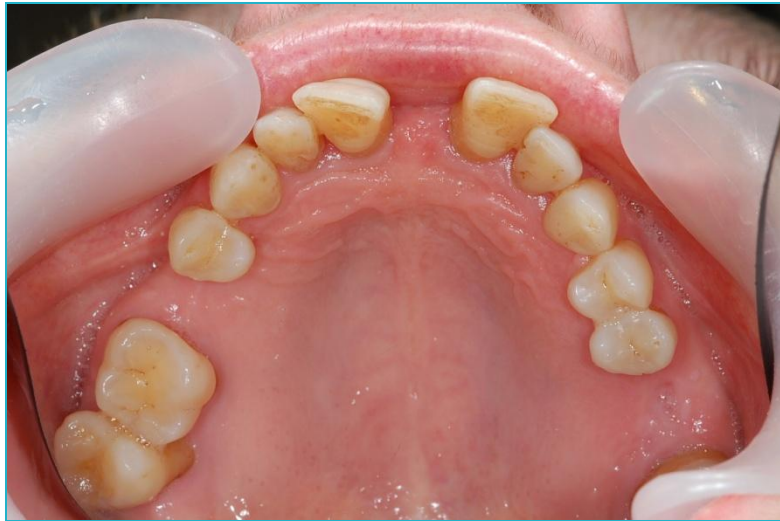**Before**



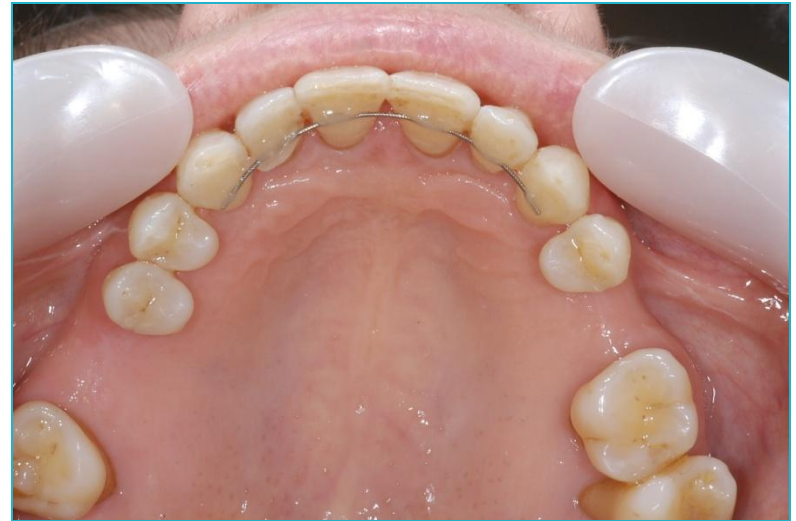**After**



**Before**



**After**



**Note the fixed retainer**



**Before**



**After**



**Marianne was delighted with her new smile**

# Smile Created By



*Confidence in your smile*