



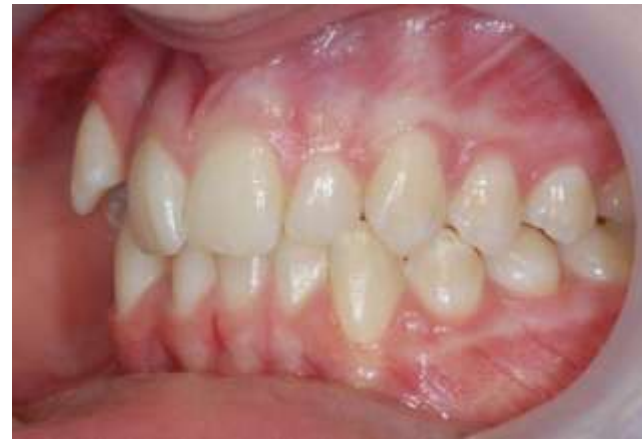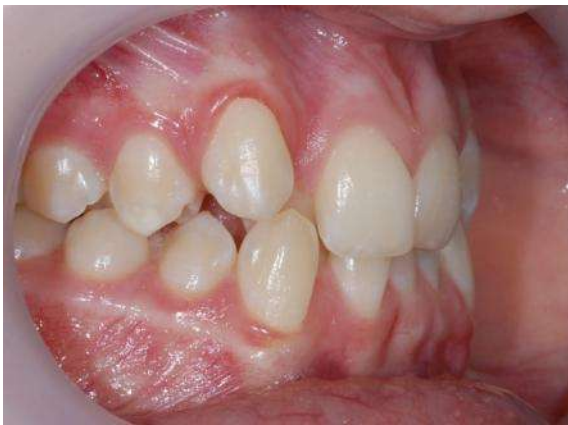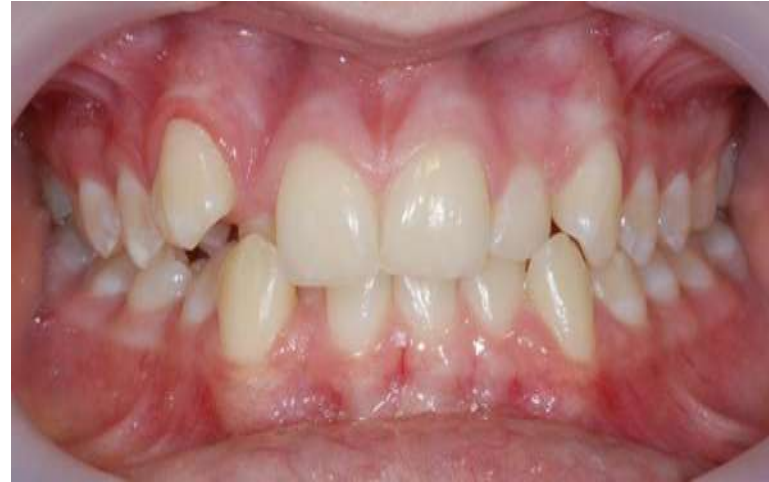Confidence in your smile

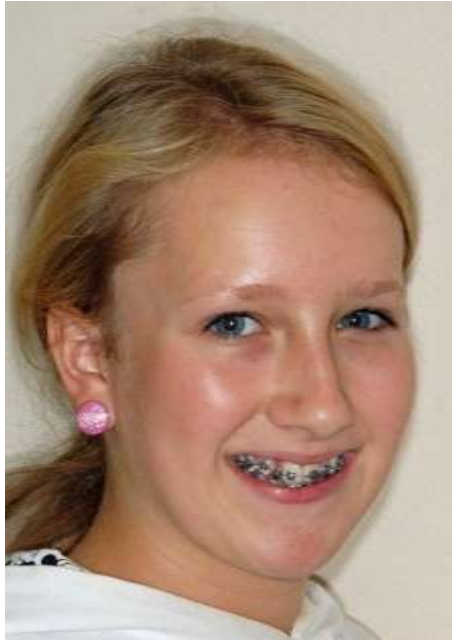presents

DAMON³_{MX}

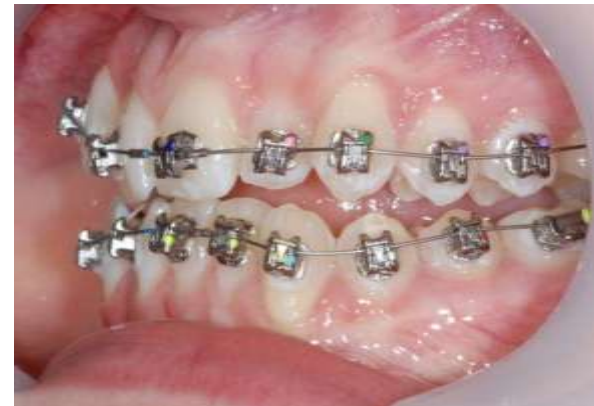
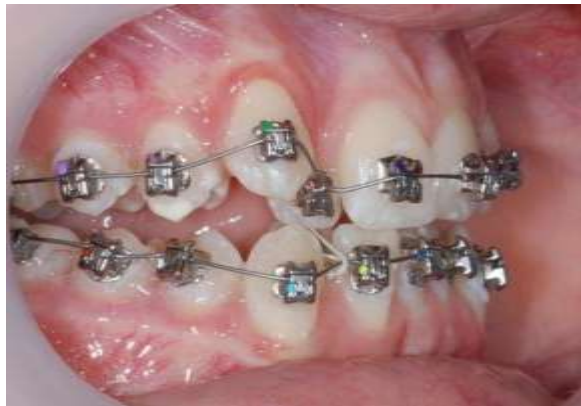
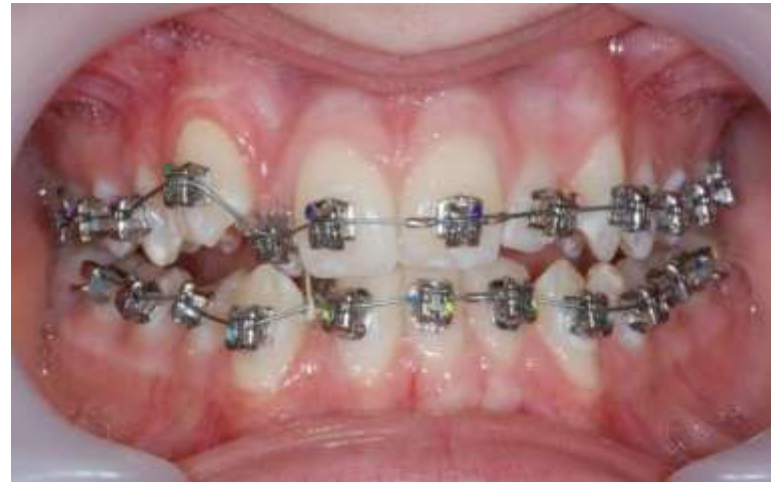Natasha presented at 12 years of age with a crowded dentition

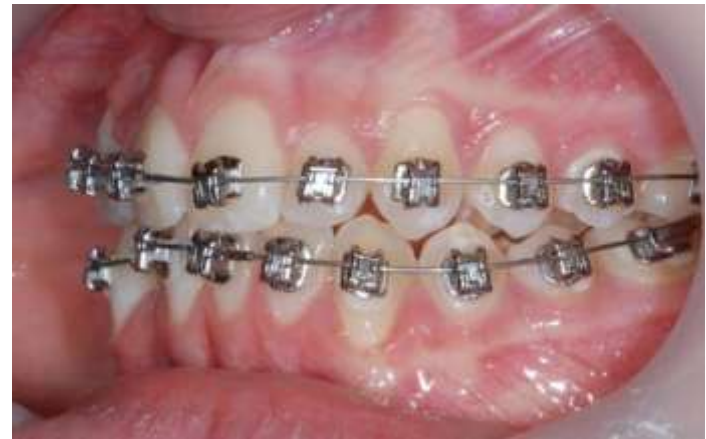
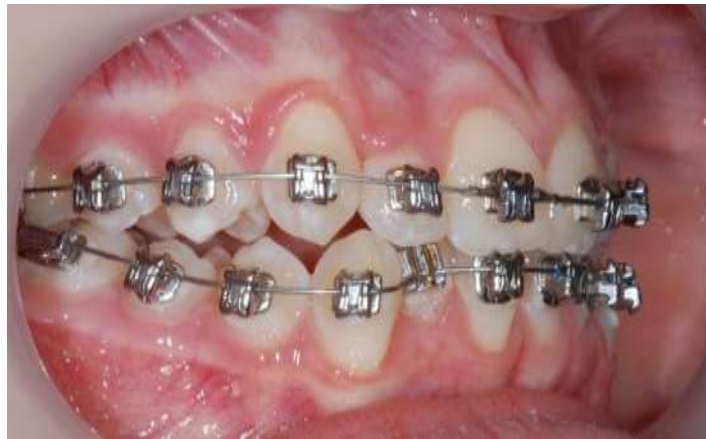
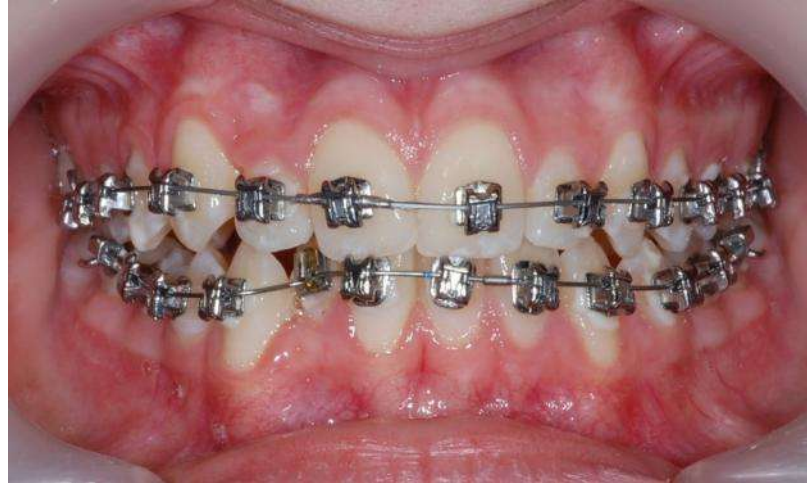

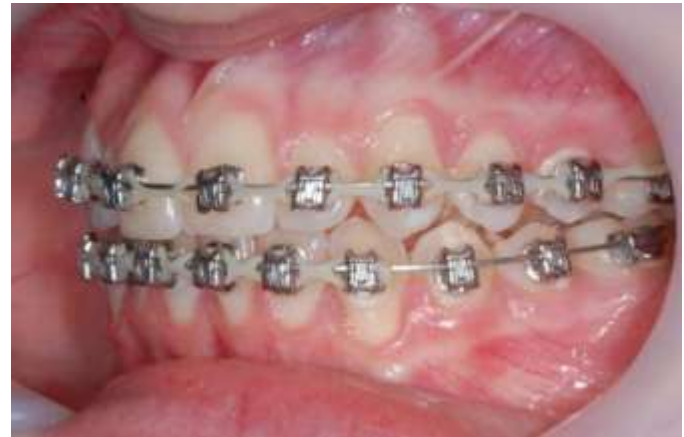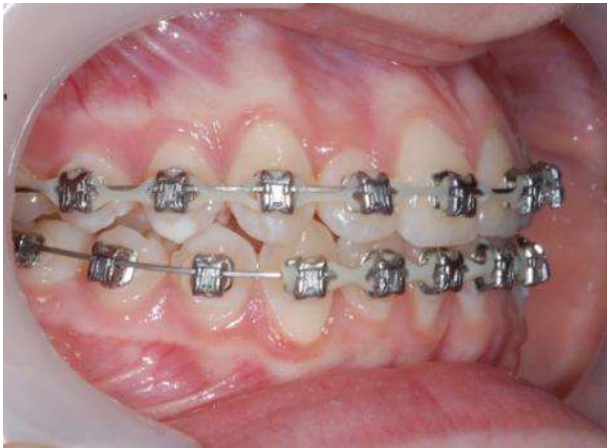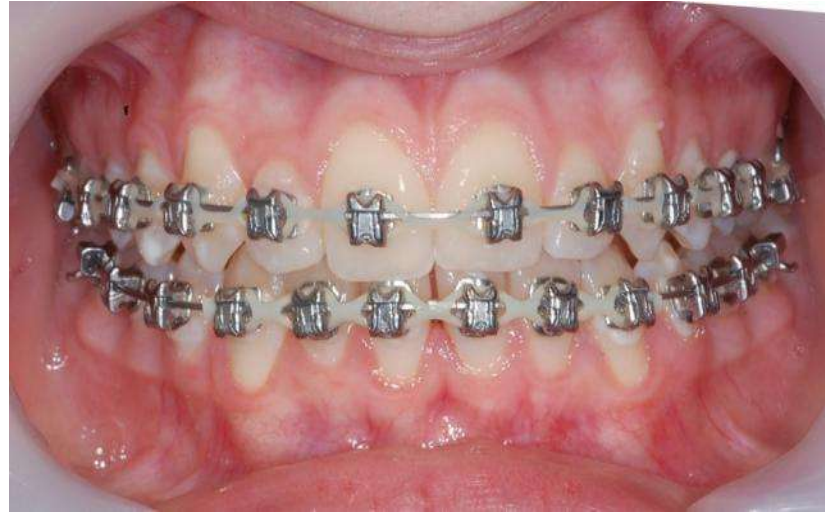
Dr David Horobin treated the case with the Damon
3_{MX} Brace without extractions



Progress after 3 months

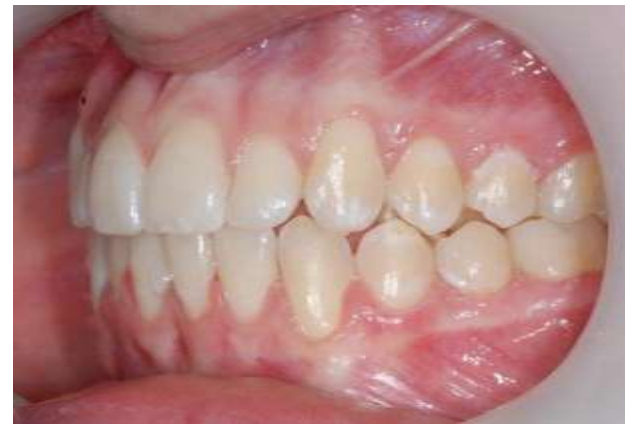
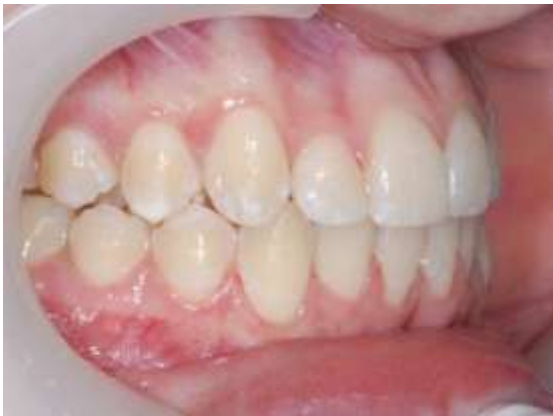
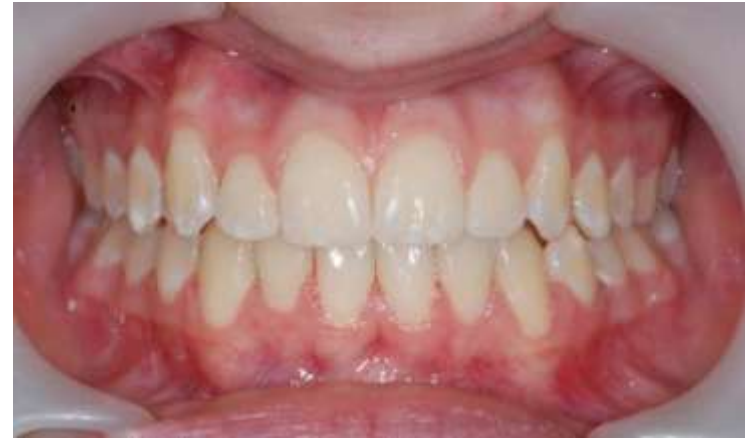Progress after 12 months

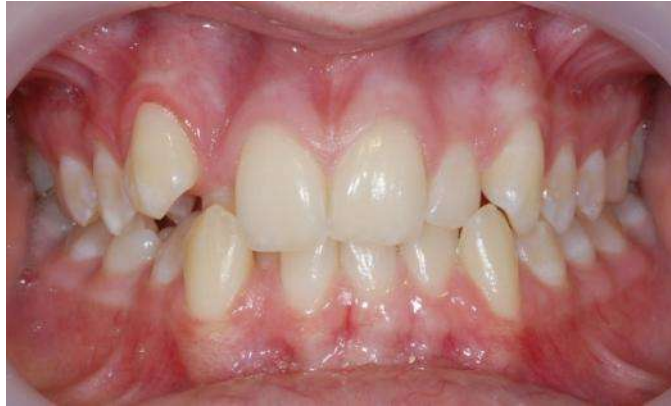



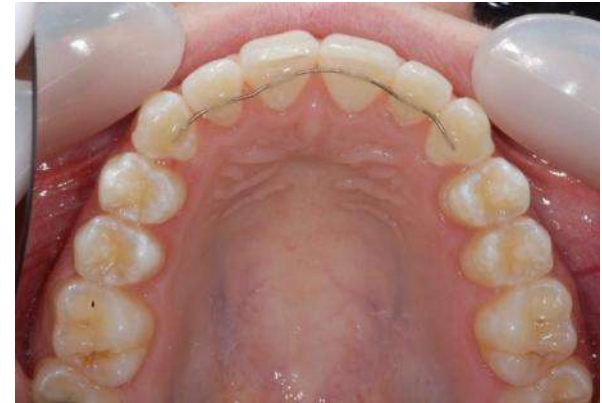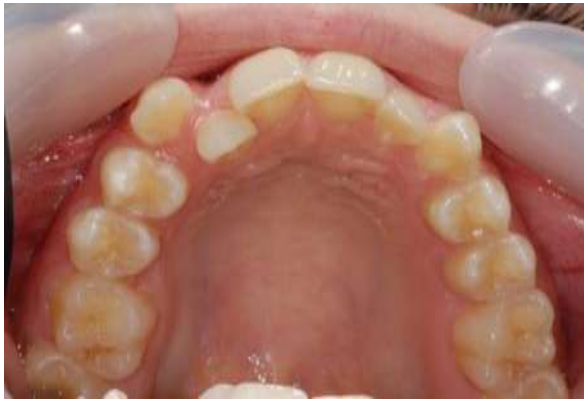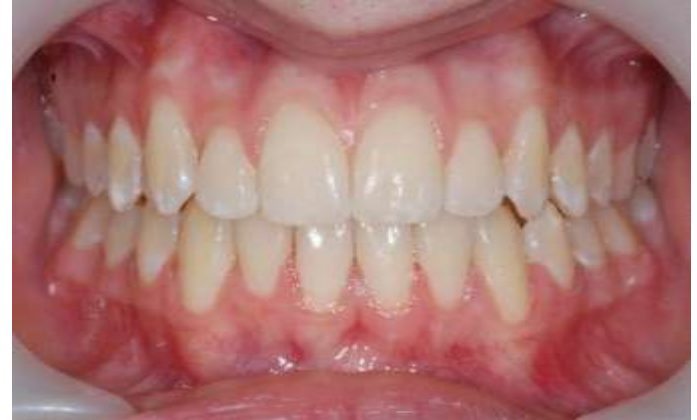Finished Smile after 14 months



Before

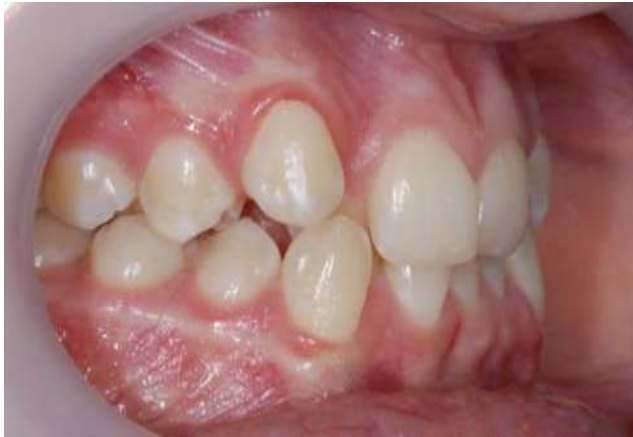

After

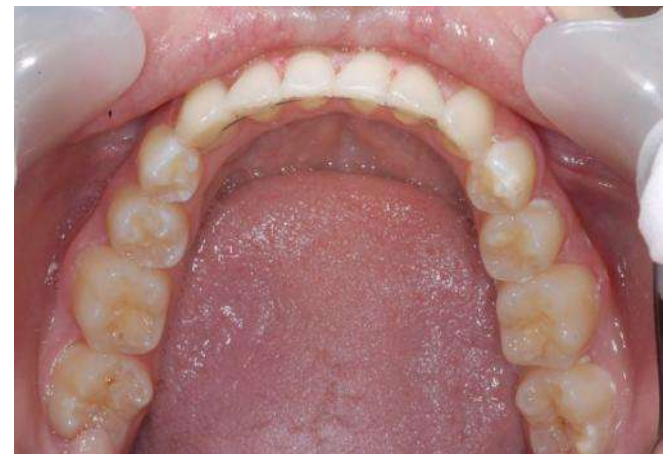
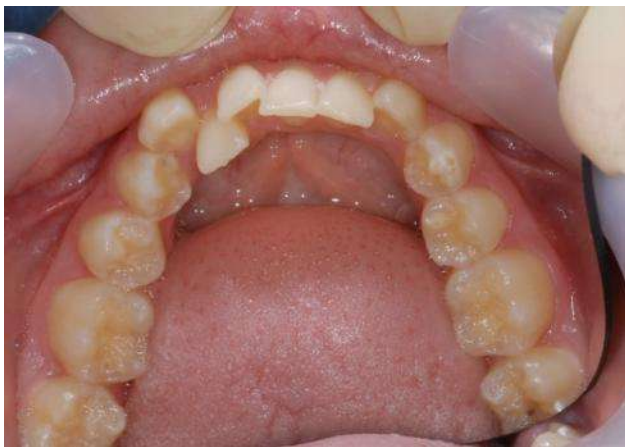
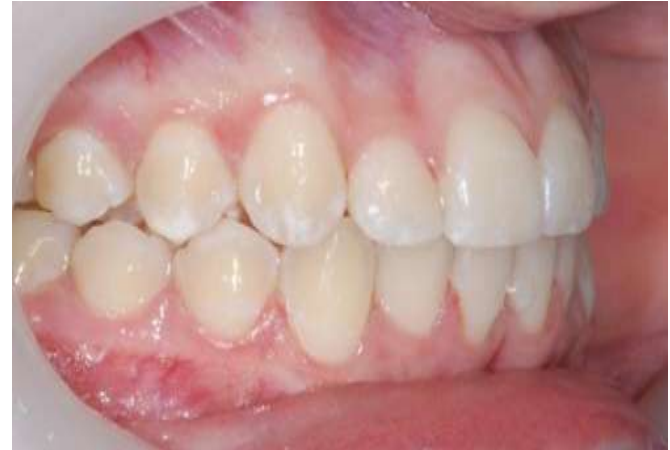Note the fixed retainer

Before

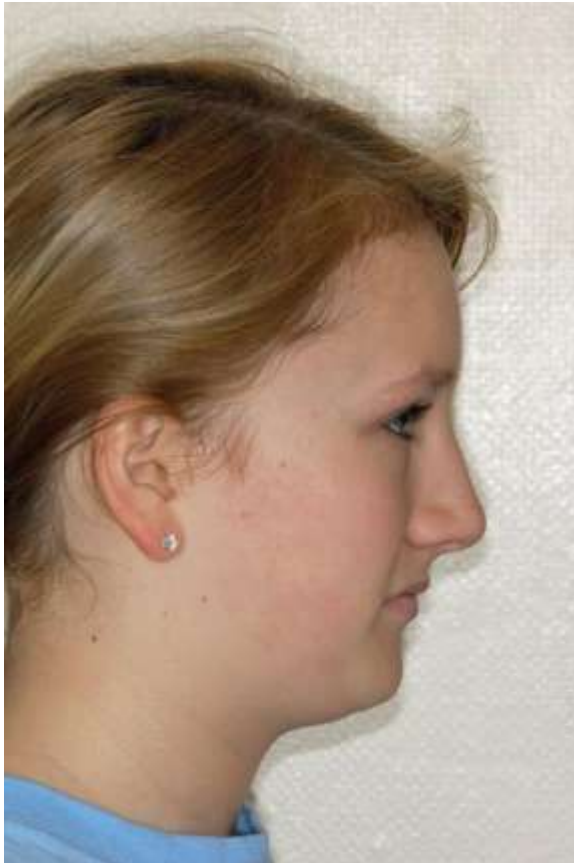

After



14 months treatment, without extractions

Before

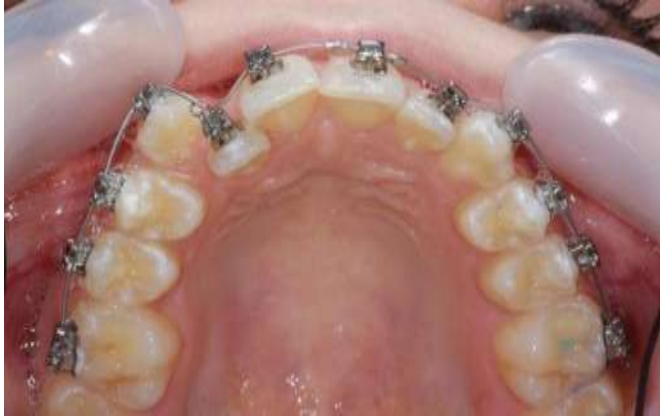

After

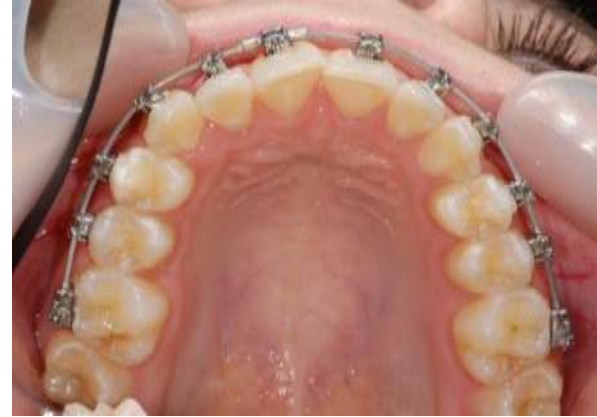

Note the improved facial profile

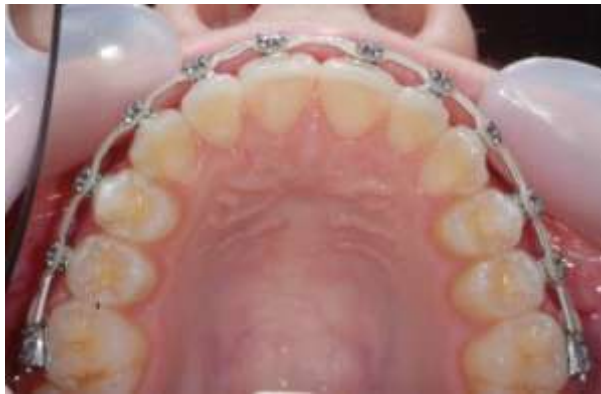Upper arch sequence



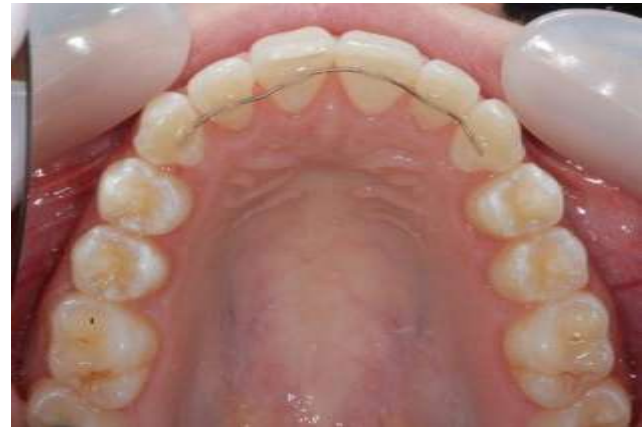1



2



3



4



Created by



Confidence in your smile