

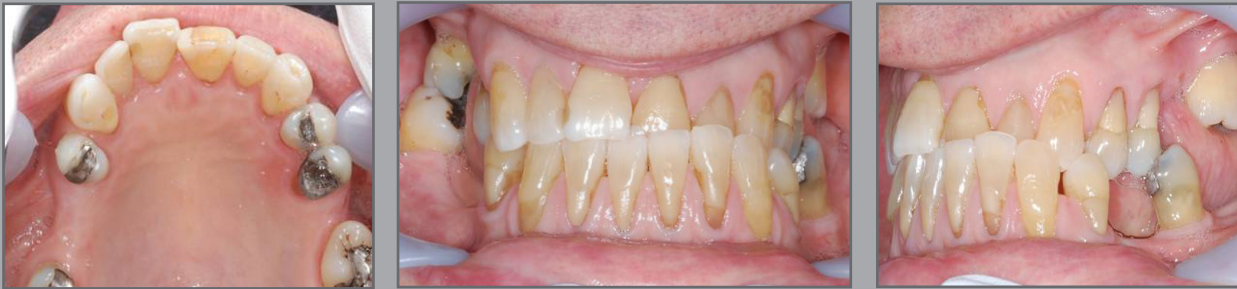## Ormco Spirit MB

At 70 years of age, Mitchell was concerned about his anterior bite.

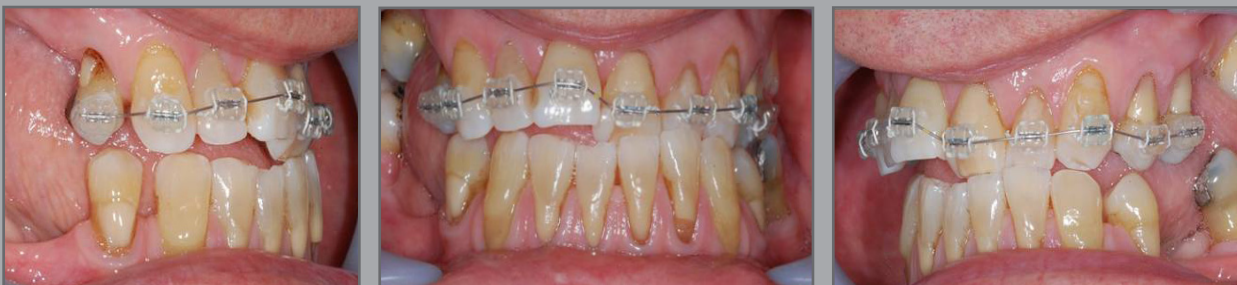Treatment was complete after 12 months using the Ormco Spirit MB system.



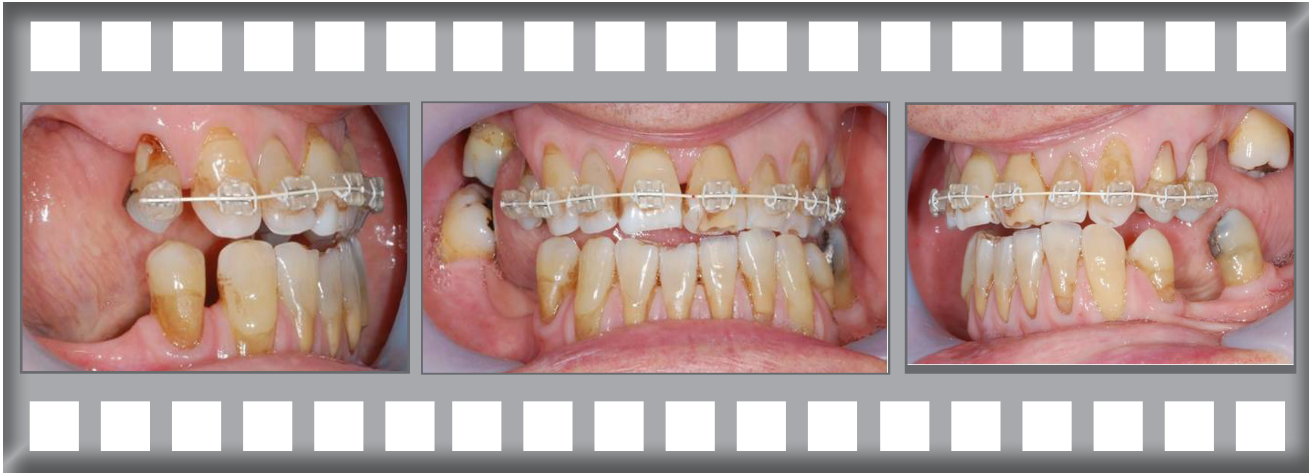*Mitchell*



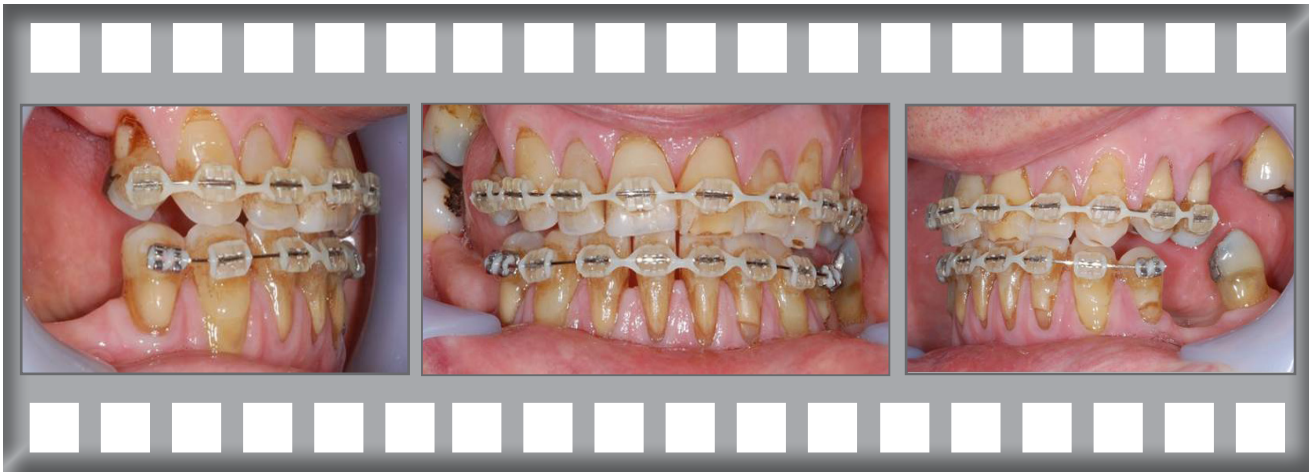Dr Horobin used the Spirit fixed brace to improve the bite.



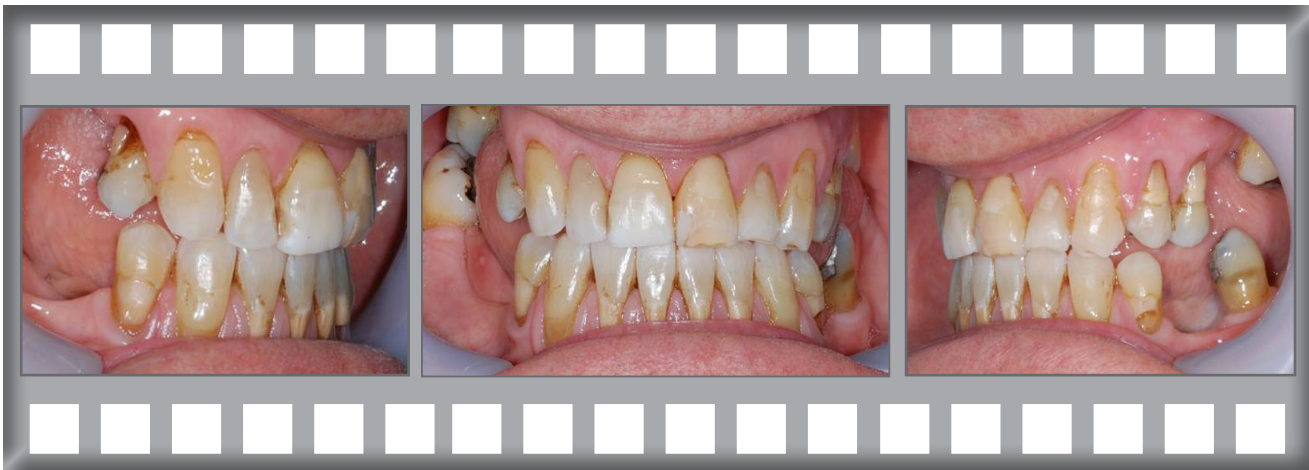After 2 months progress.



Treatment after 8 months.




Treatment complete after 12 months.



Mitchell was delighted with his result.

Treatment was complete after 12 months using the Ormco Spirit MB system.

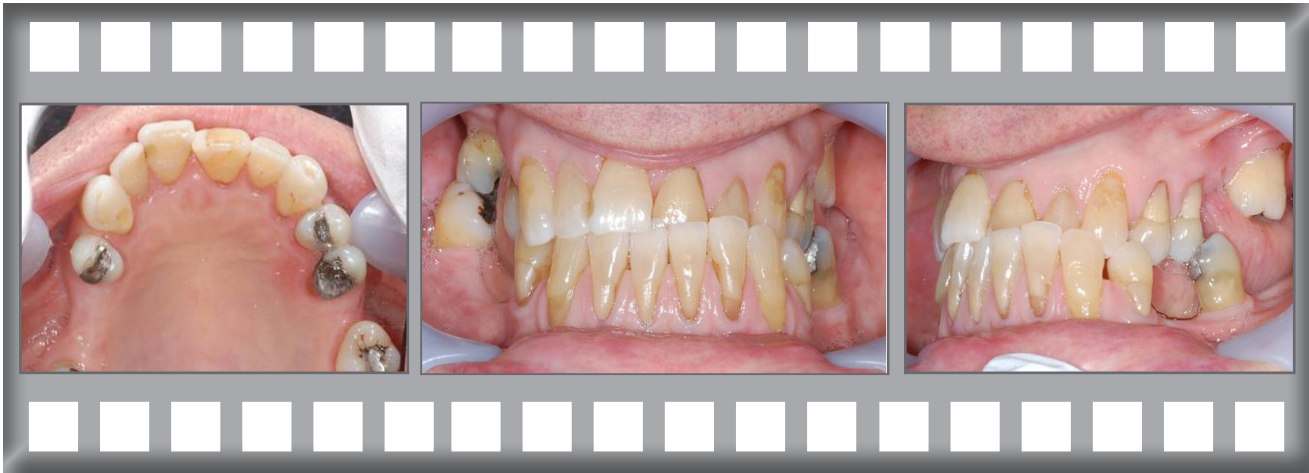

After

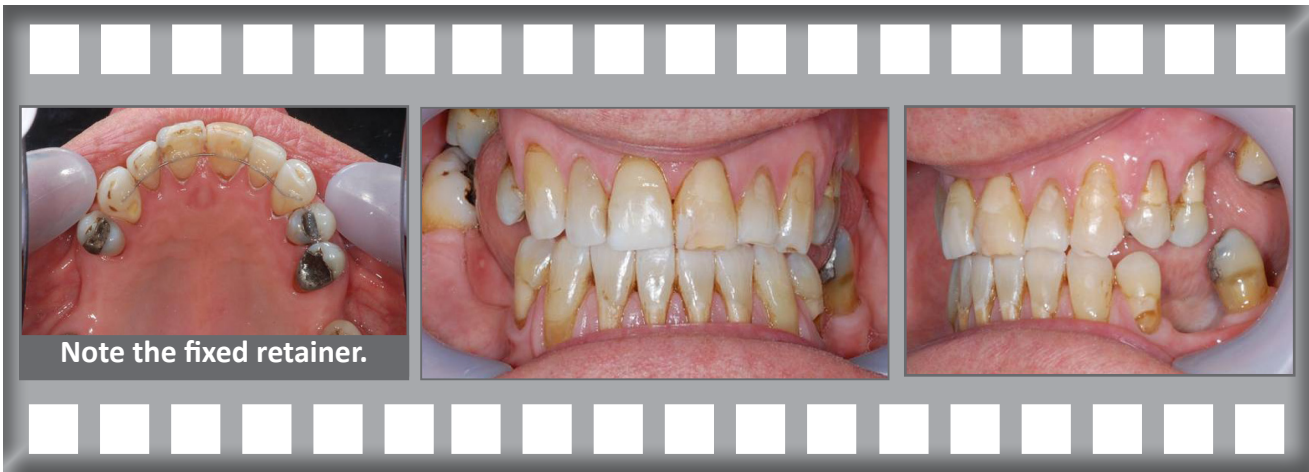

Before

Before treatment.



After orthodontic treatment.



Note the fixed retainer.