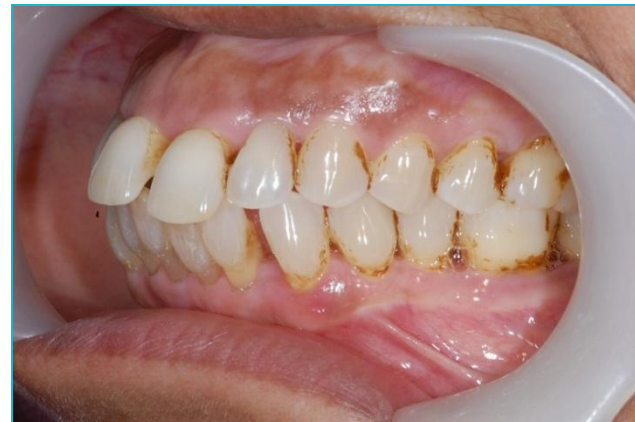
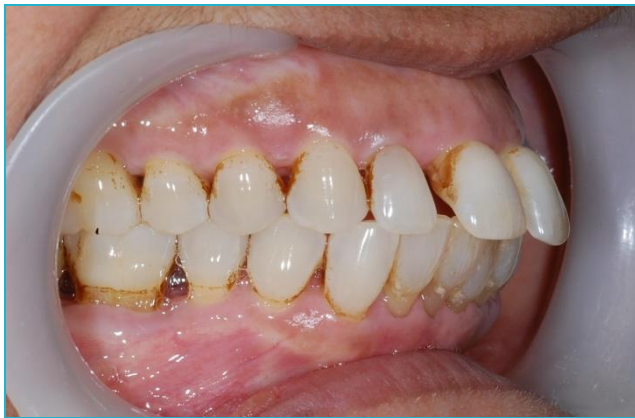
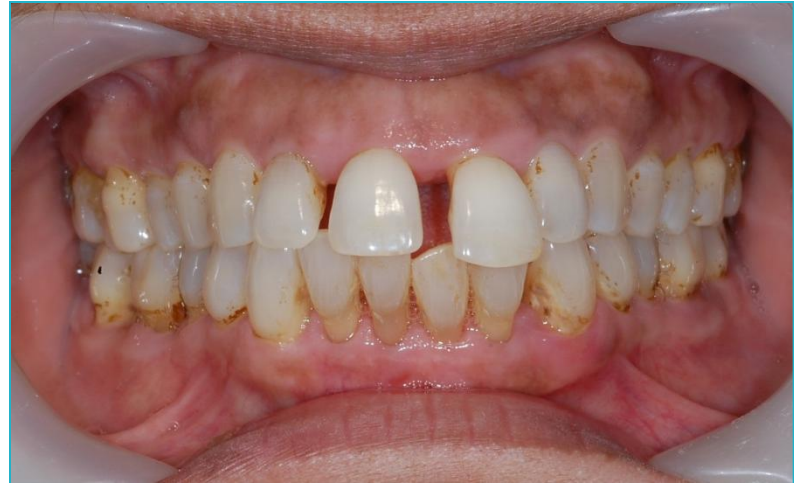
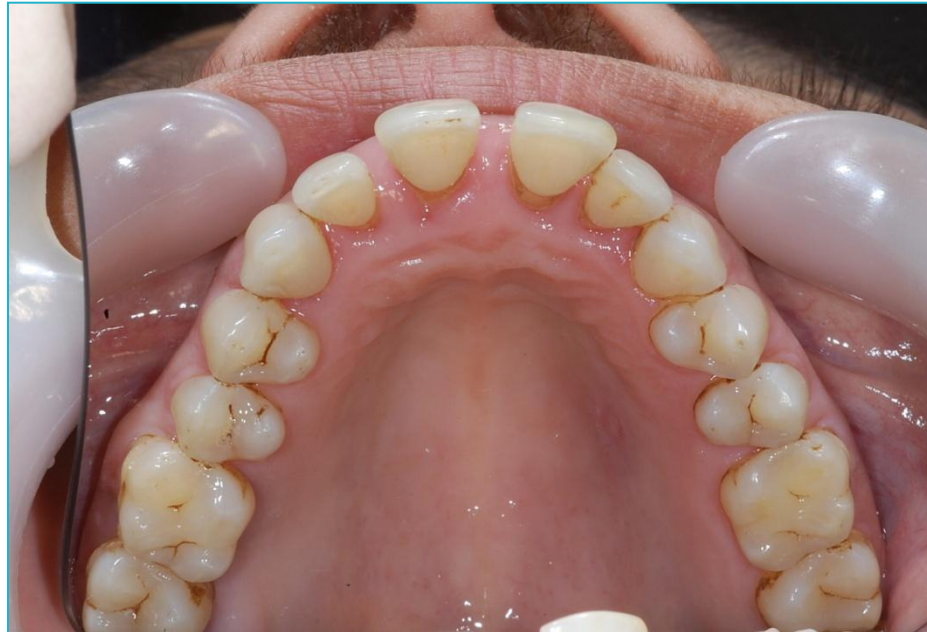
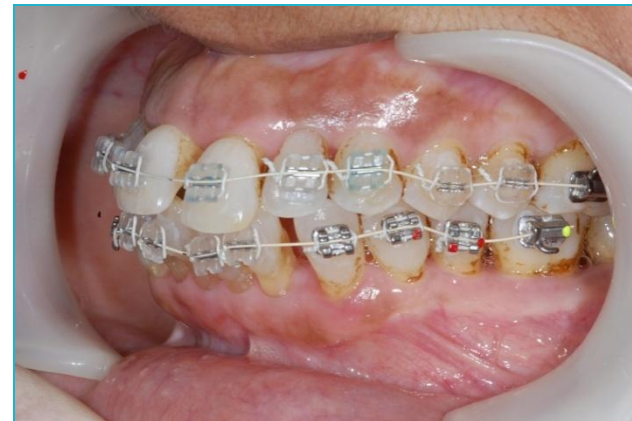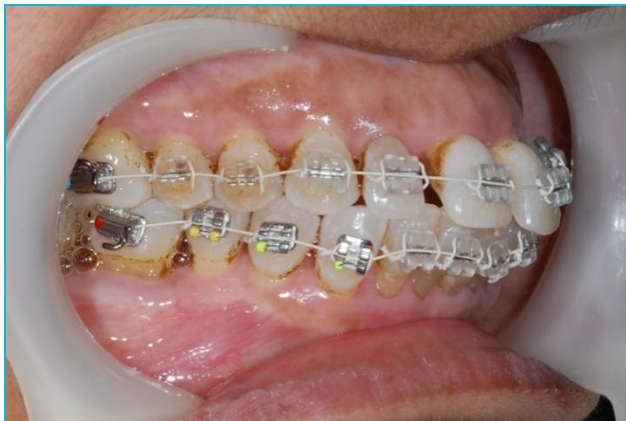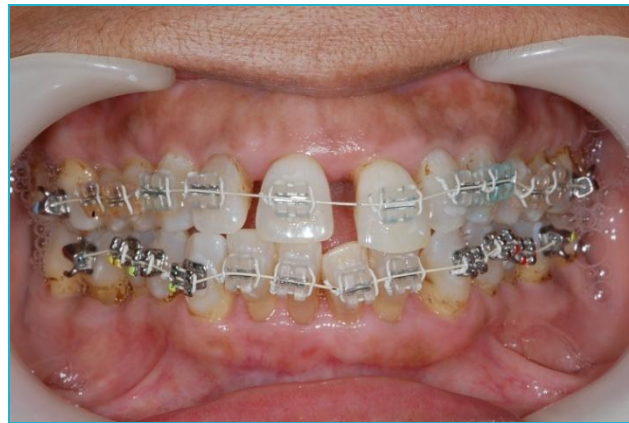Mary presented at 57 years of age concerned about her spaced teeth



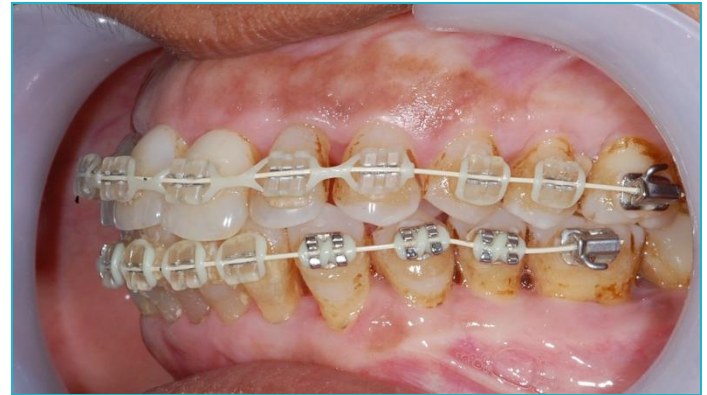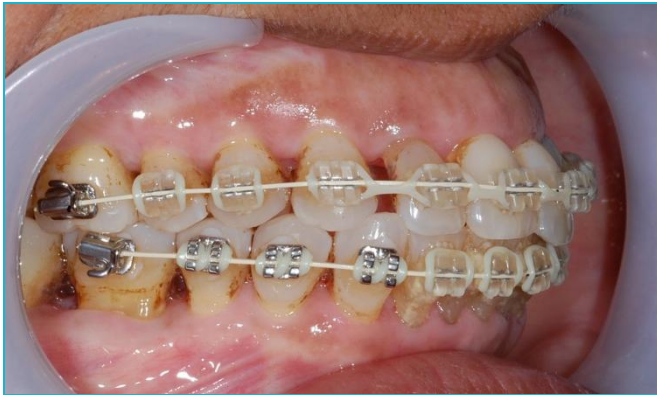
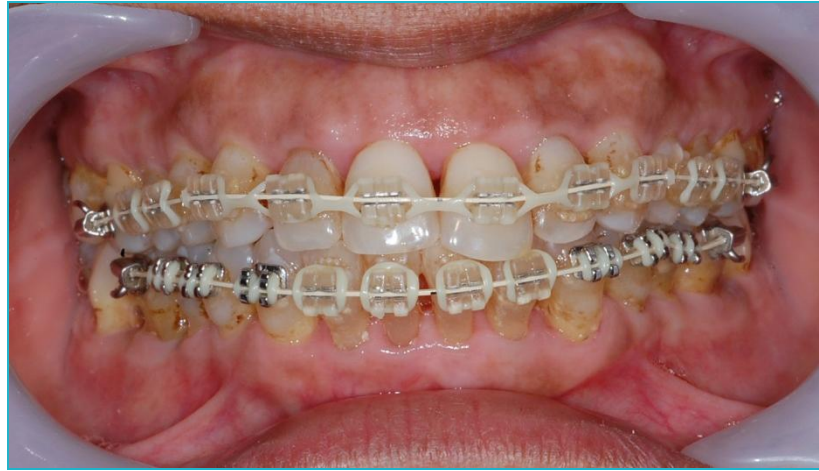The upper spacing was accompanied by a periodontal (gum) condition which was being treated by a local periodontist, Dr Spedding



Dr Horobin used a fixed brace to close the spaces

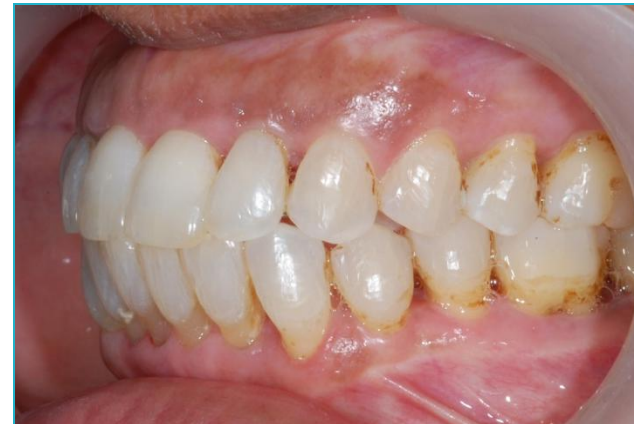
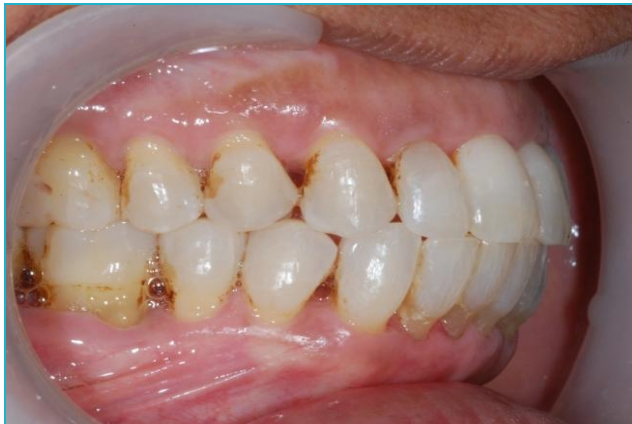
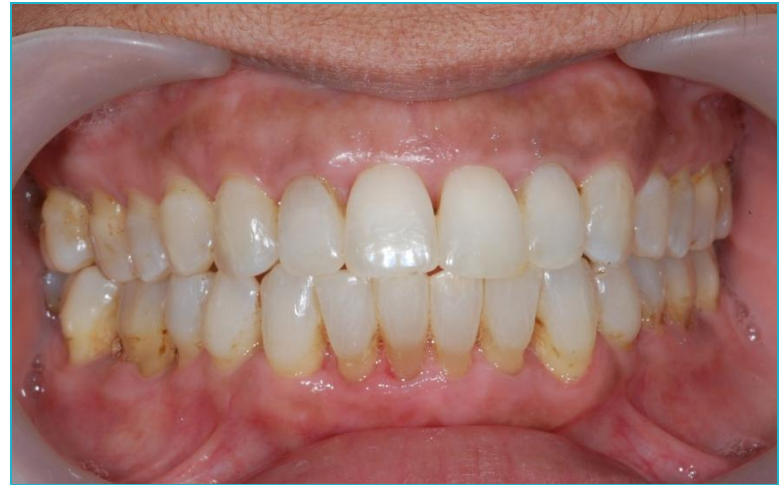Progress after 2 months



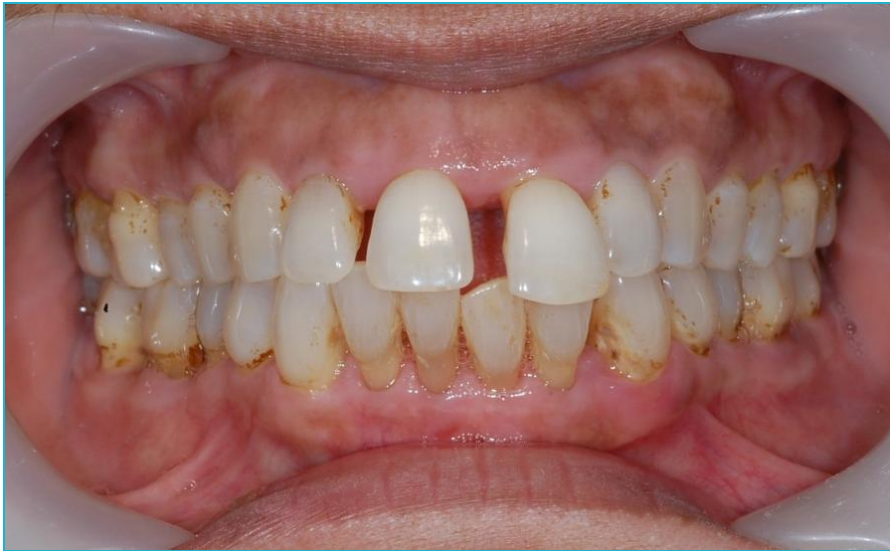

Finished Result

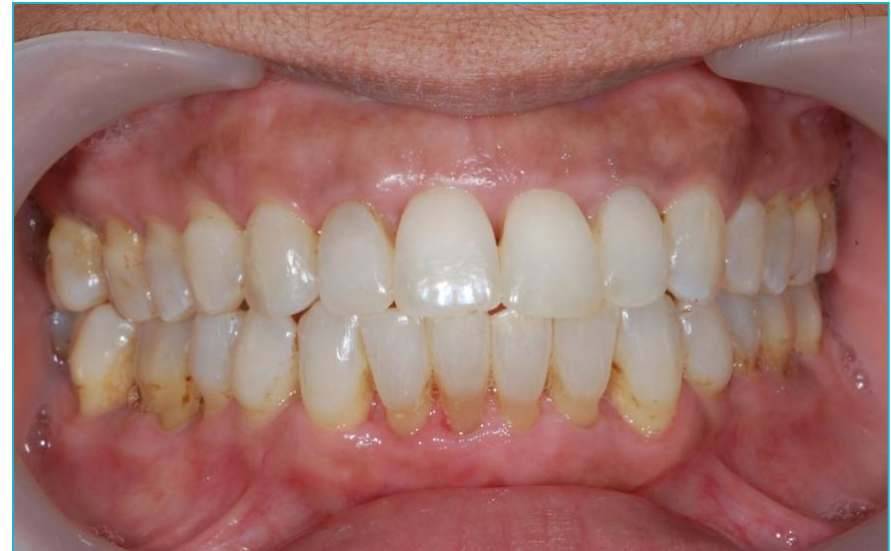

8 months treatment

Before

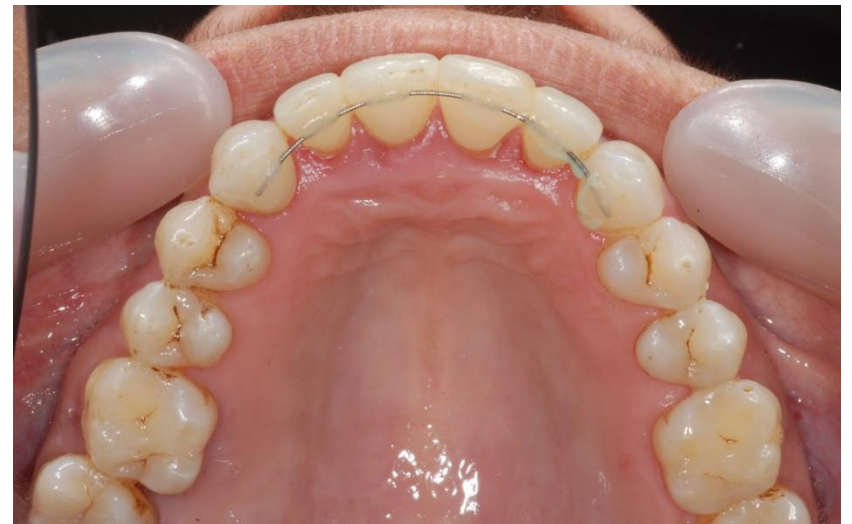
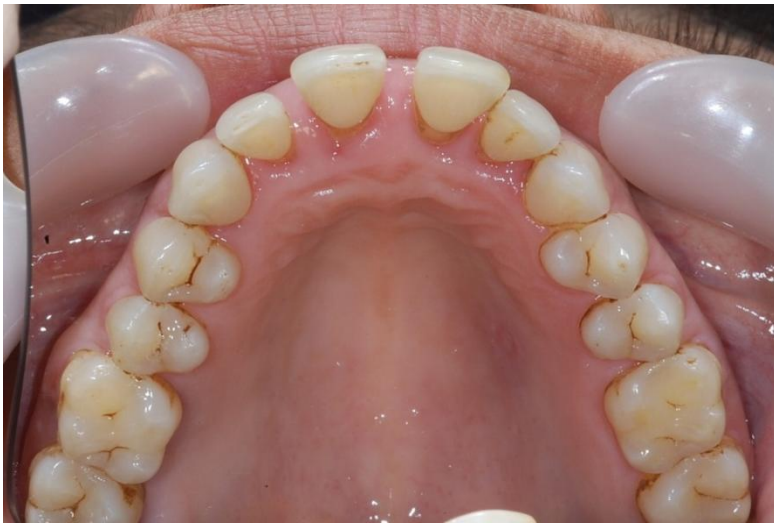
After



Before

After



Note the fixed retainer

Before



After



Smile Created by



Confidence in your smile