

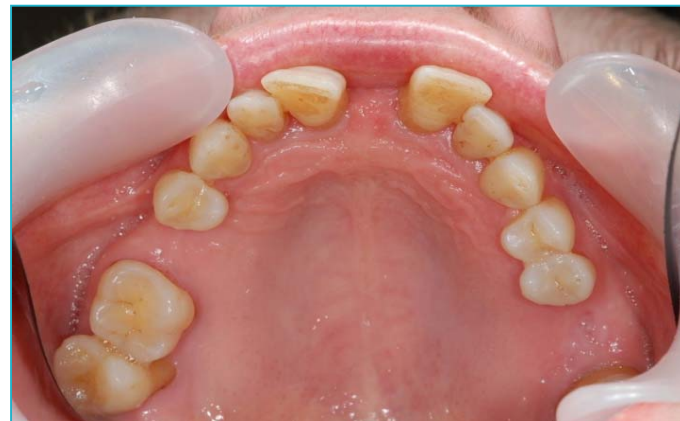
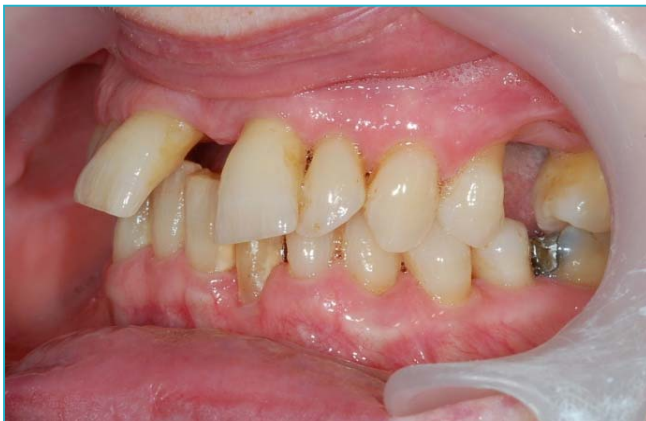
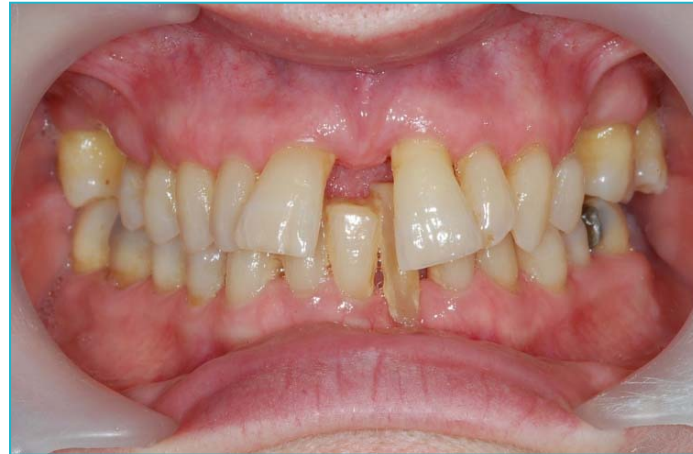Confidence in your smile

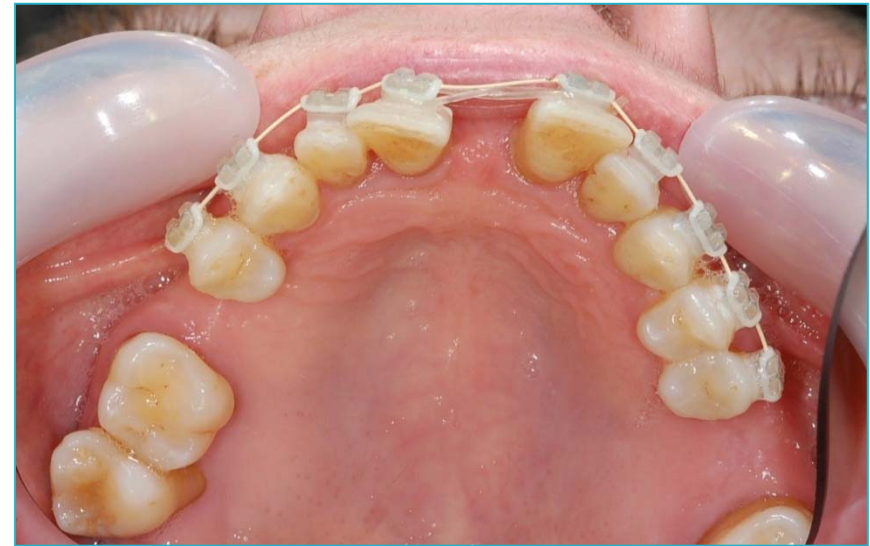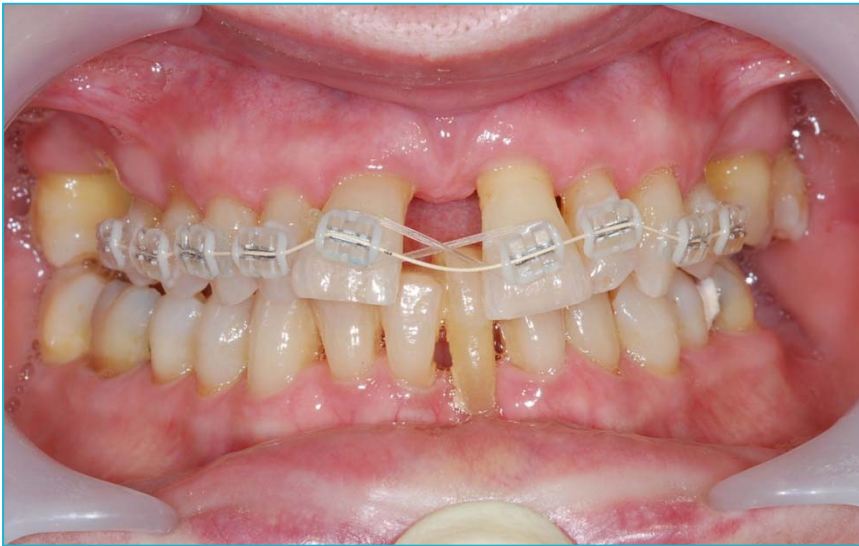presents

Ormco Spirit[®]MB

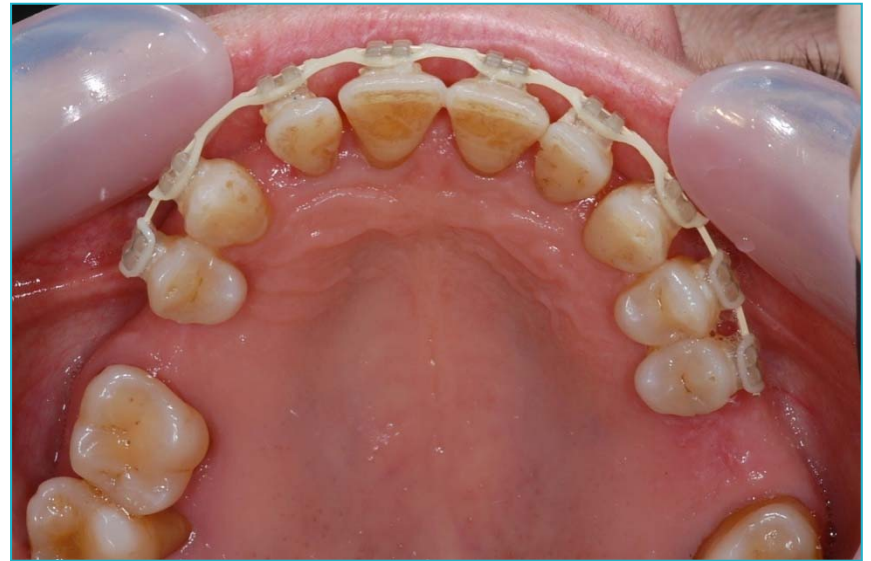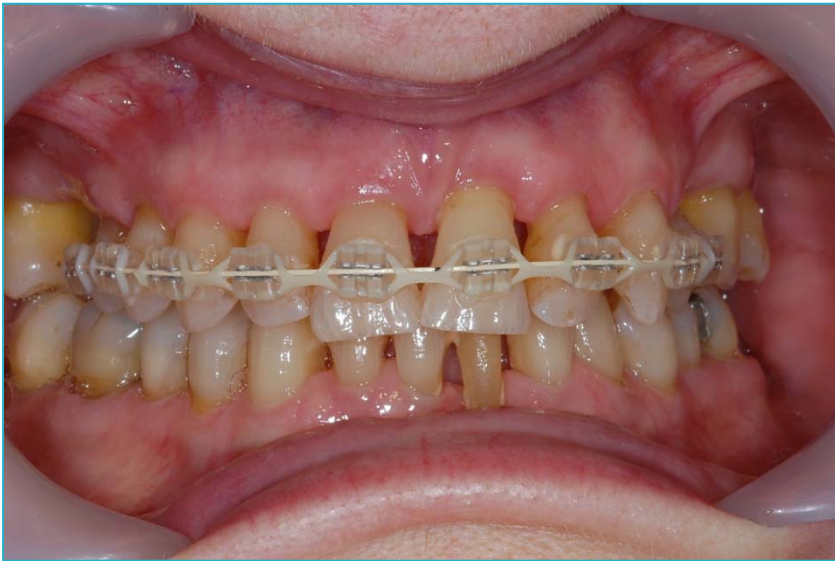
Marianne presented at 61 years young with upper incisors which had drifted badly, due to periodontal disease.



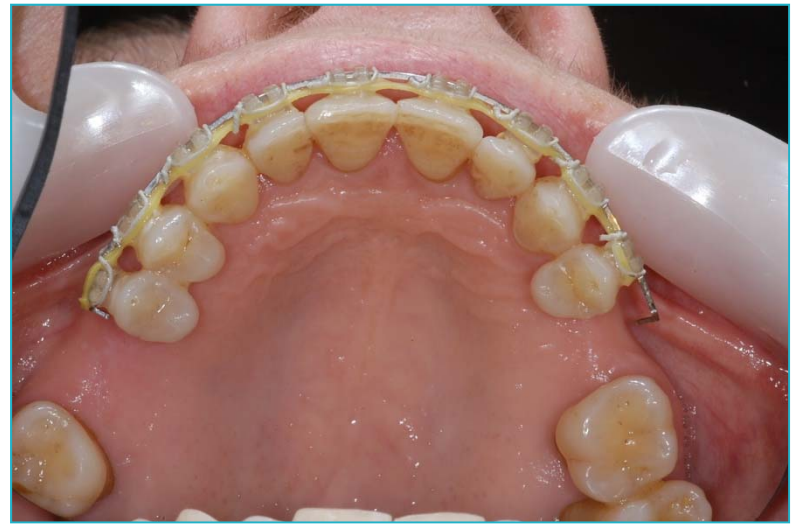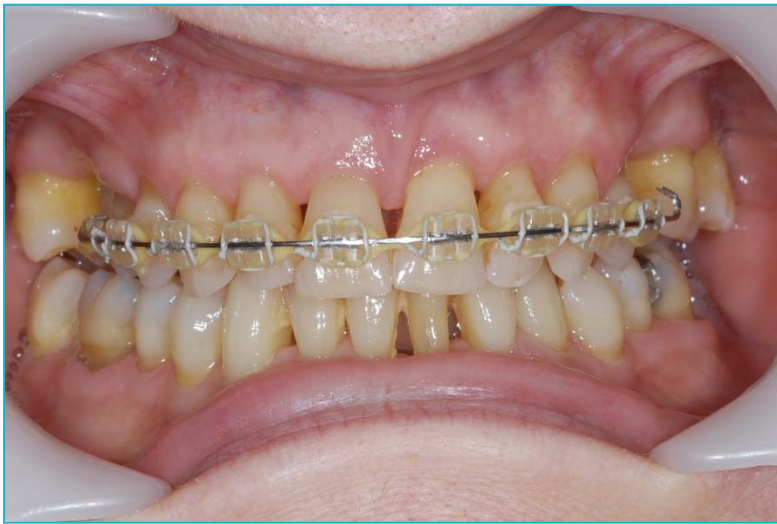Dr David Horobin used an aesthetic upper fixed brace to close the midline gap



Progress after 5 months

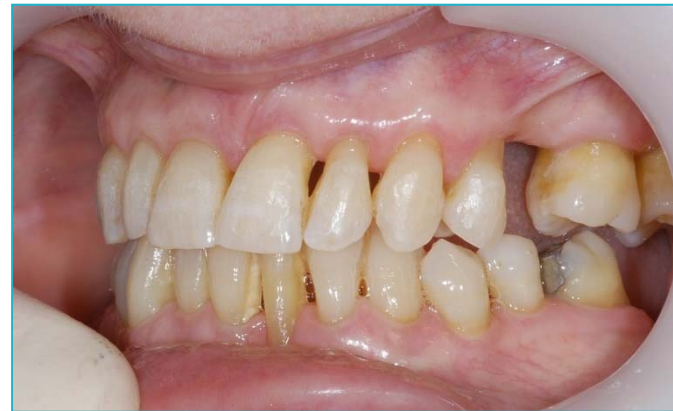
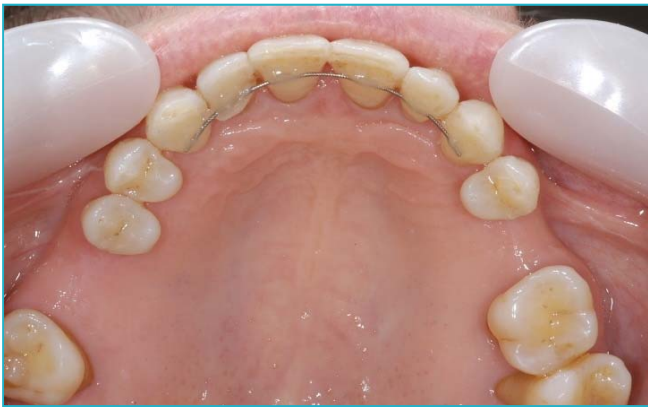
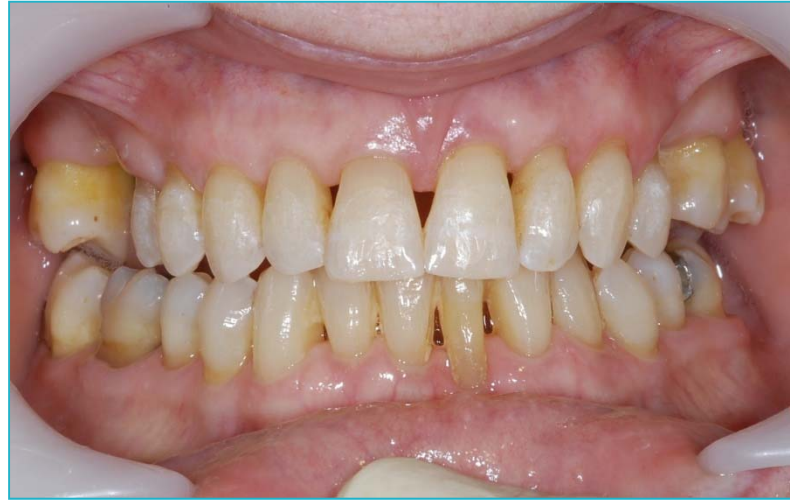All anterior space closed



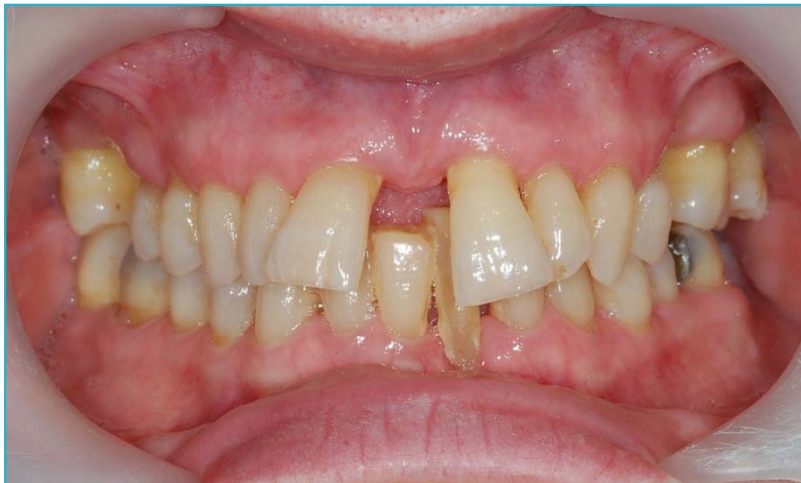

Finished Result

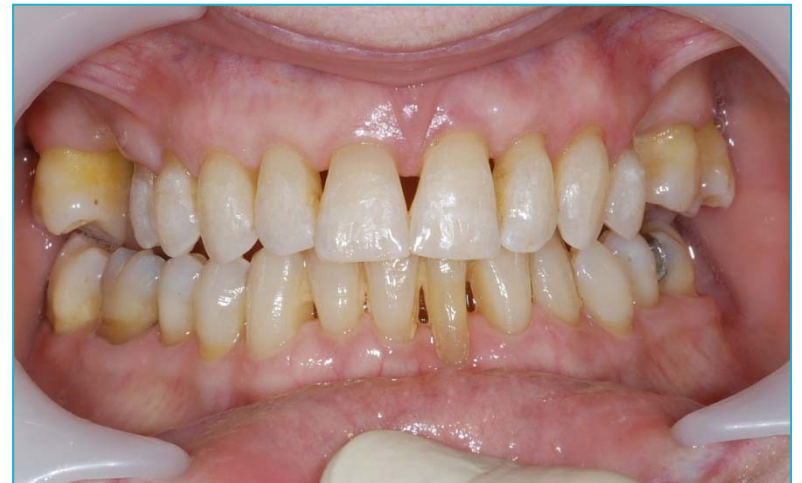

14 months treatment

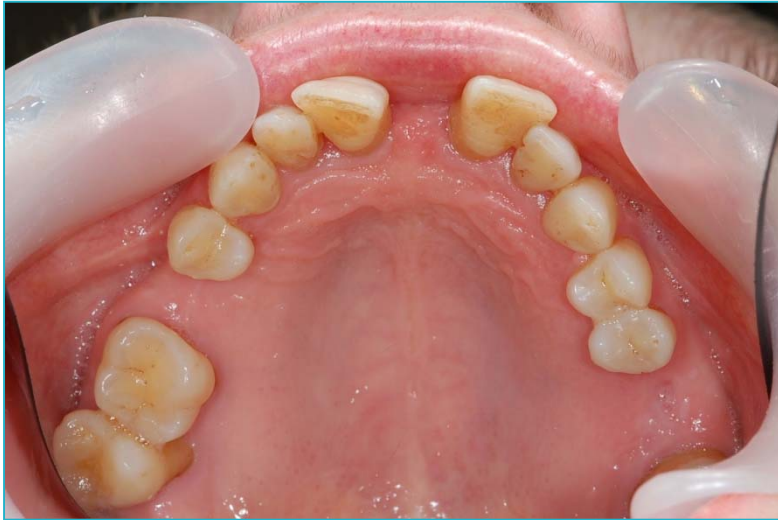Before



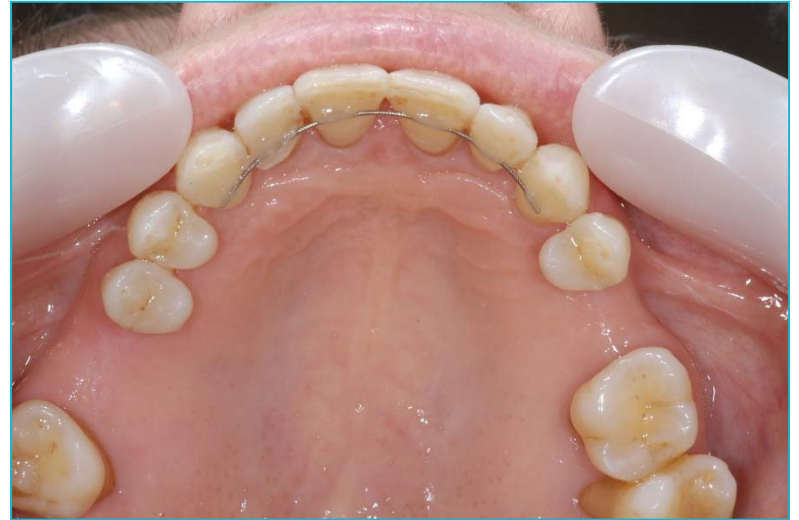After



Before



After



Note the fixed retainer

Before



After



Marianne was delighted with her new smile

Smile Created By



Confidence in your smile