



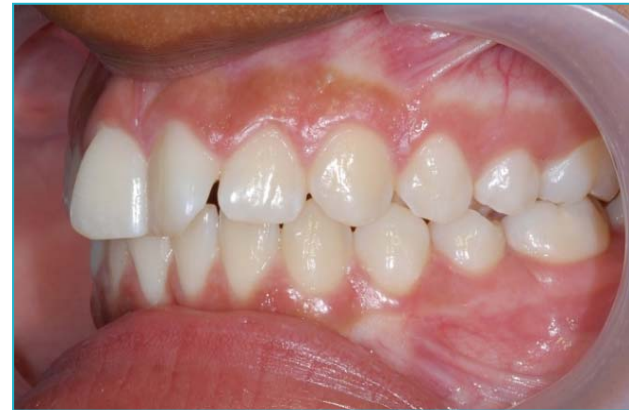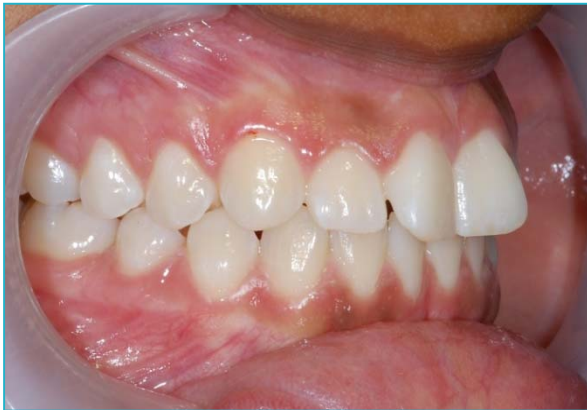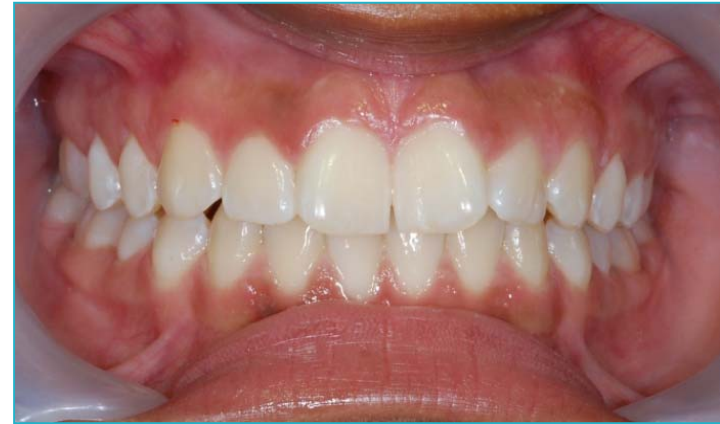Confidence in your smile

presents

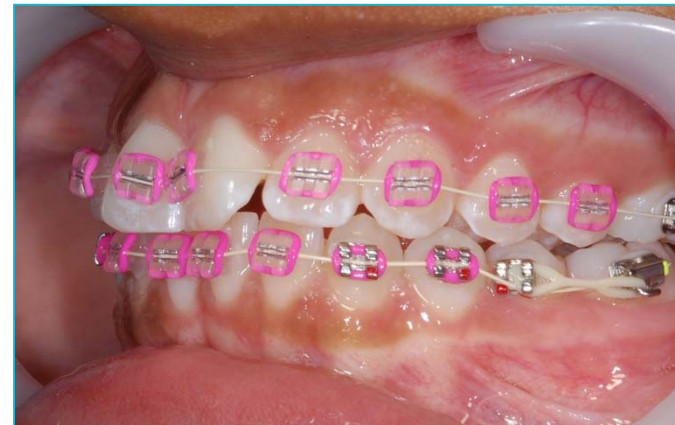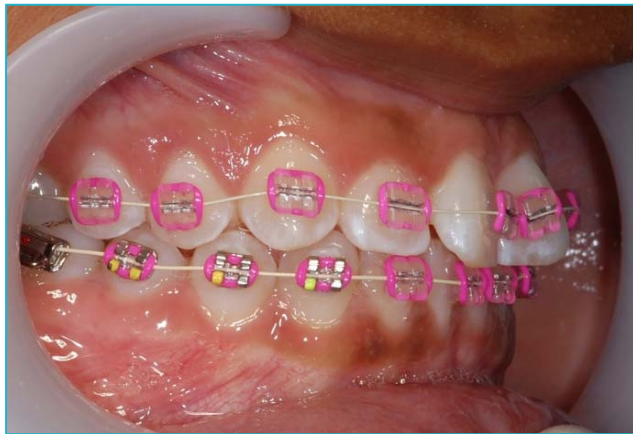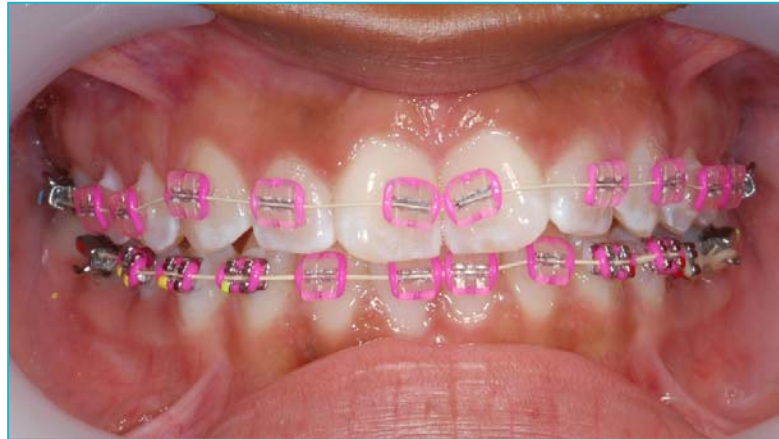Ormco Spirit[®]MB



Jasmin presented at 13 years of age concerned about her twisted front teeth.

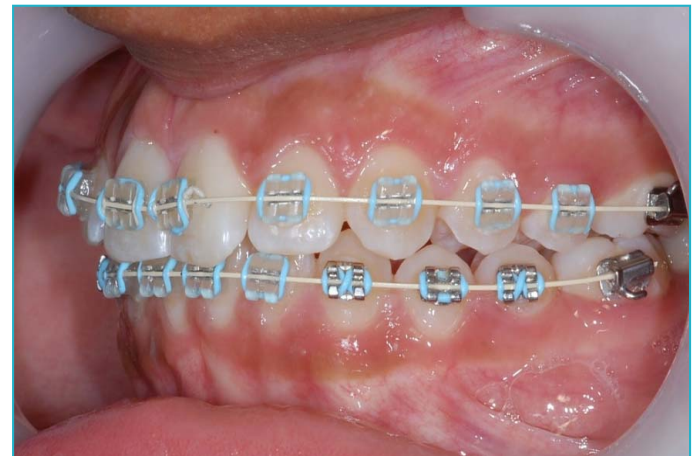
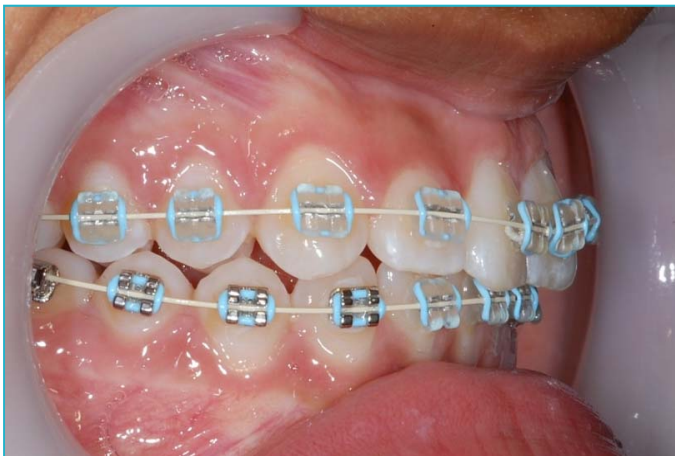
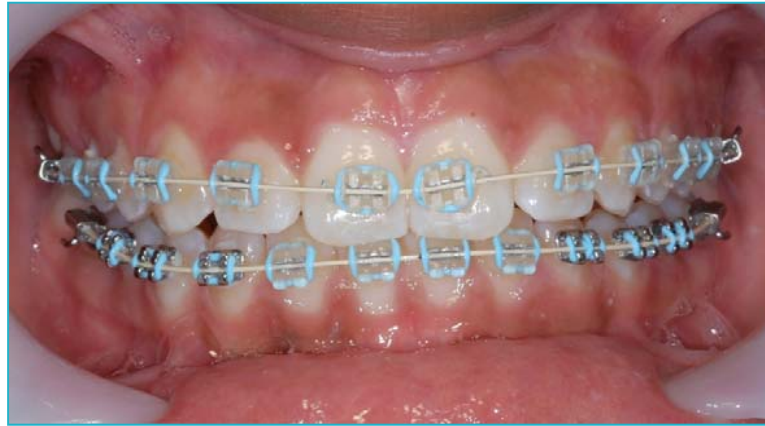

Dr David Horobin treated the case with a white aesthetic fixed appliance, without extractions.



Jasmin chose to have pink ligatures!

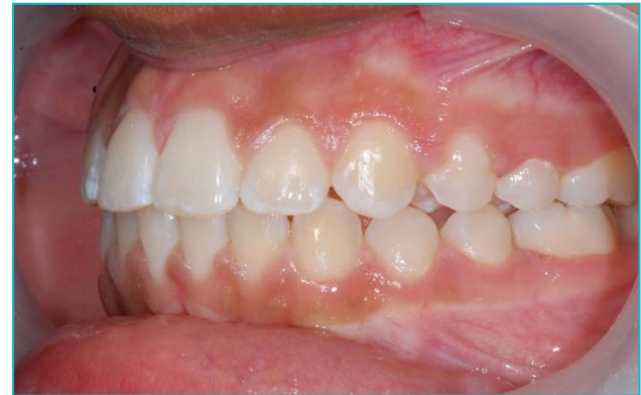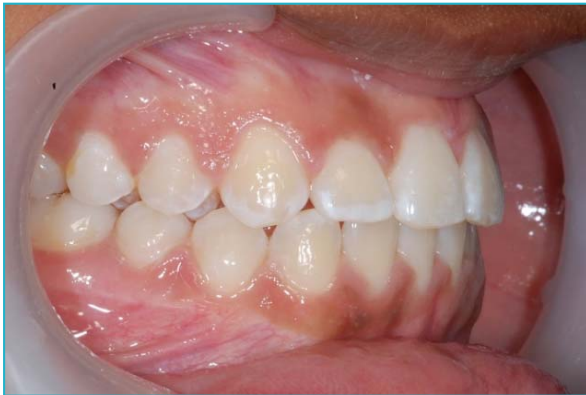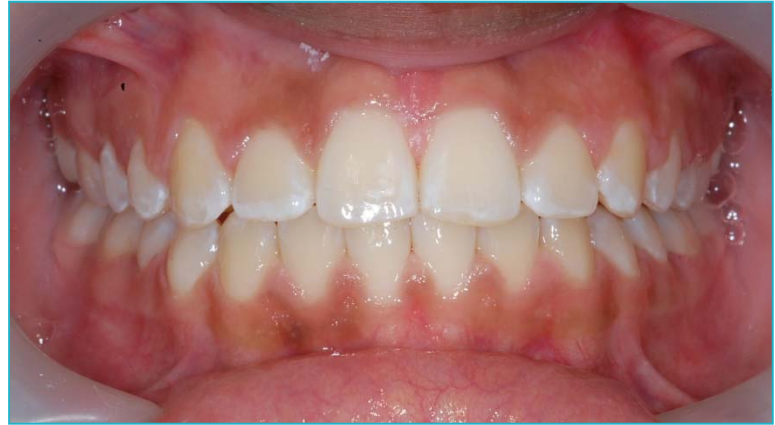Progress after 4 months



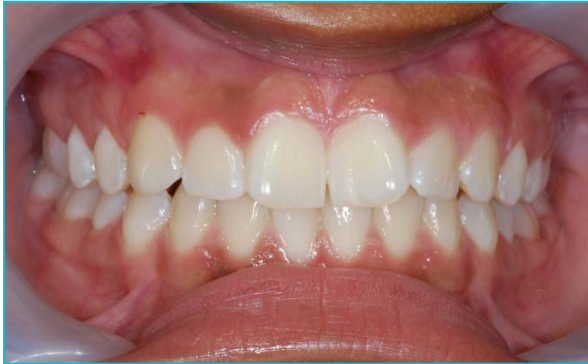With baby blue ligatures!



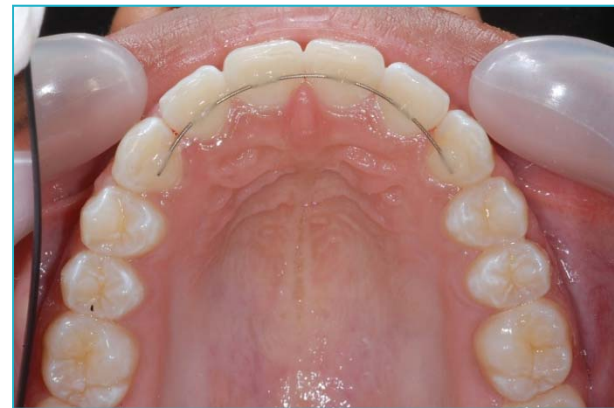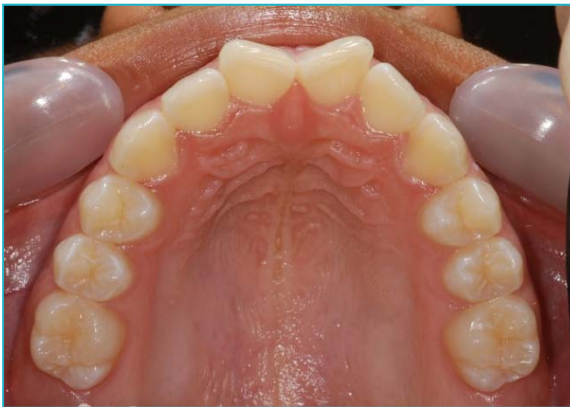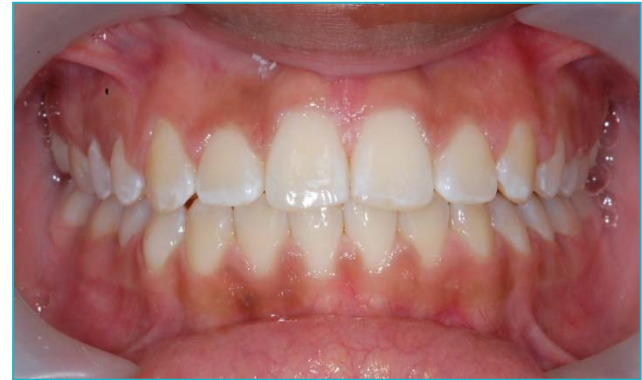Finished Smile after 12 months



Before




After




Note the fixed retainer

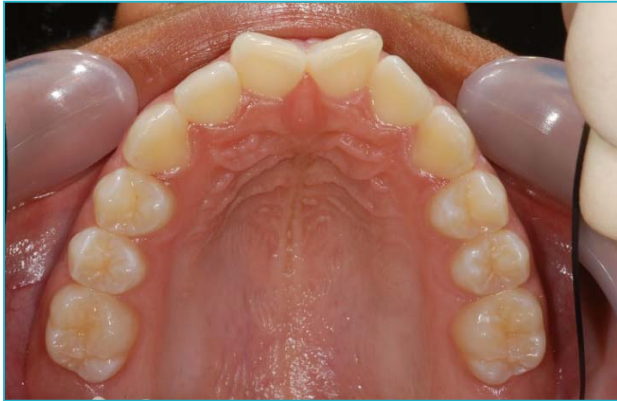Before



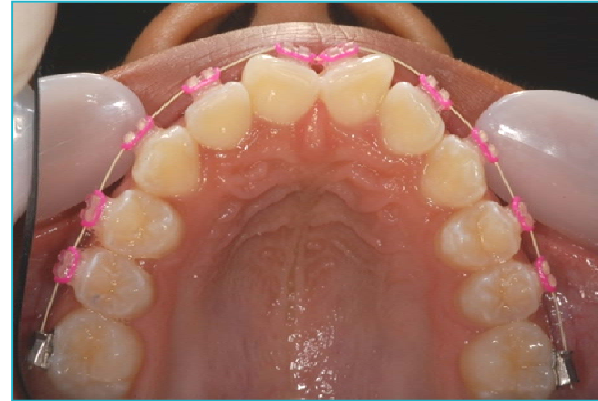After



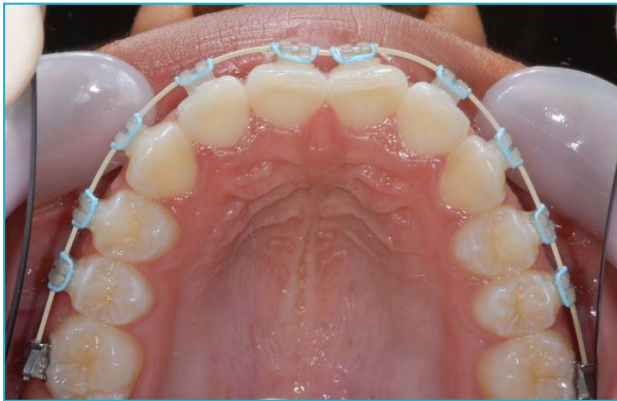Upper arch sequence



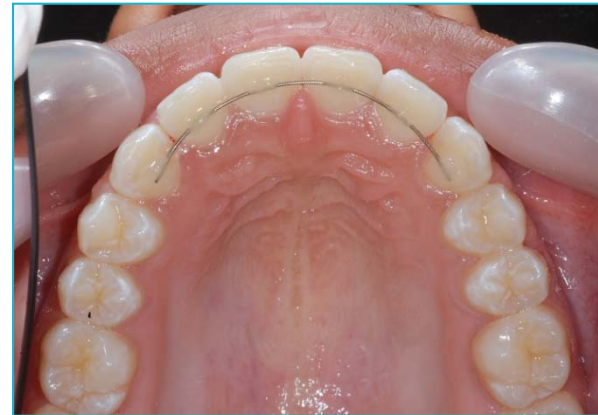1




2



3



4



Smile Created By



Confidence in your smile