

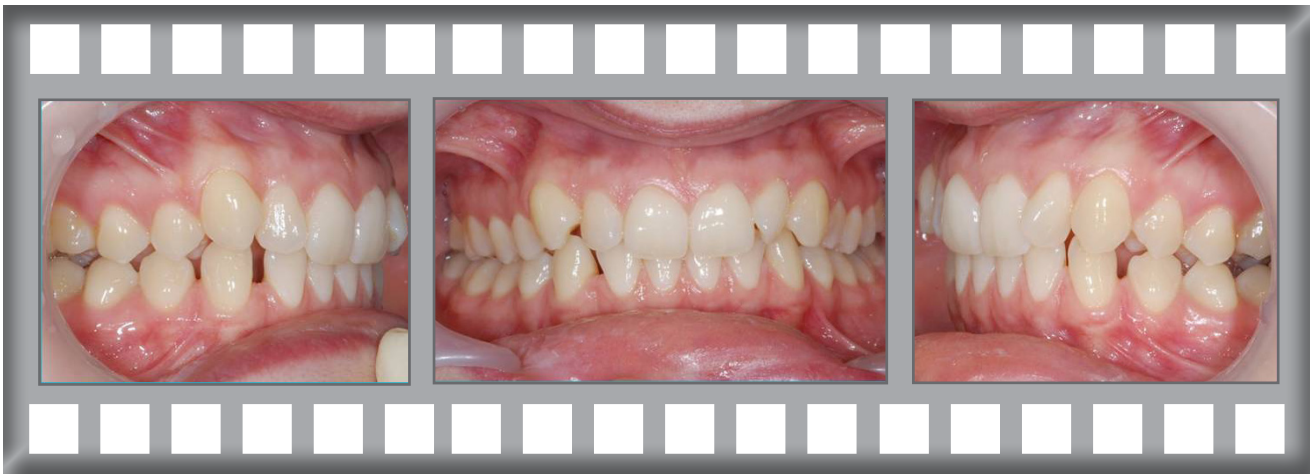## In-Ovation C

At 26 years of age, Leighann was concerned about her crowded and twisted upper front teeth.

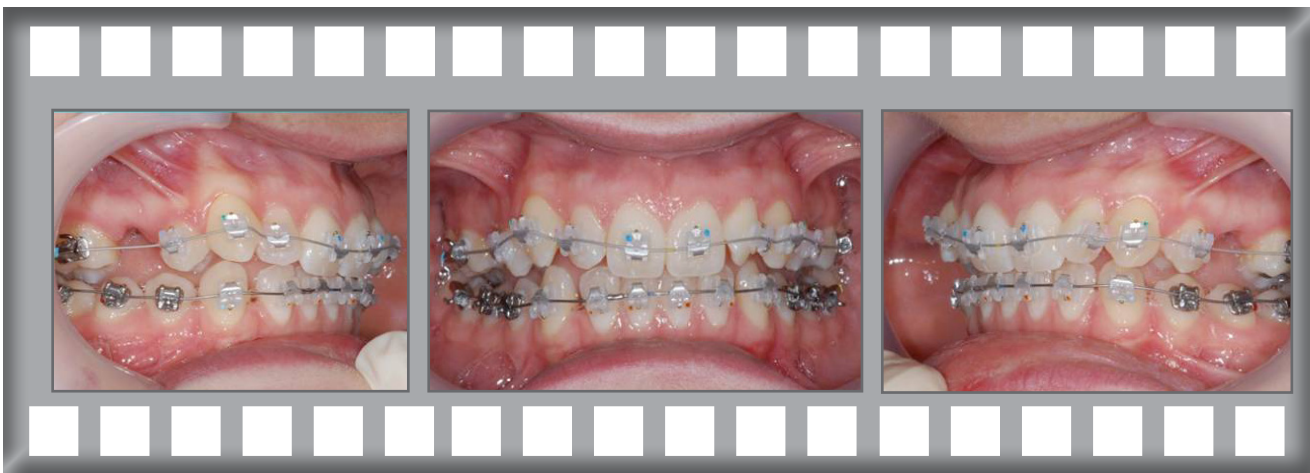
Treatment was complete after 11 months using the In-Ovation C system.



*Leighann*



Dr Horobin used the In-Ovation C system with the extraction of two upper second premolars.





Before

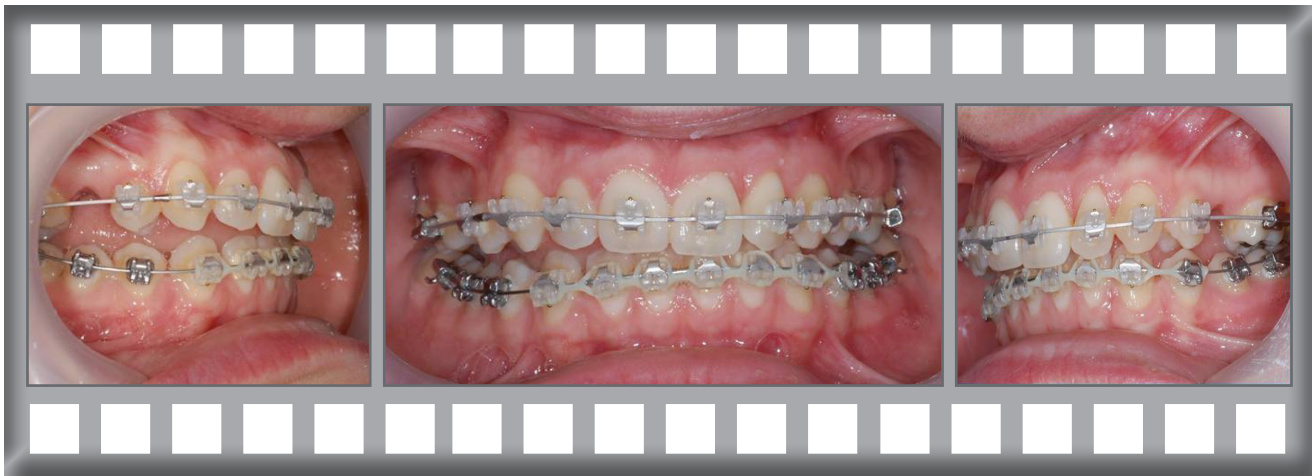

After

Leighann was delighted with her results and her treatment was complete just in time for her big day!

Treatment was complete after 11 months using the In-Ovation C system.

After just 2 months progress was already obvious.



The finished result after 11 months.

