



Confidence in your smile

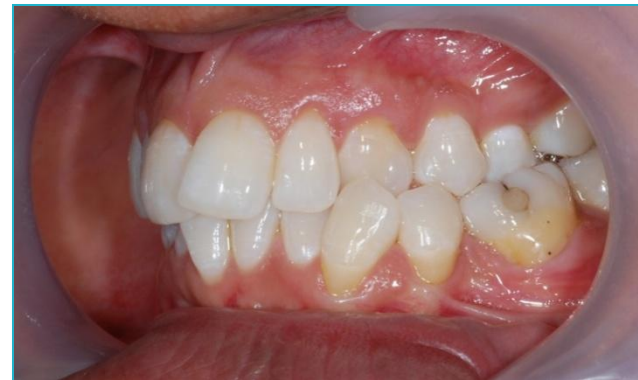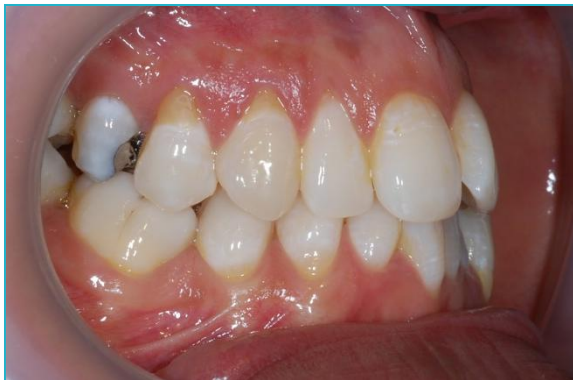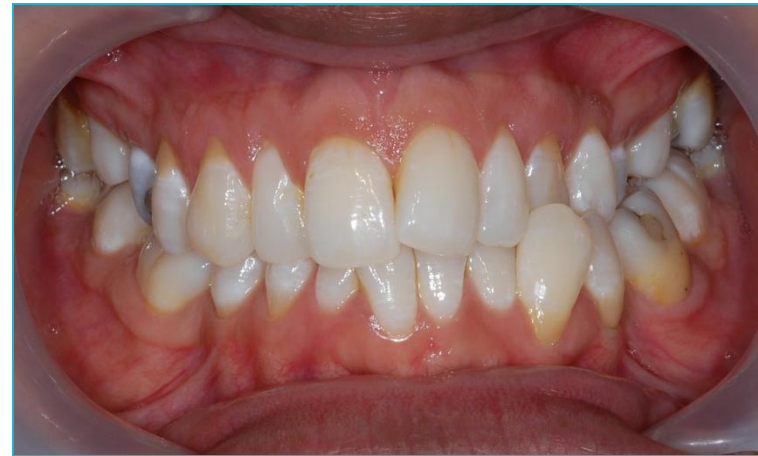presents



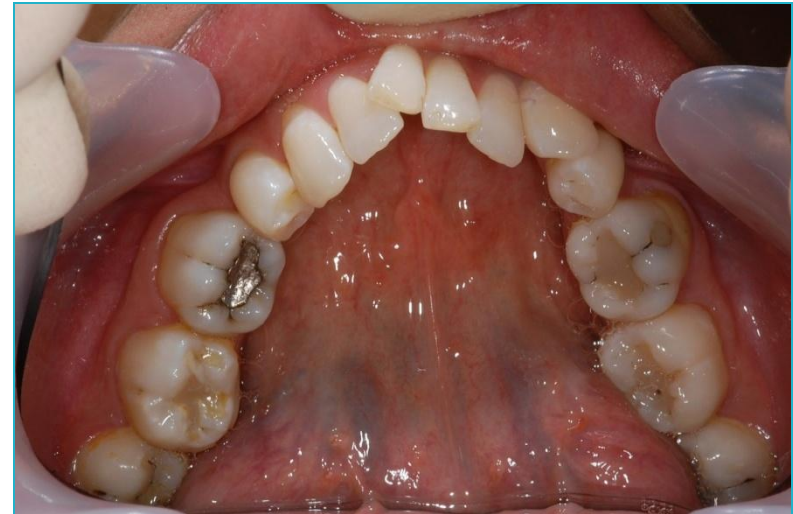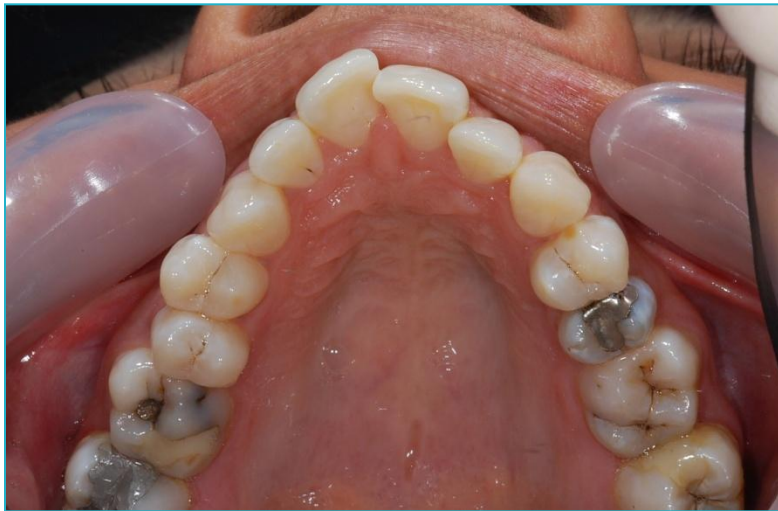In-Ovation[®] C



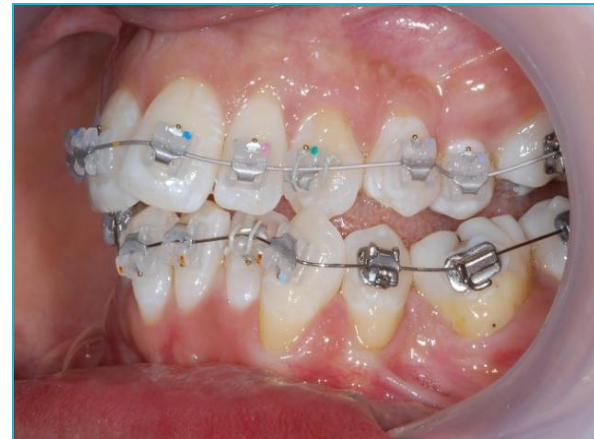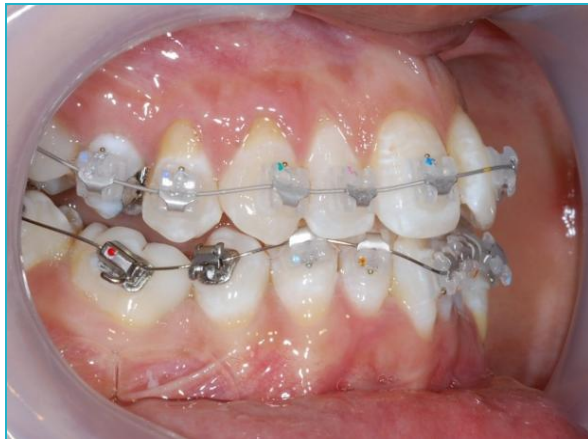
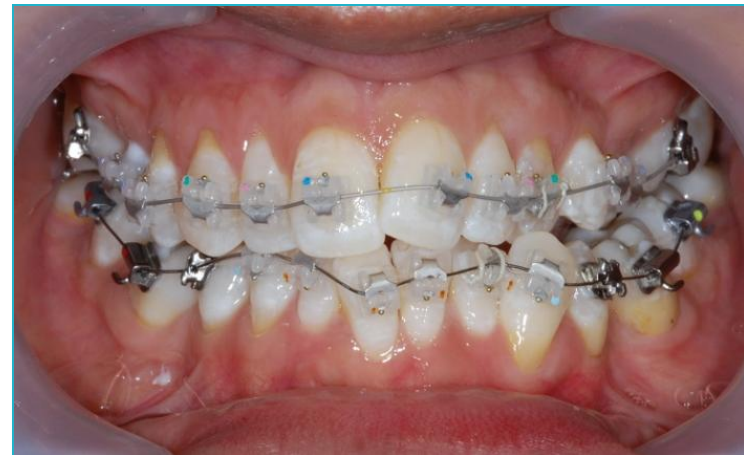At 30 years of age, Davinder was concerned about her lower crowding and cross bite



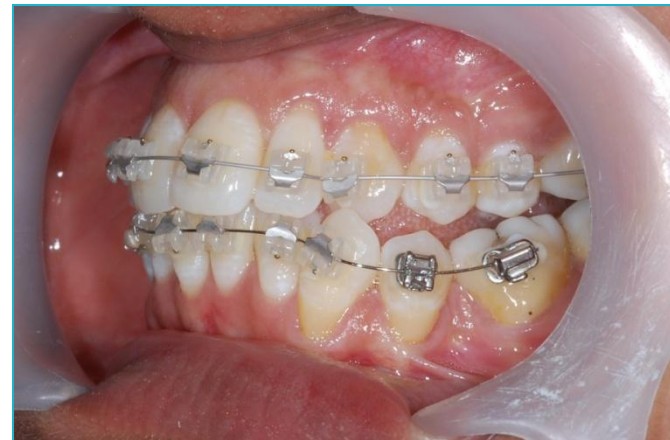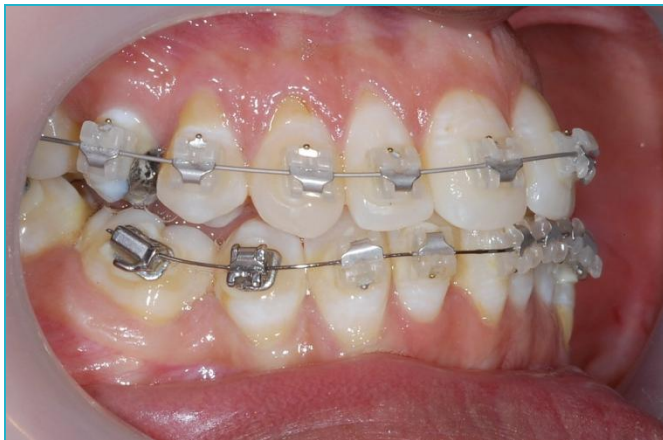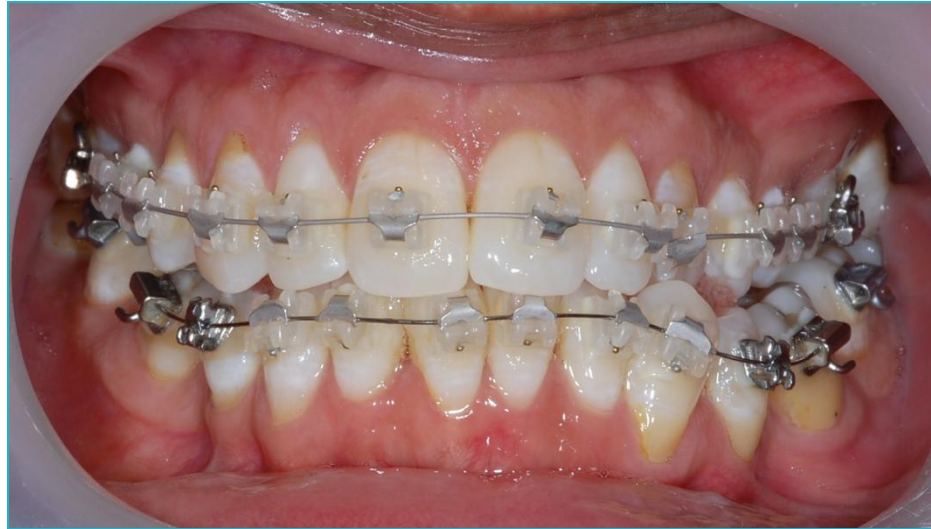The upper and lower arches were very narrow and irregular



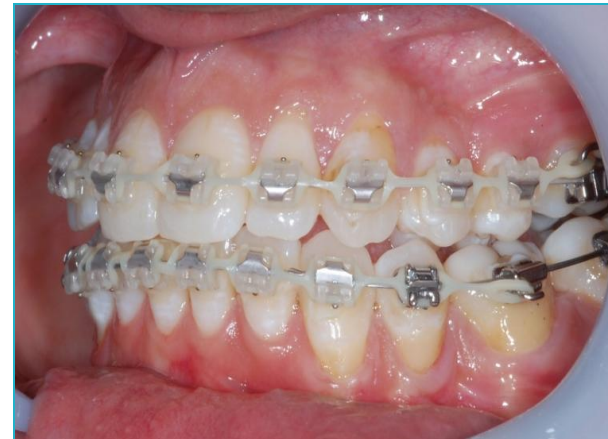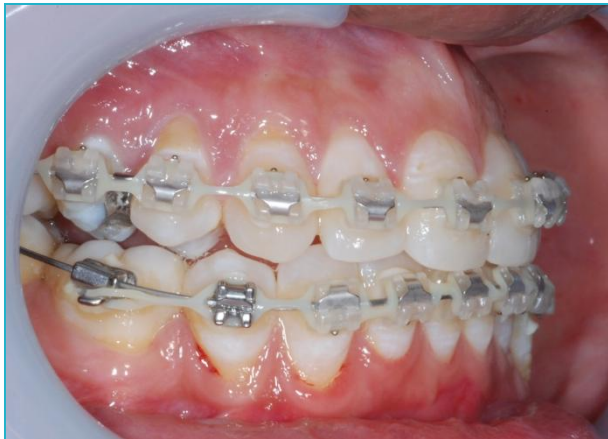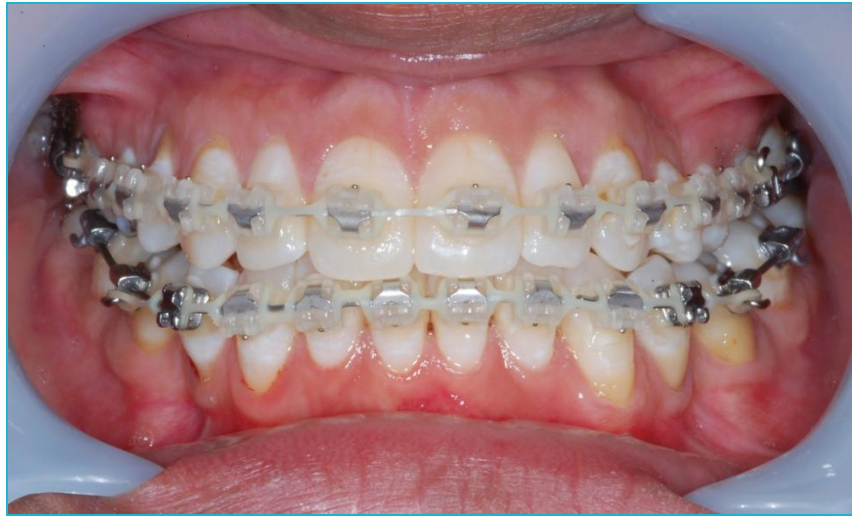**Dr David Horobin used the
In-Ovation C Brace without
extractions**



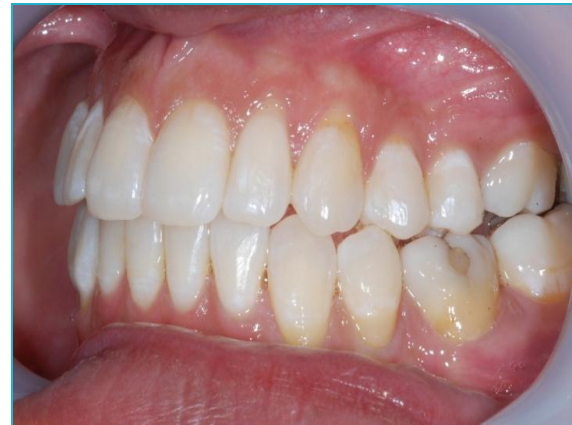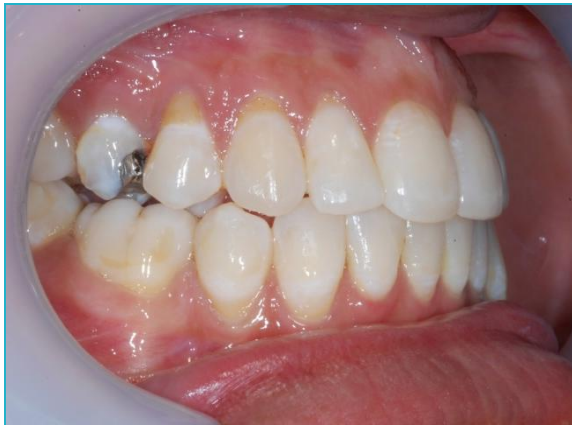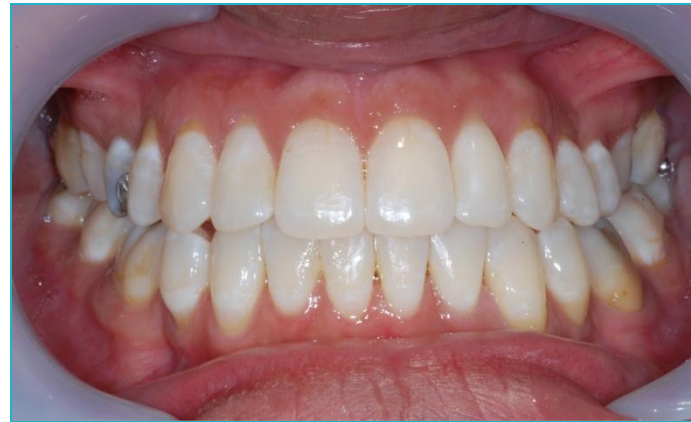Progress after 3 months



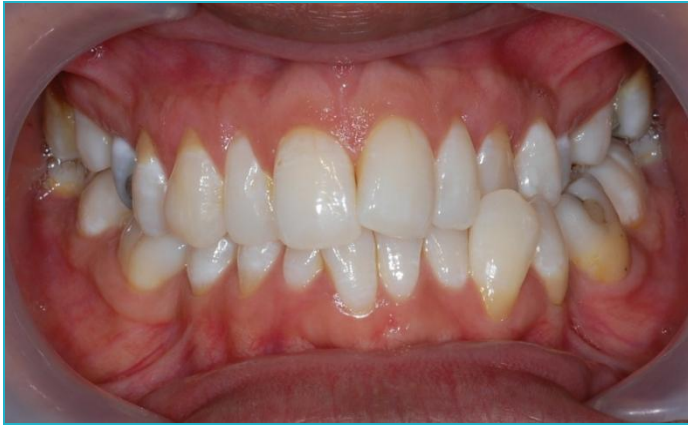Progress after 15 months



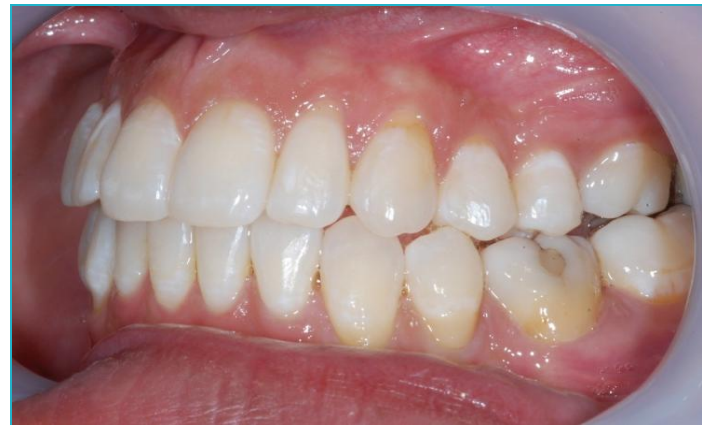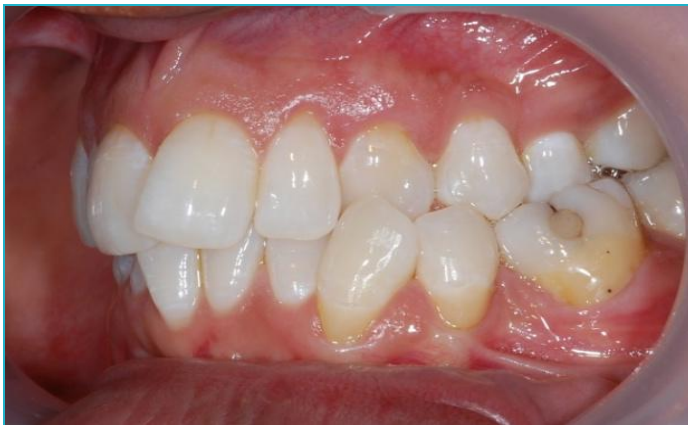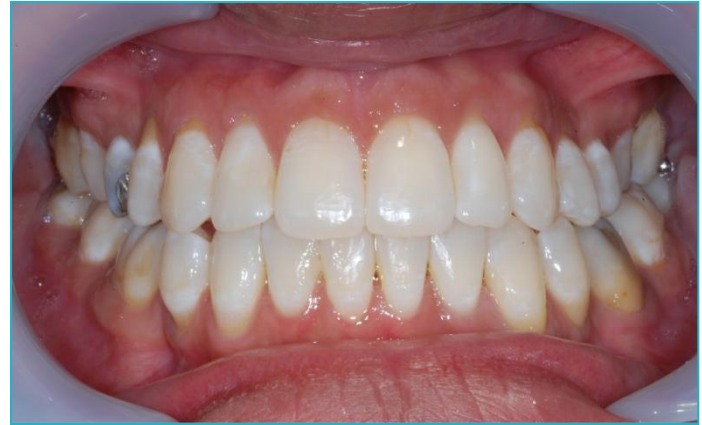Finished Result after 16 months



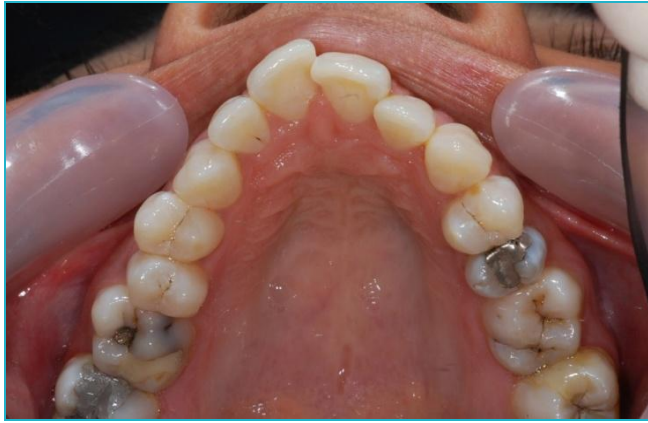Before



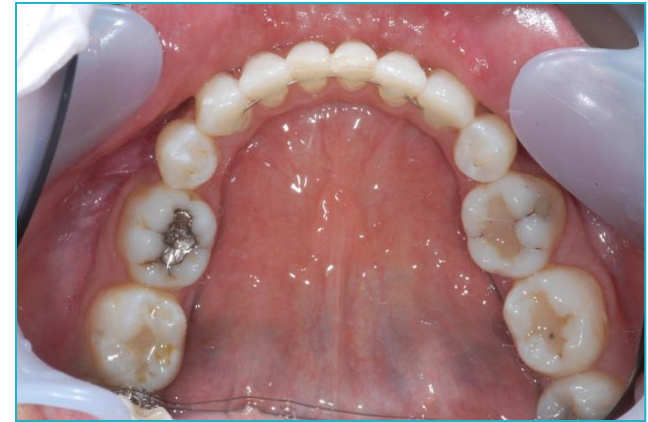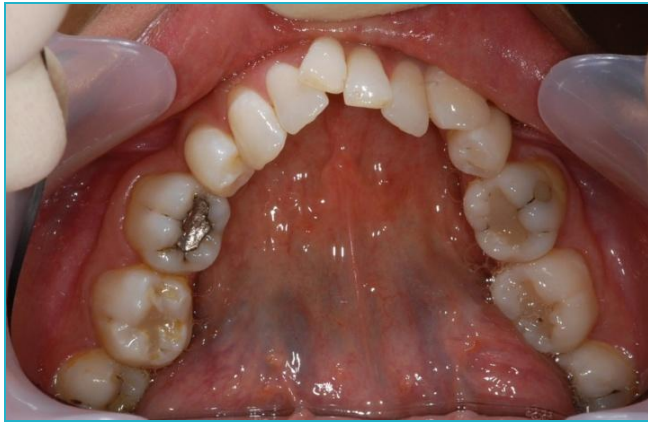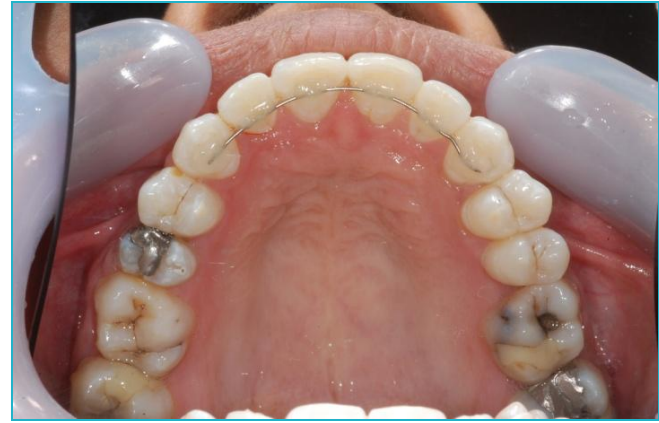After



Before



After



Note the fixed retainers

Before



After



Smile Created By



Confidence in your smile