

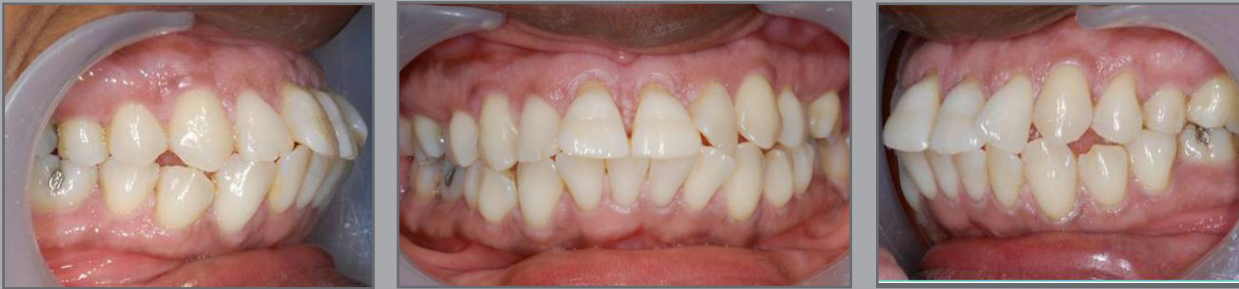## In-Ovation C

Carina was concerned about her prominent front teeth.

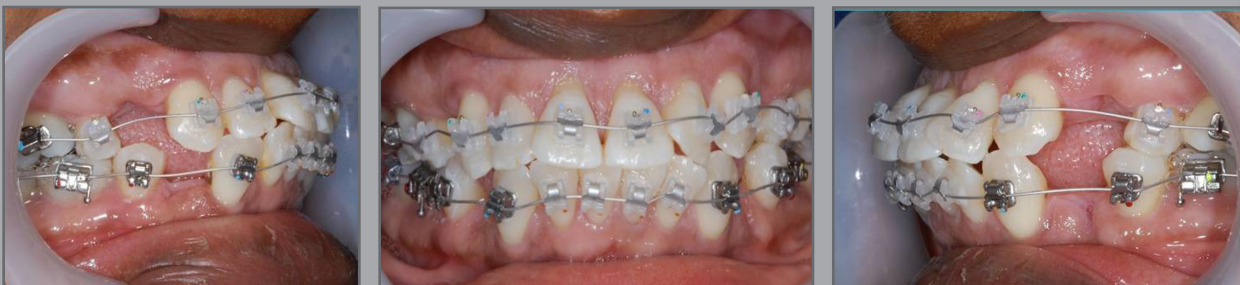Treatment was complete after 19 months using the In-Ovation C system.



*Carina*




All four first premolars were extracted to create space and Dr Horobin used the In-Ovation C system

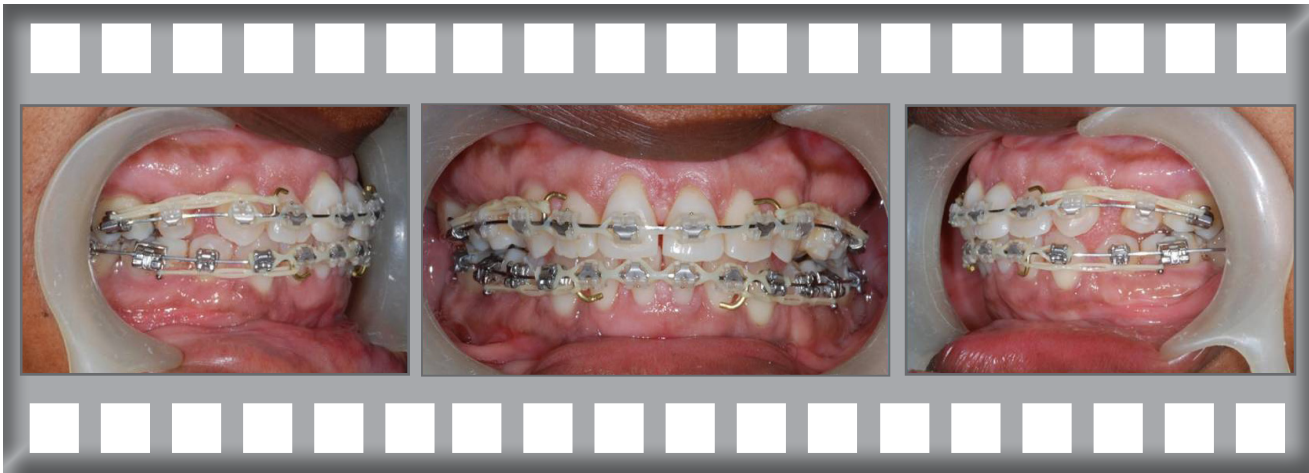

Carina was delighted with her results.

Treatment was complete after 13 months using the Damon Clear system without extractions.



After 12 months the front teeth are beginning to move inwards.



Treatment complete after 19 months.

