

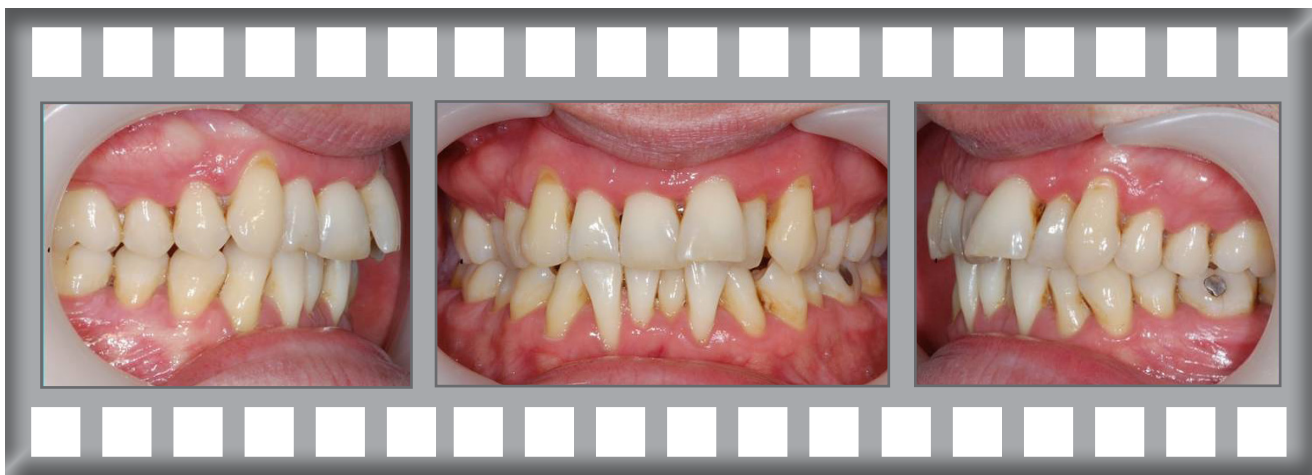## In-Ovation C

Alex was concerned about his crowded and twisted front teeth. There had been a periodontal (gum) problem in this case.

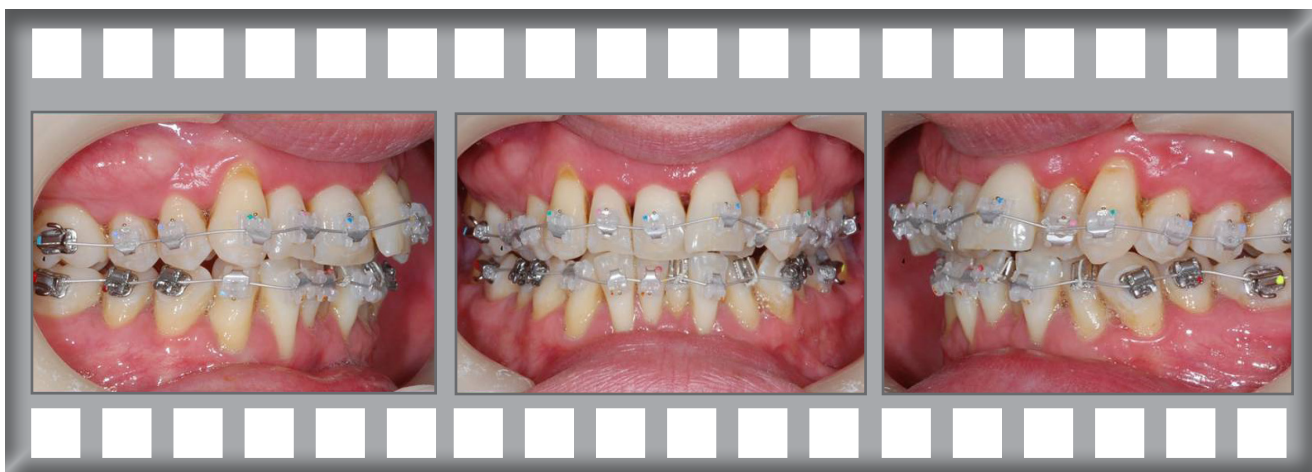Treatment was complete after 9 months using the In-Ovation C system.



Alex




Dr Horobin used the In-Ovation C system

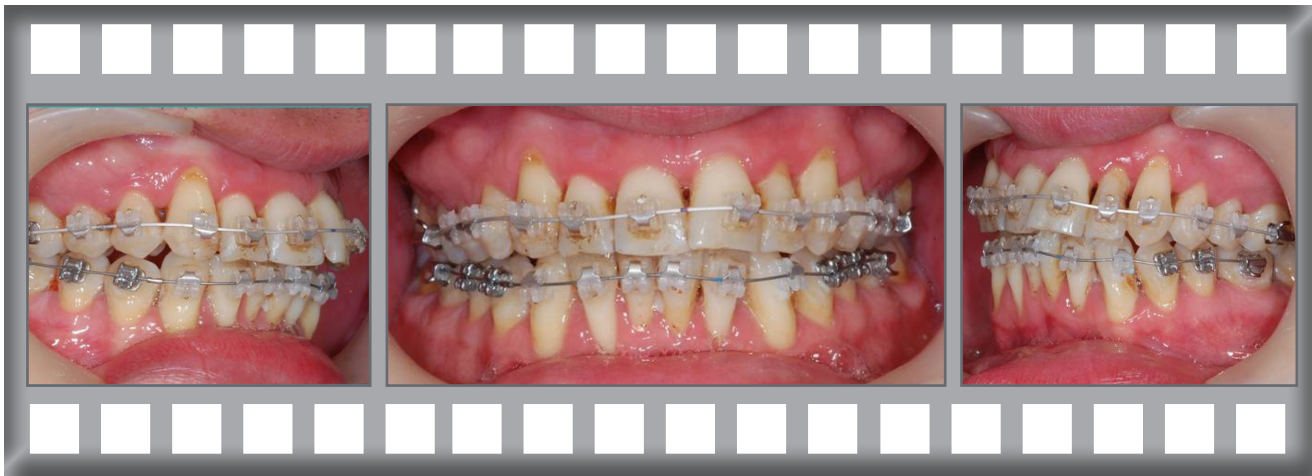


Alex was delighted with his results.

Treatment was complete after 9 months using the In-Ovation C system.



Progress after 5 months.



The finished result after just 9 months.

