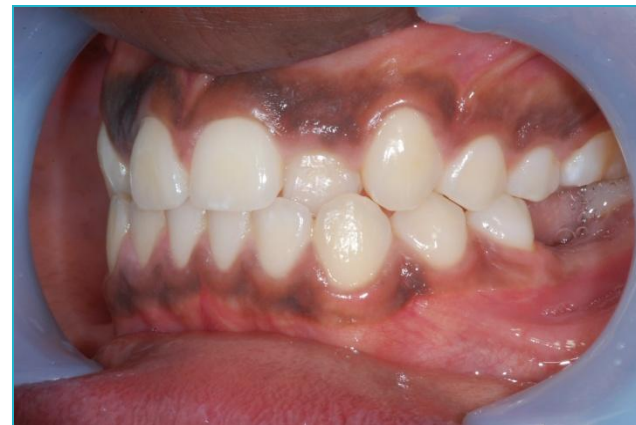
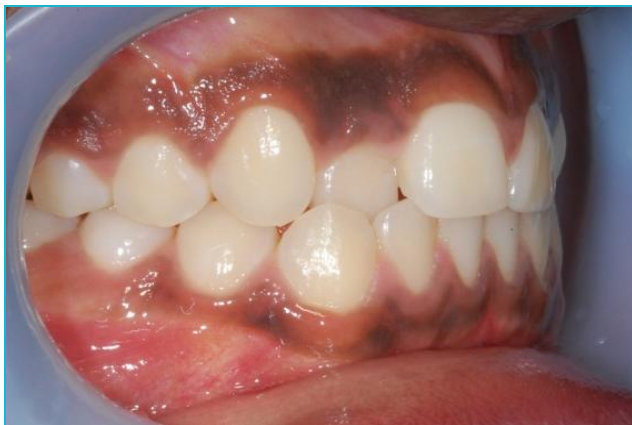
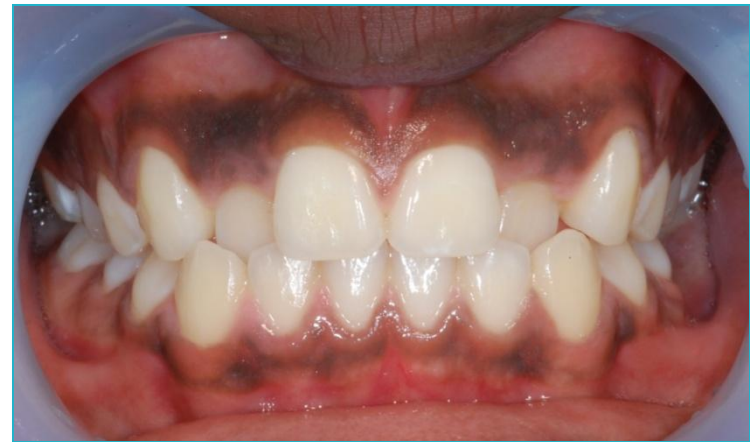
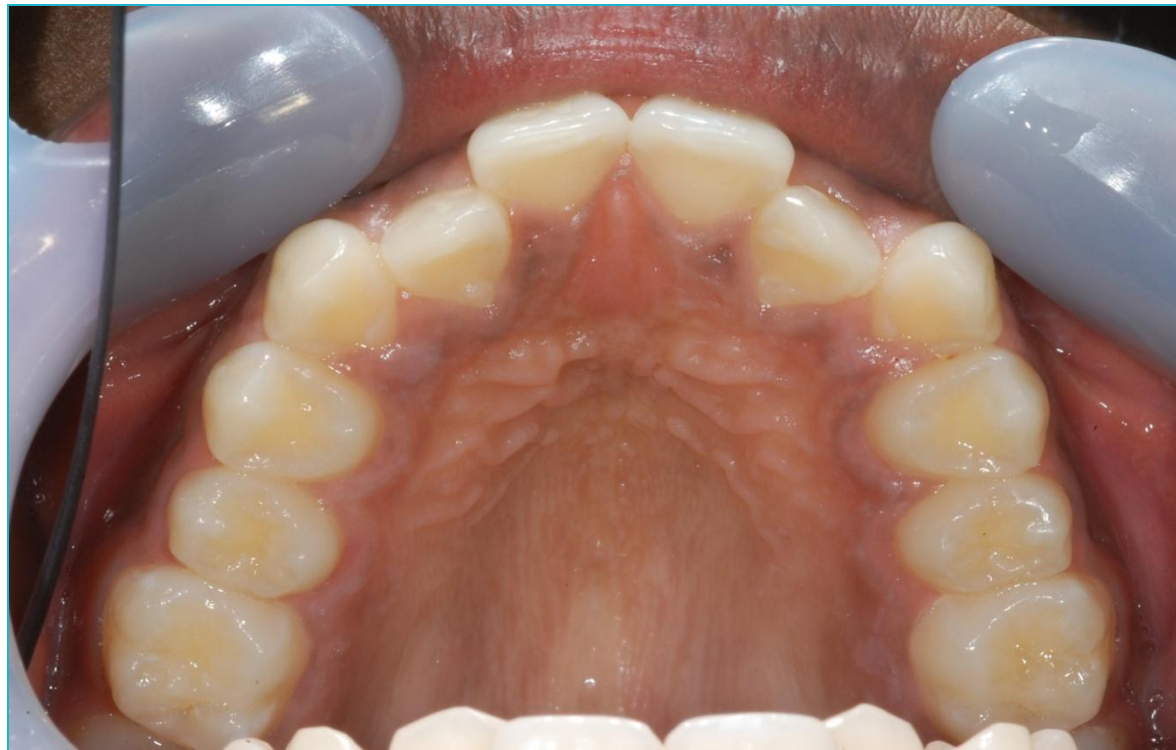
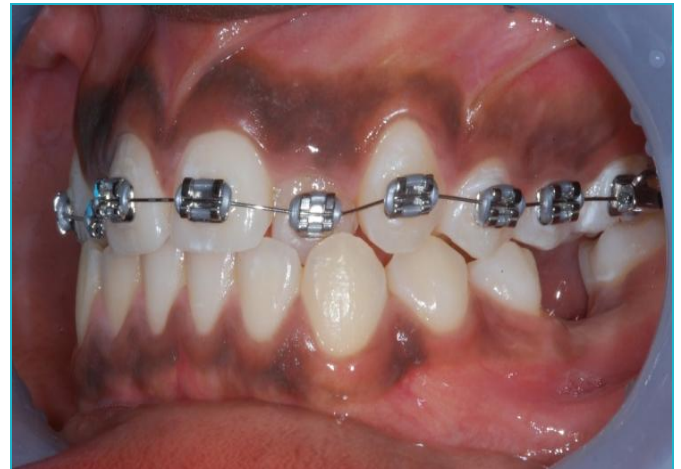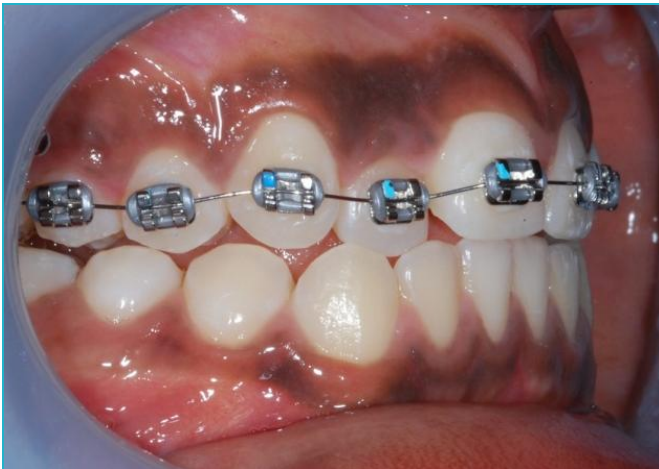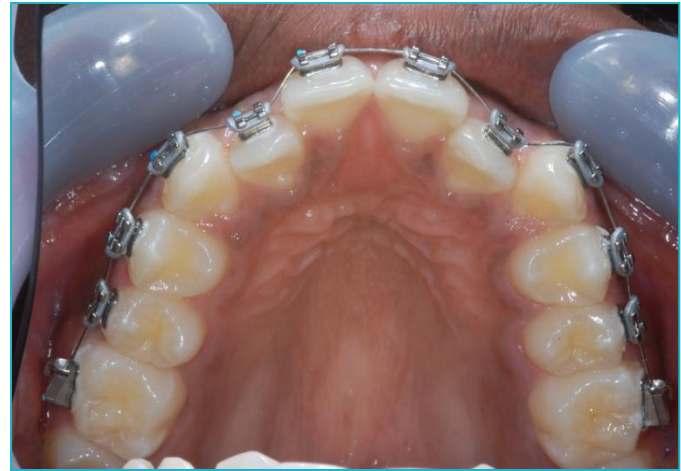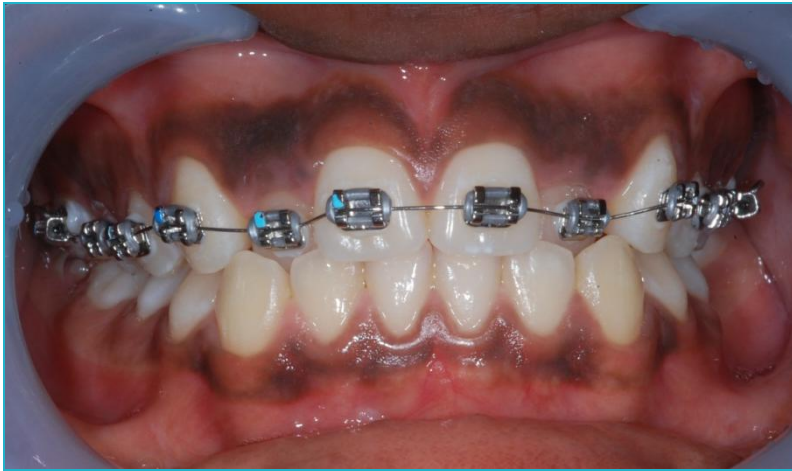Tosin was concerned about his irregular upper teeth



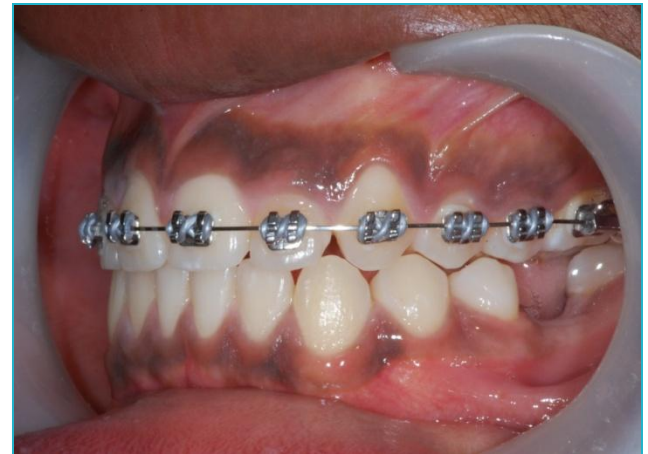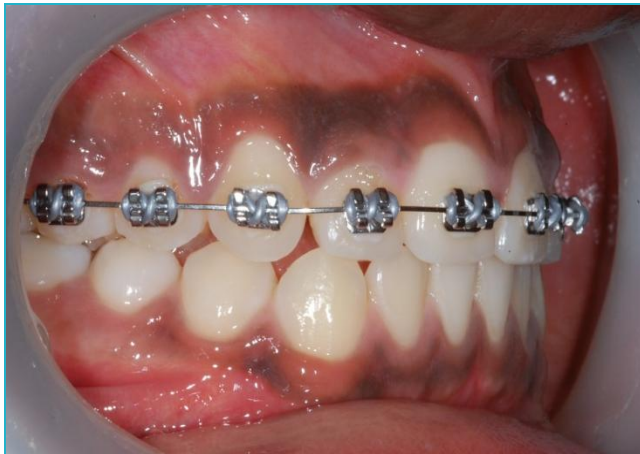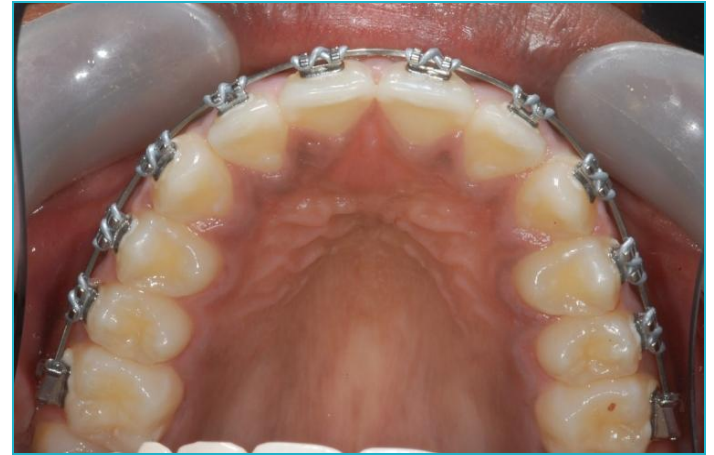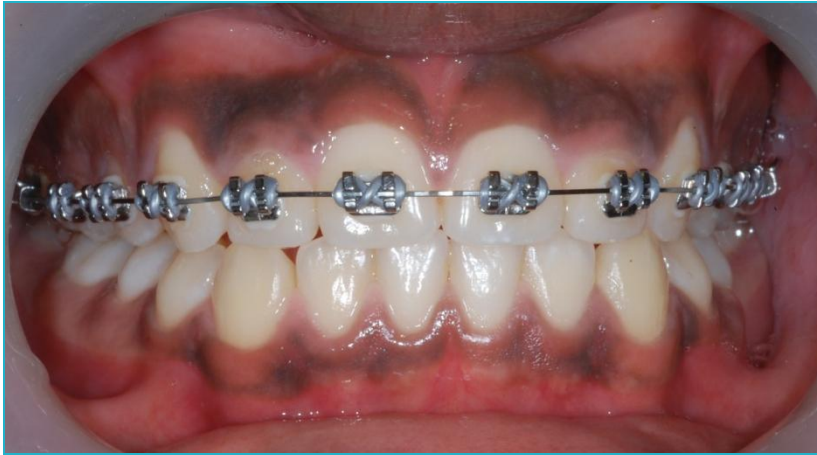The Upper Lateral Incisors were palatally positioned



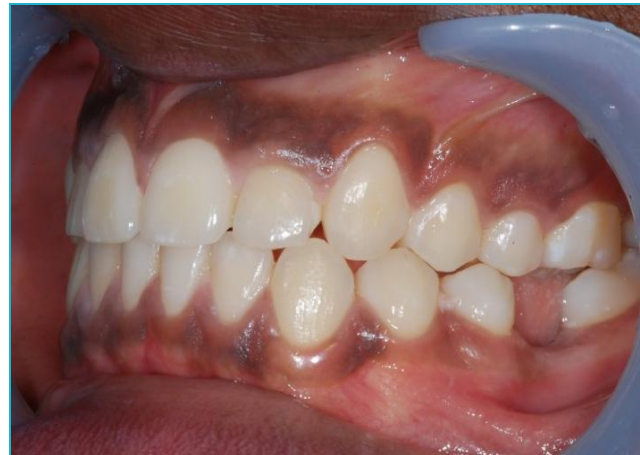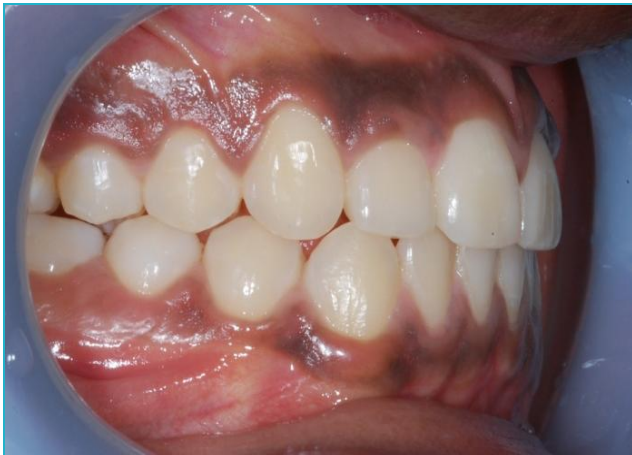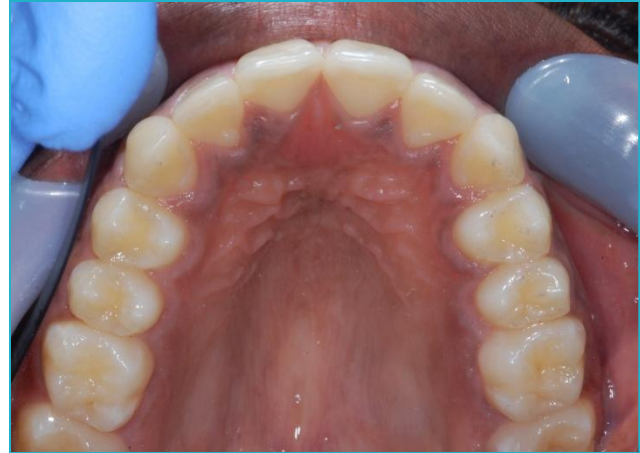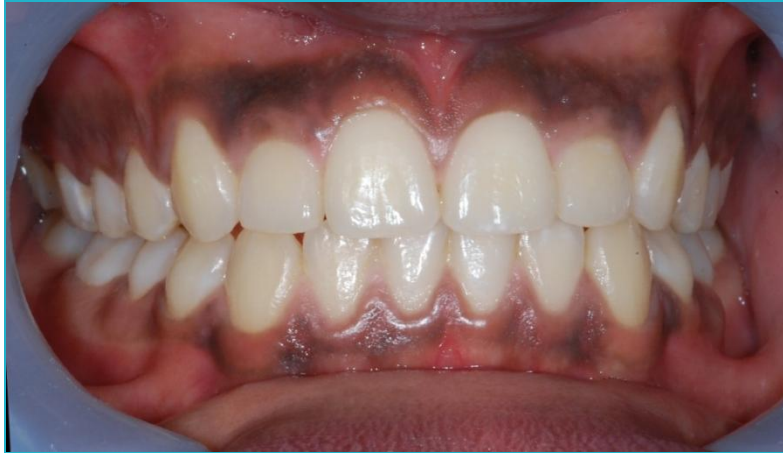An upper fixed brace was used



After 3 months

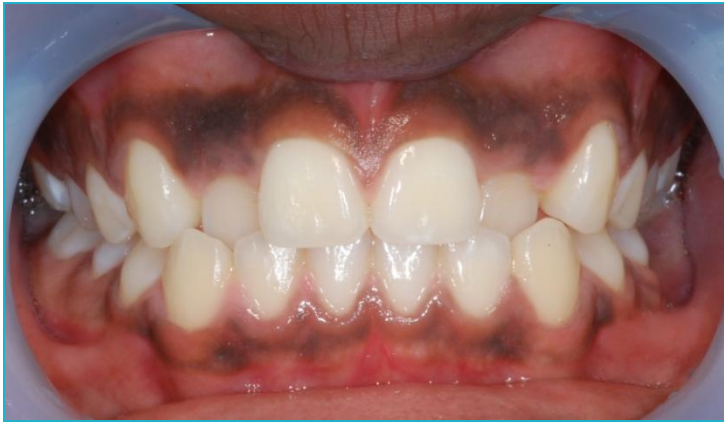

The finished result

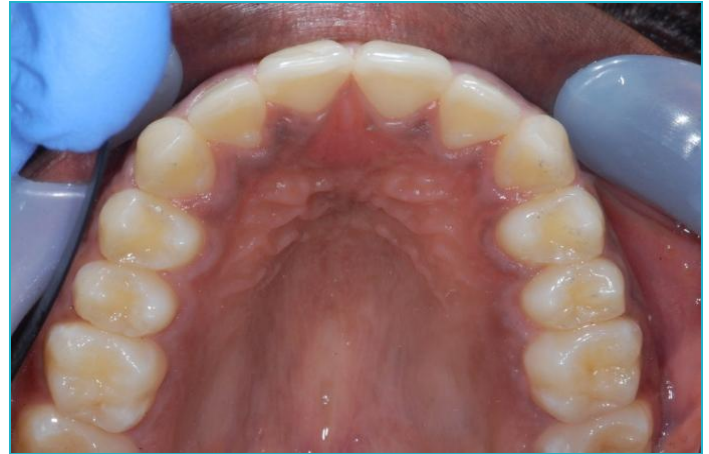
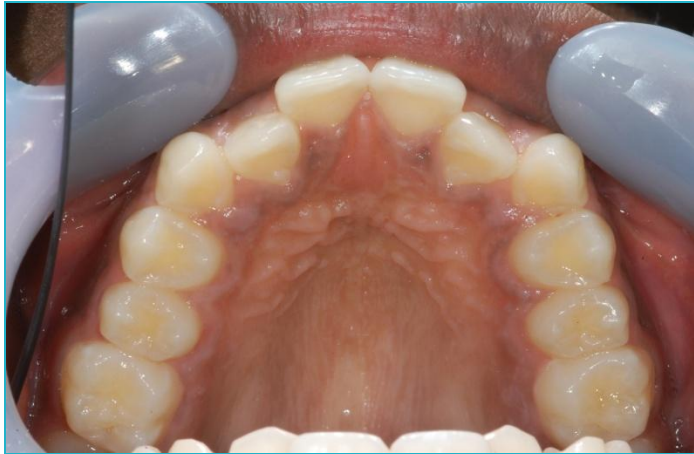
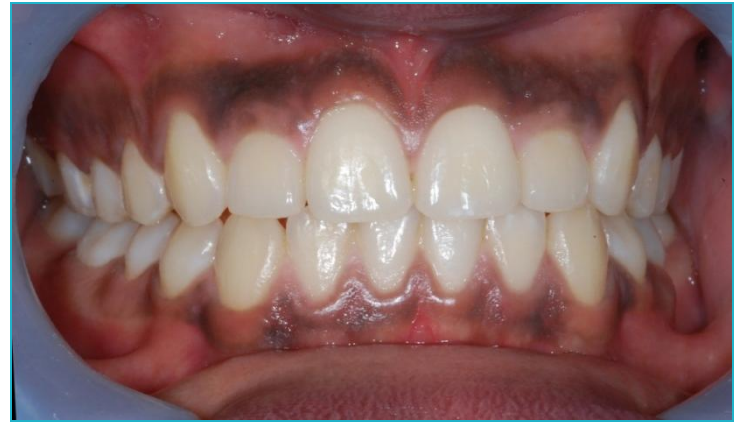6 months treatment

Before




After



Before



After



Smile Created By



Confidence in your smile