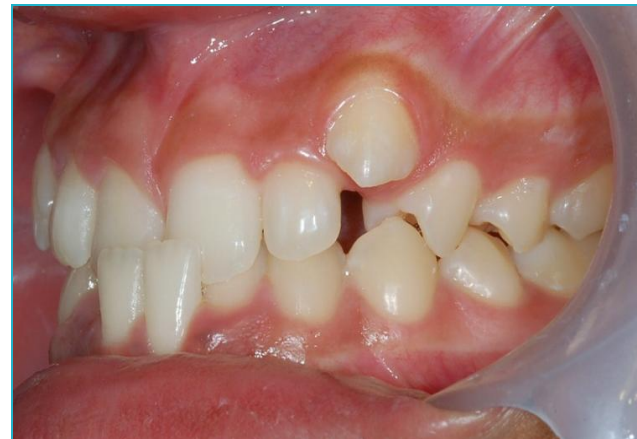
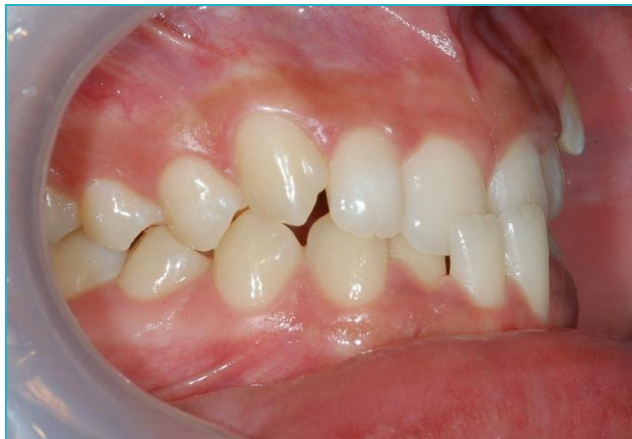
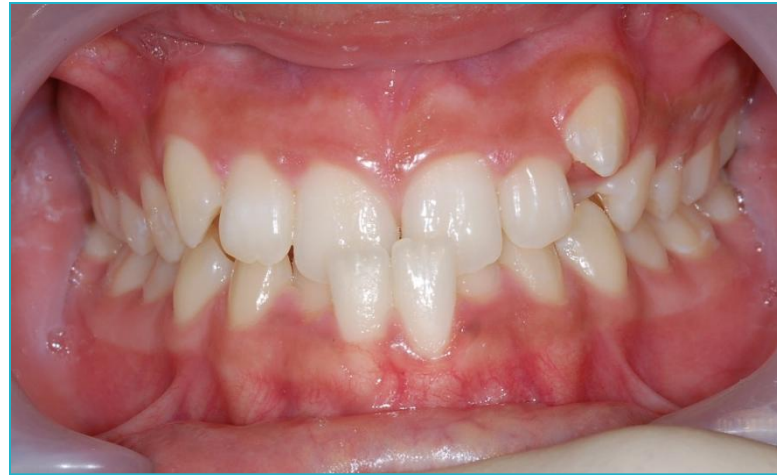
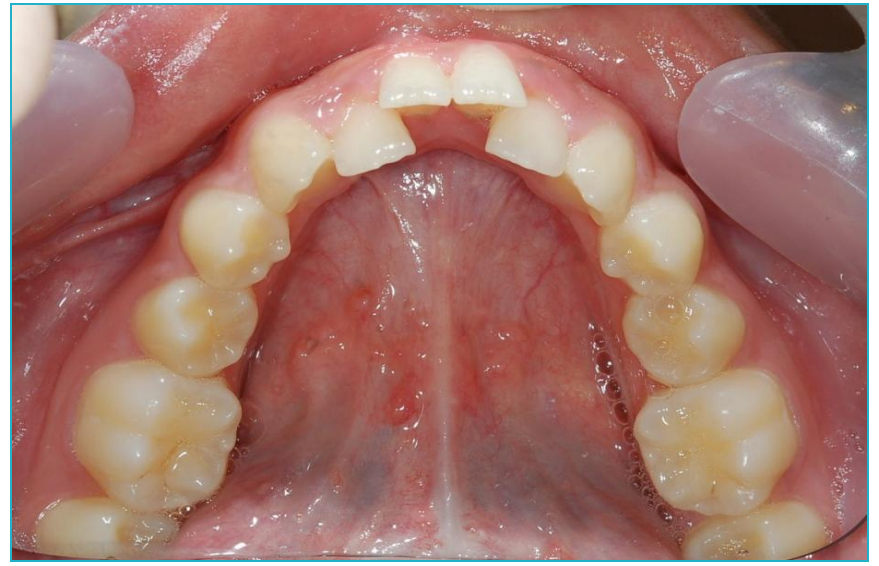
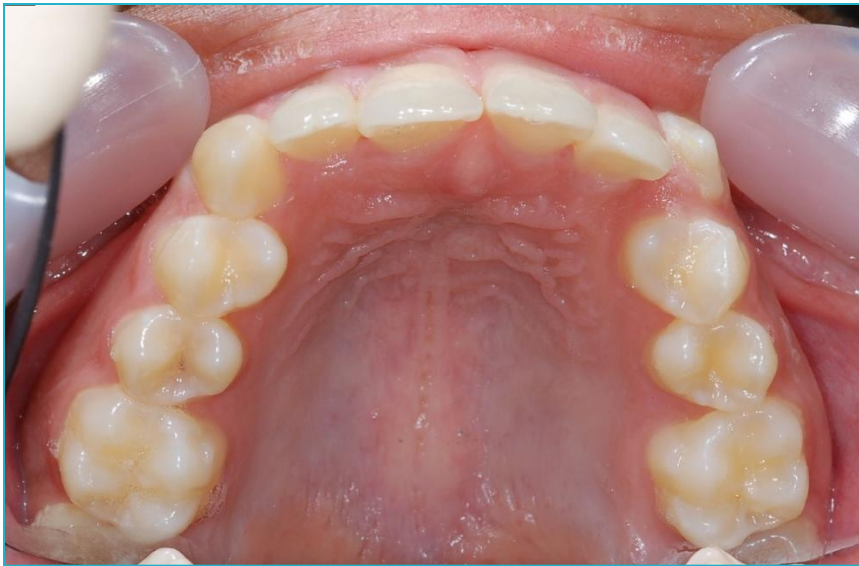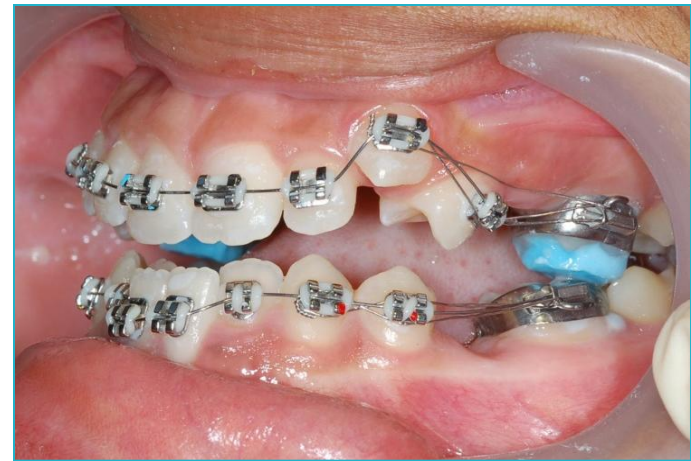
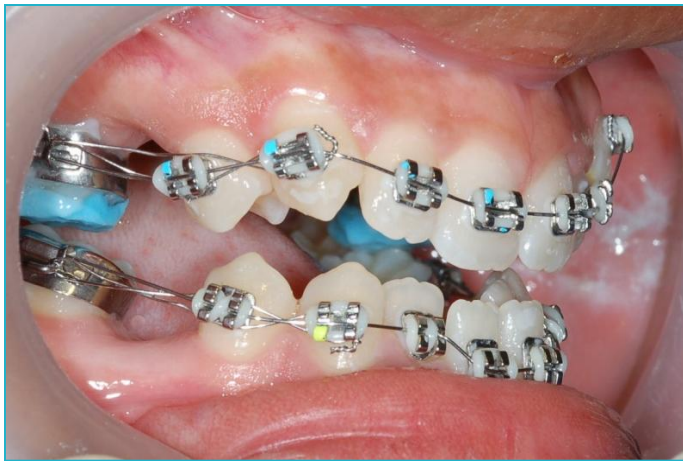
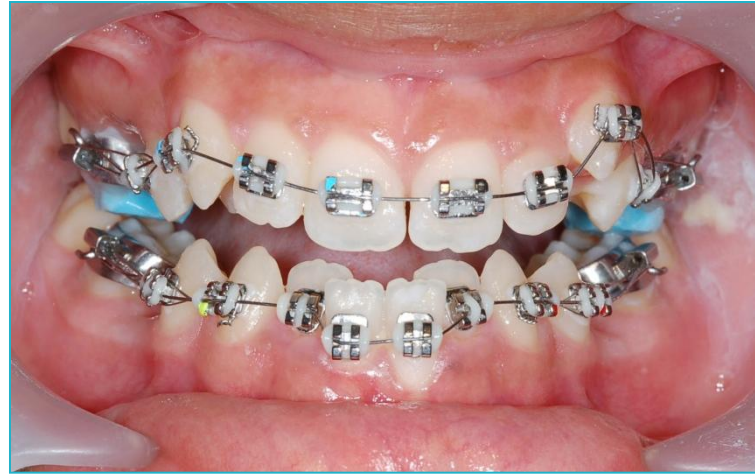Antonia presented at 14 years



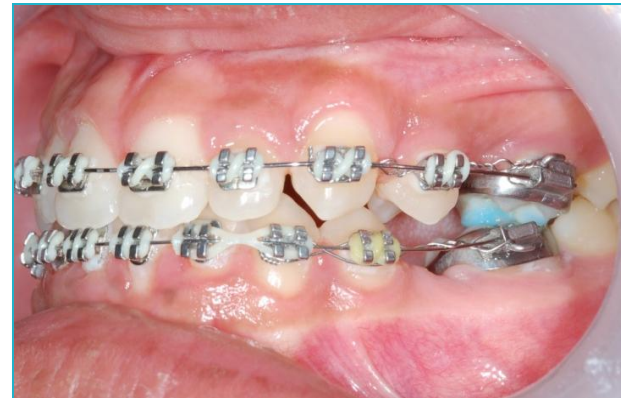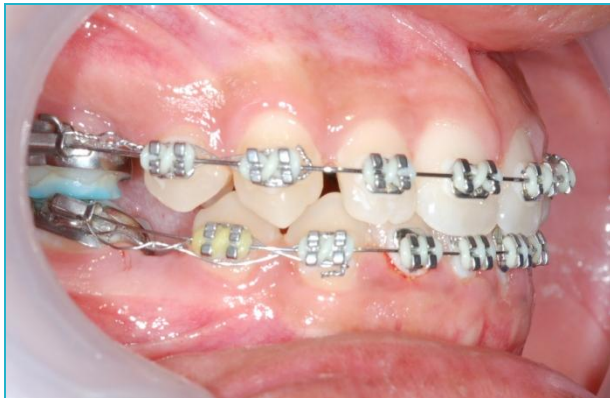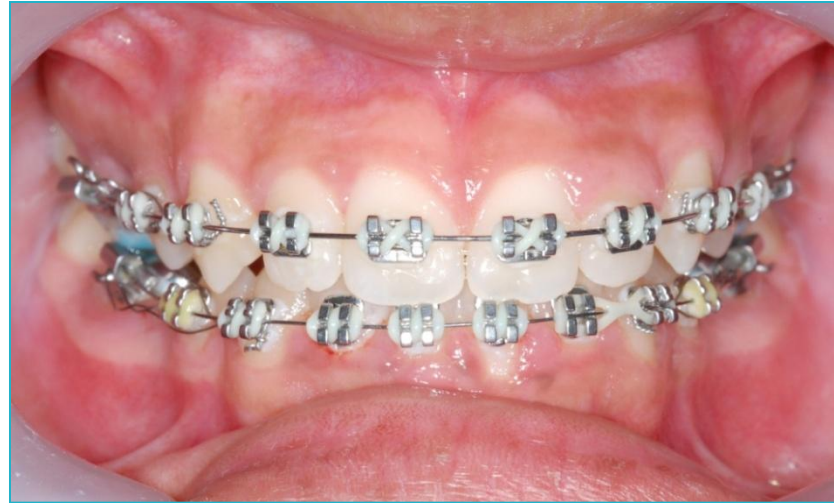Crowded upper and lower arches



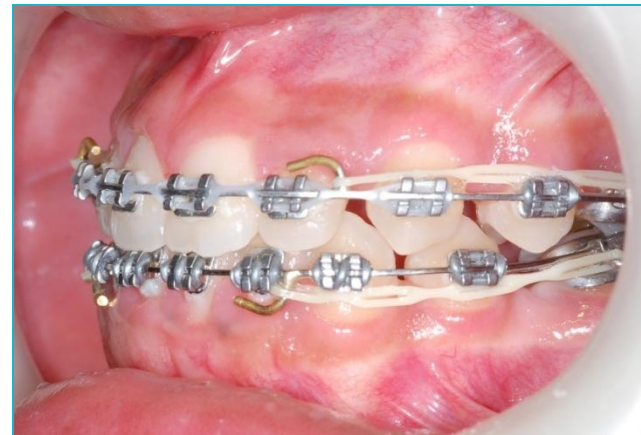
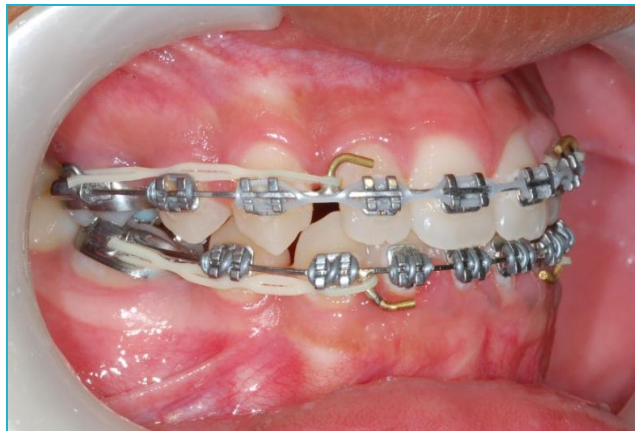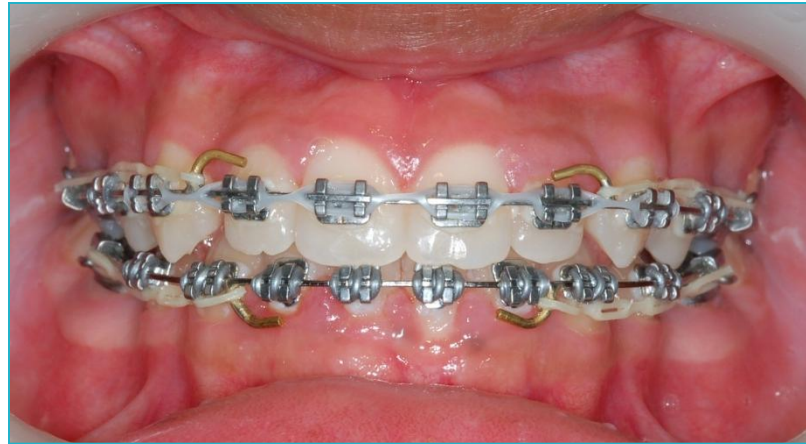All four second premolars were extracted and Dr Carol Humphrey placed a fixed brace



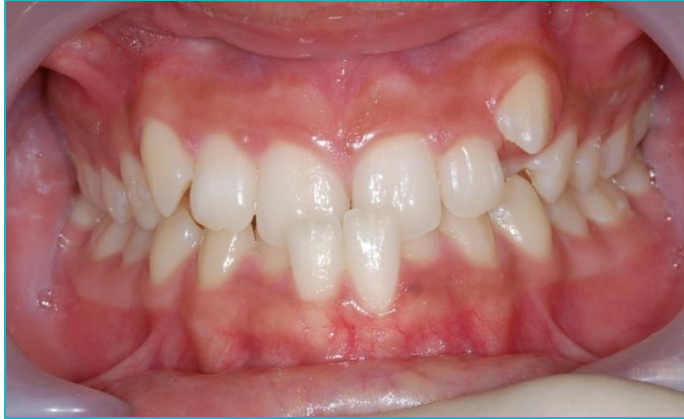Progress after 4 months



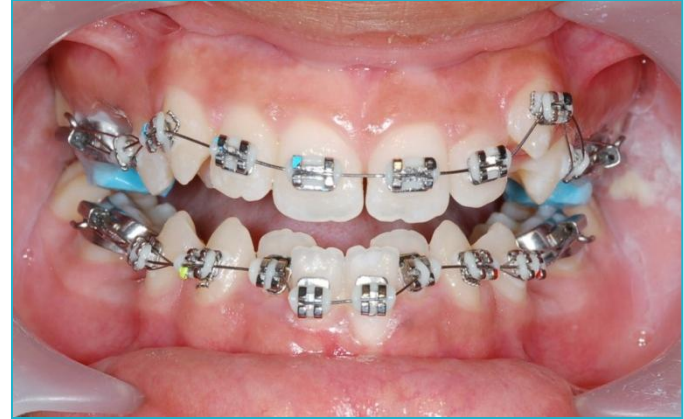Progress after 12 months



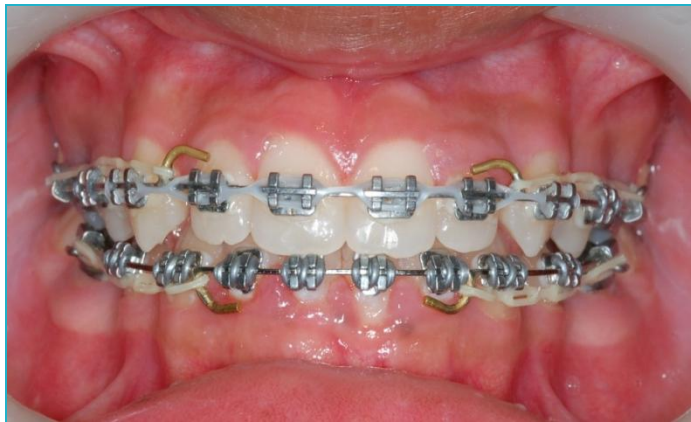Progress



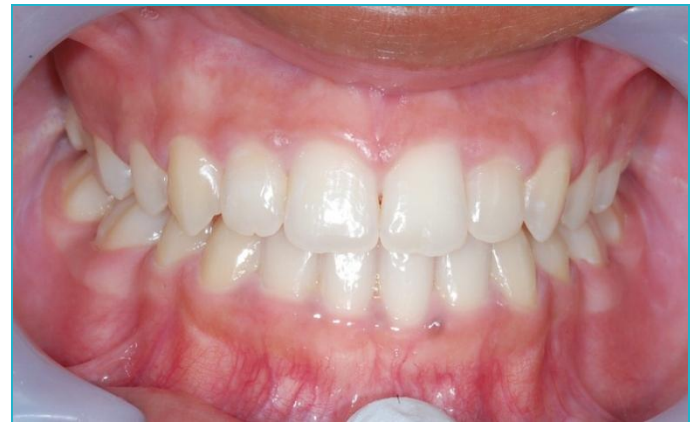1



2



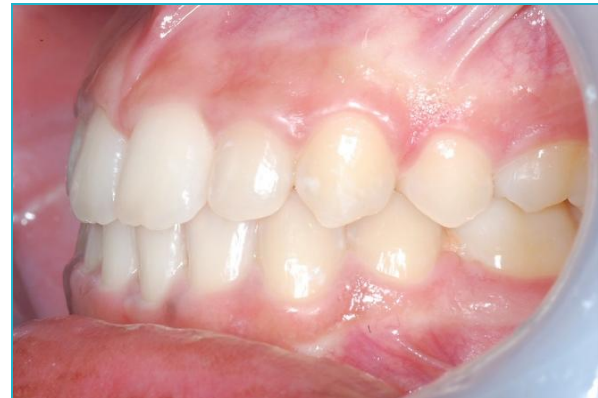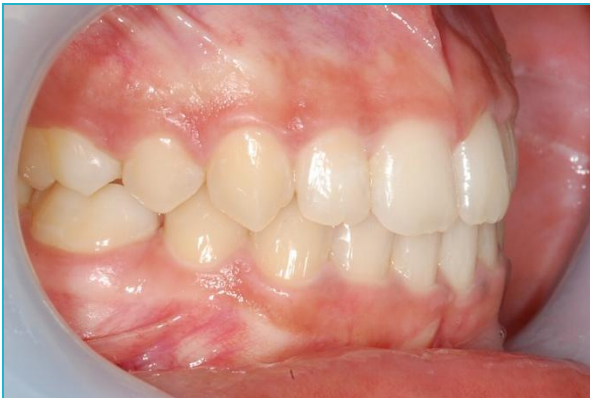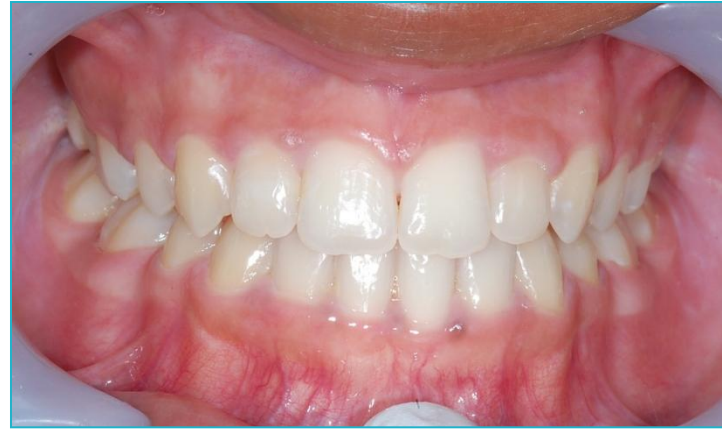3



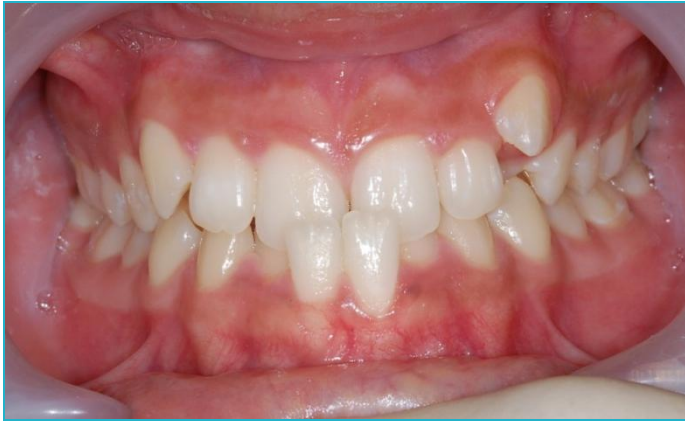4



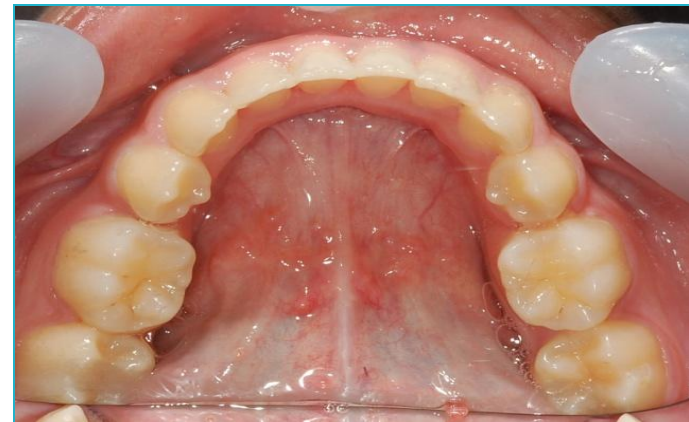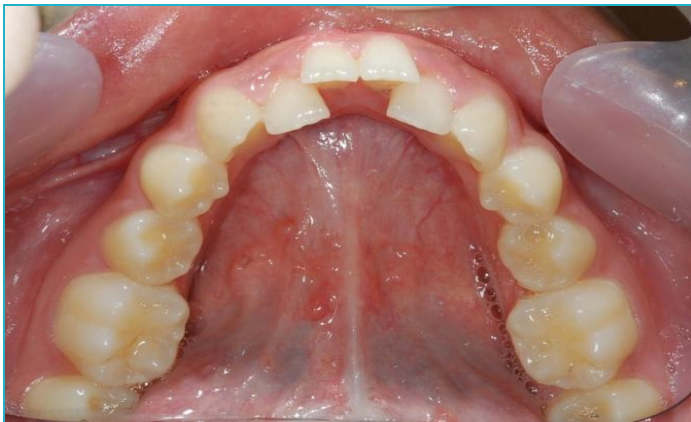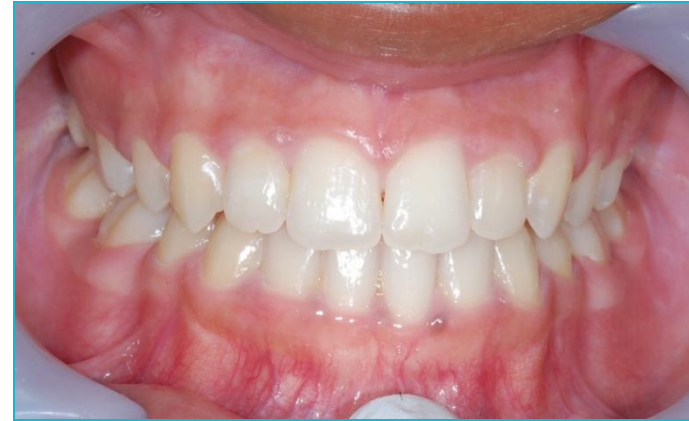Finished Result



Before

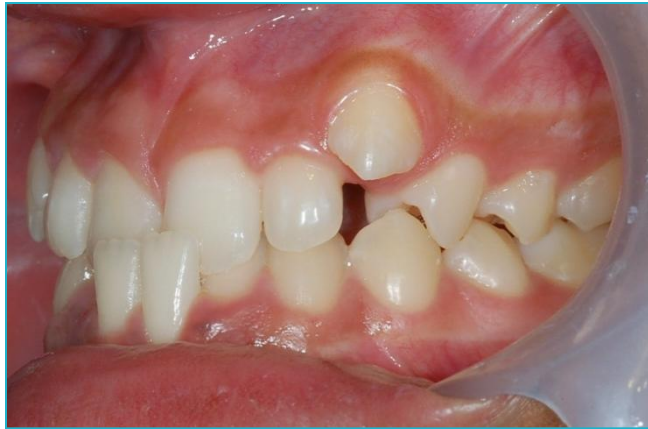

After

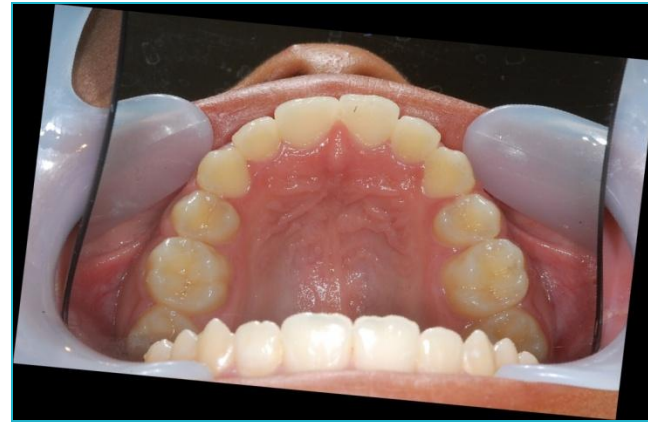
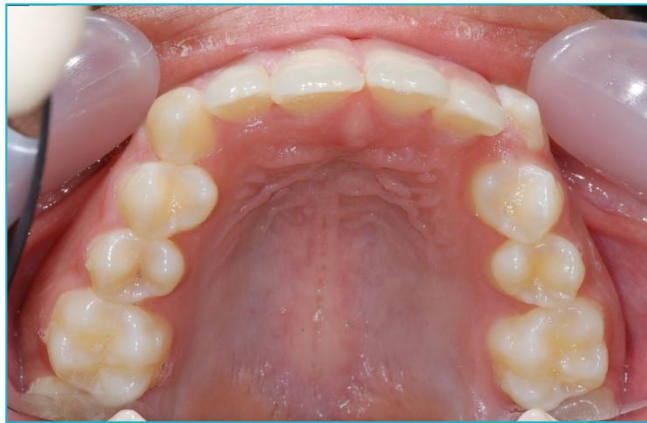
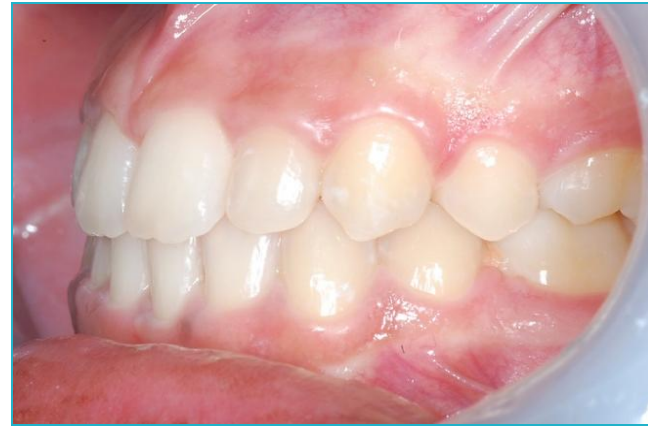20 months treatment

Before



After



Before



After



Smile Created By



Confidence in your smile