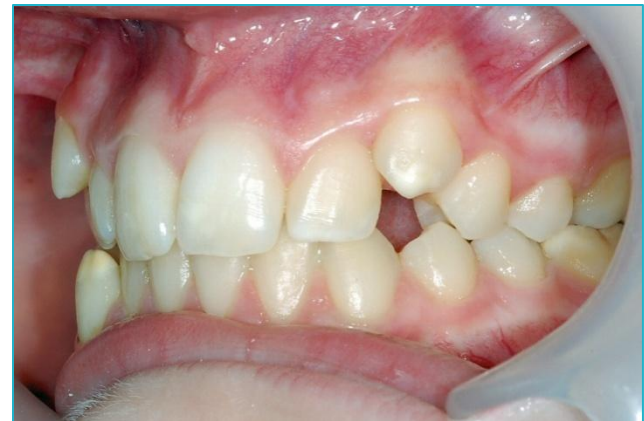
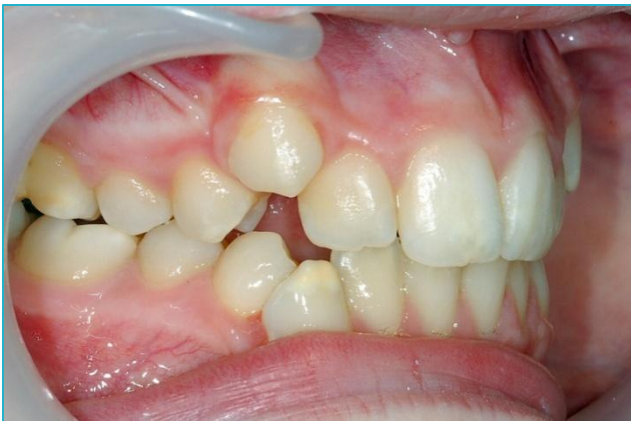
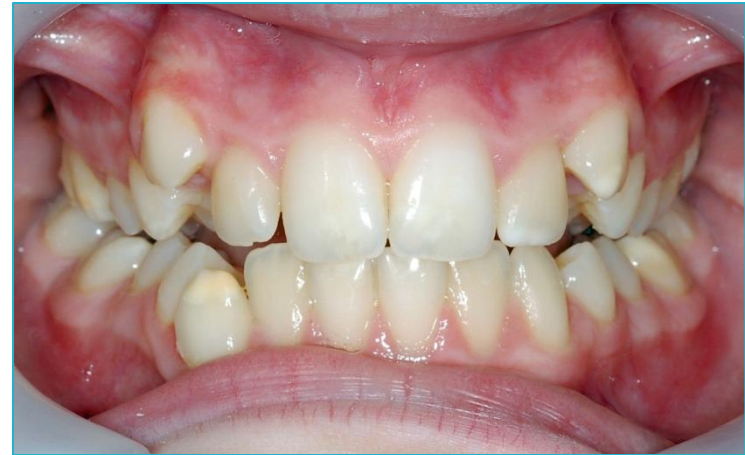
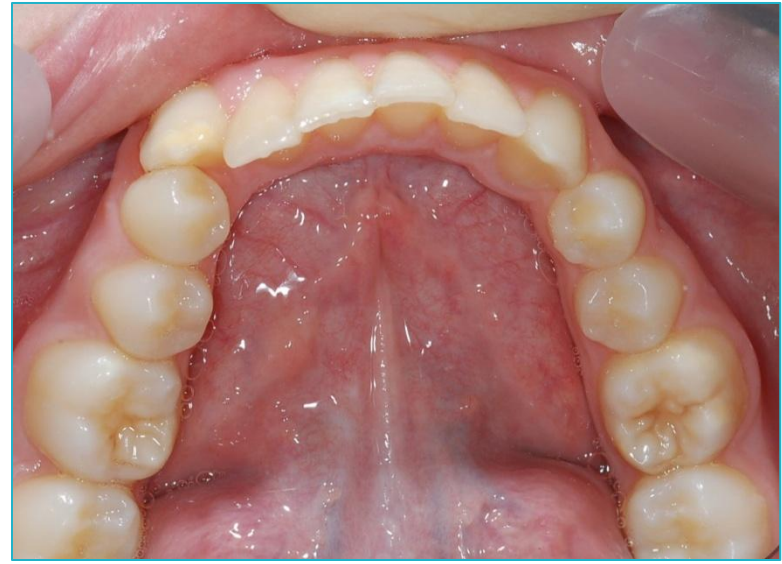
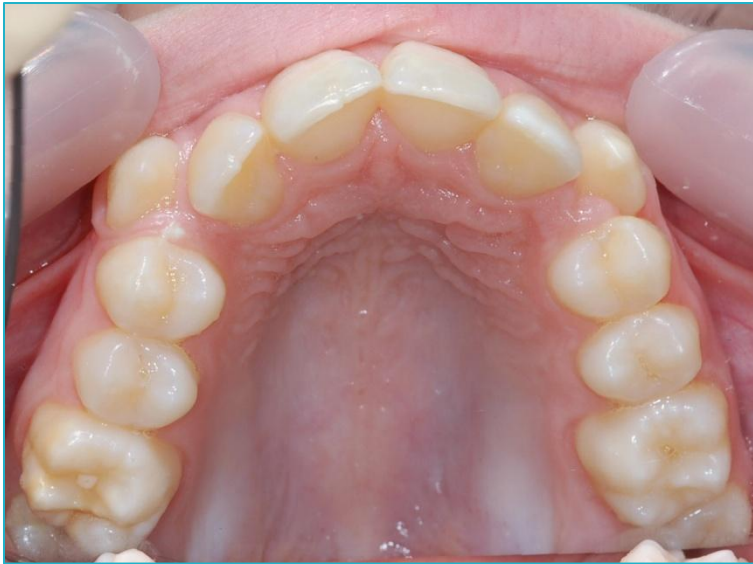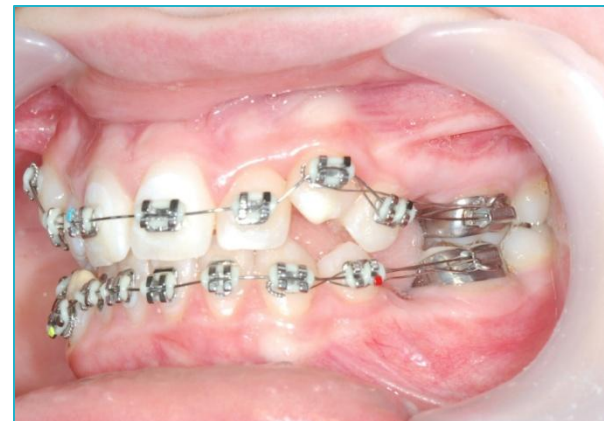
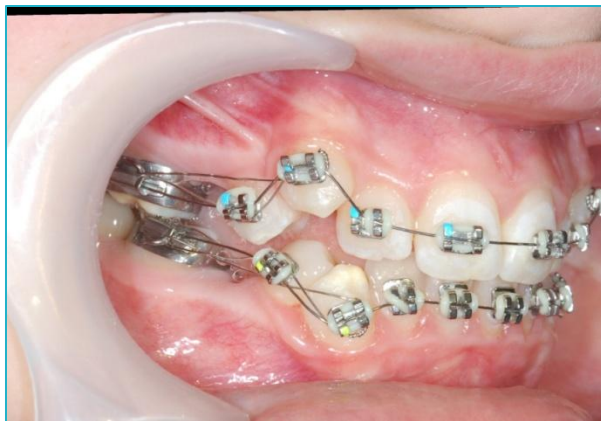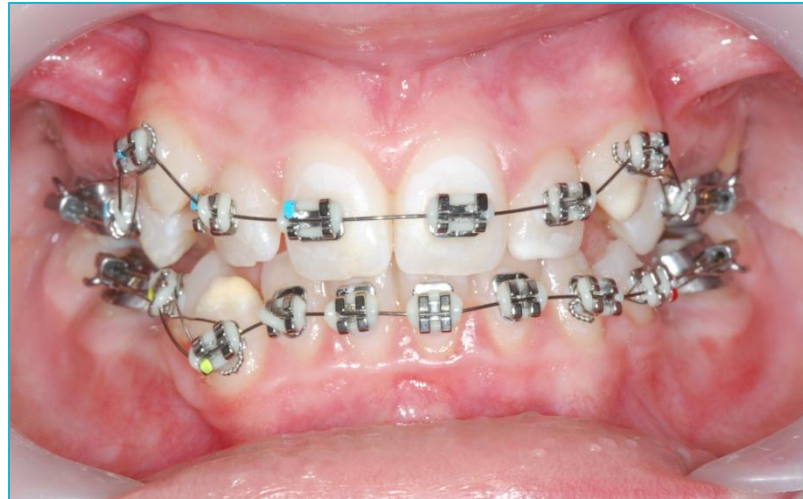
Amy presented at 12 years



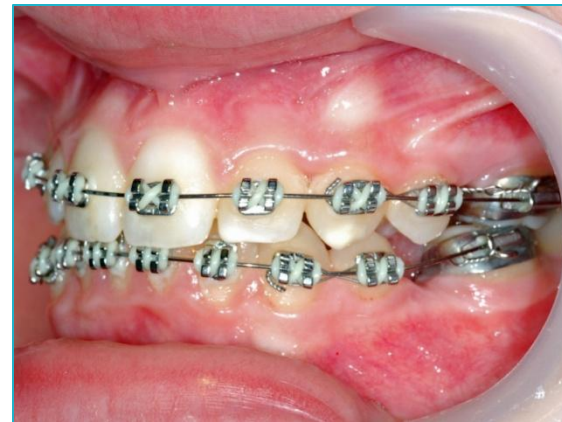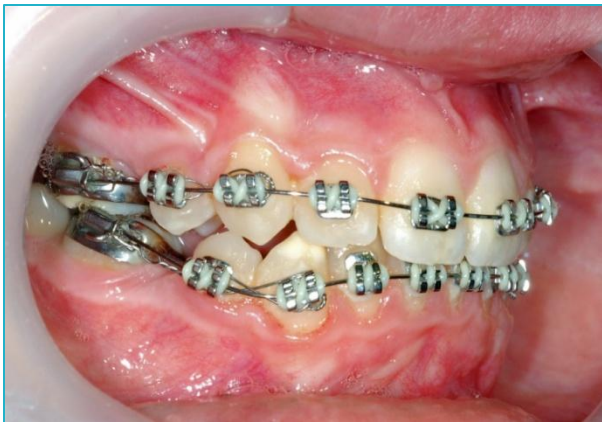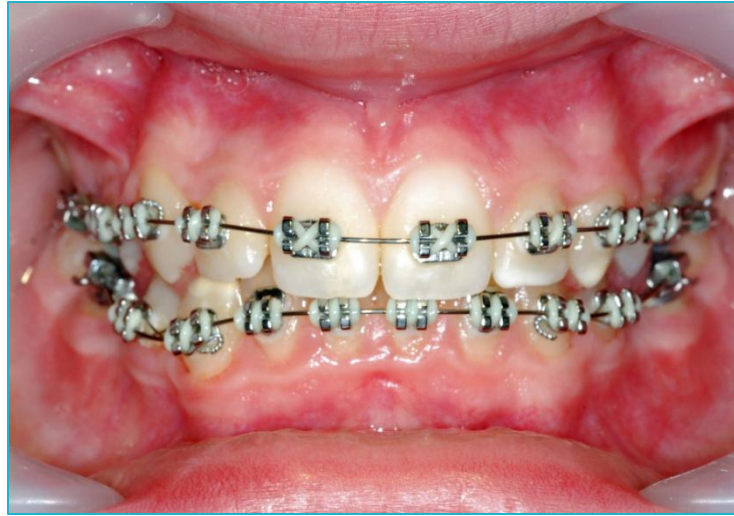Crowded upper and lower arches



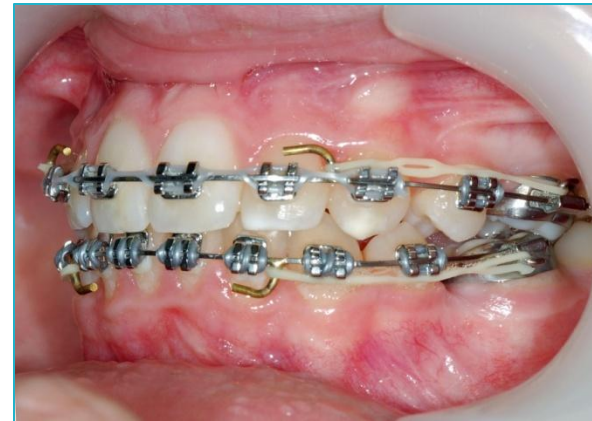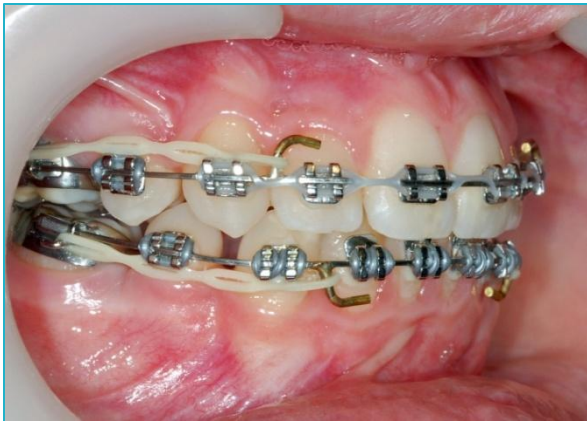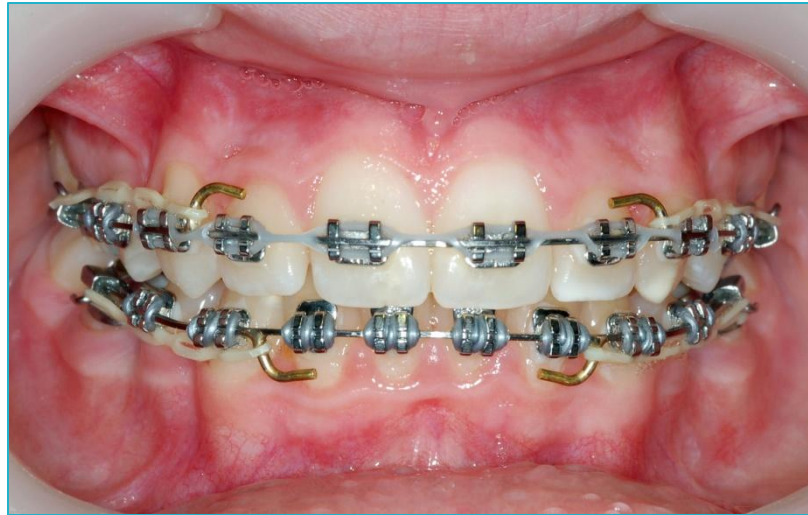All four second premolars were extracted and Dr Carol Humphrey placed a fixed brace



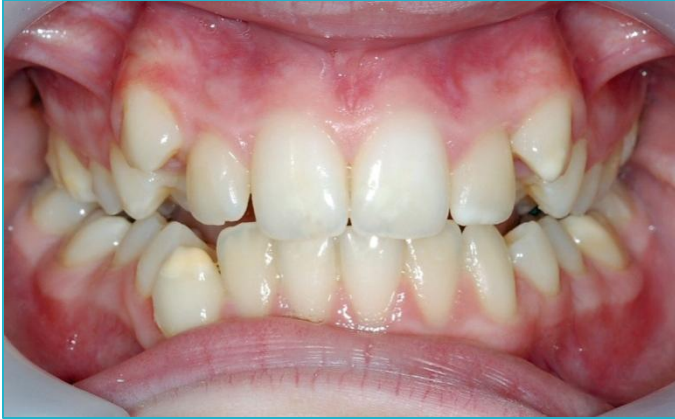Progress after 2 months



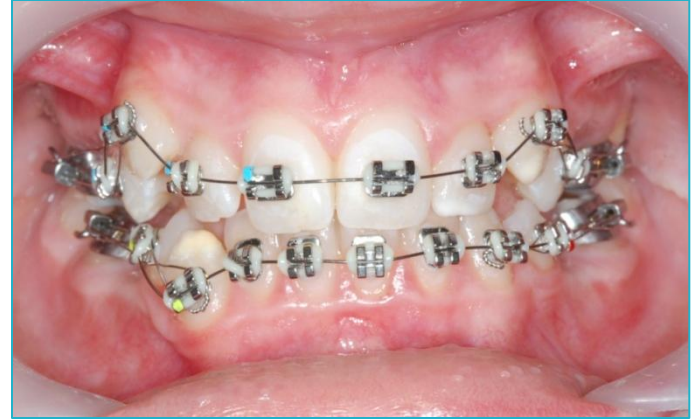Progress after 6 months



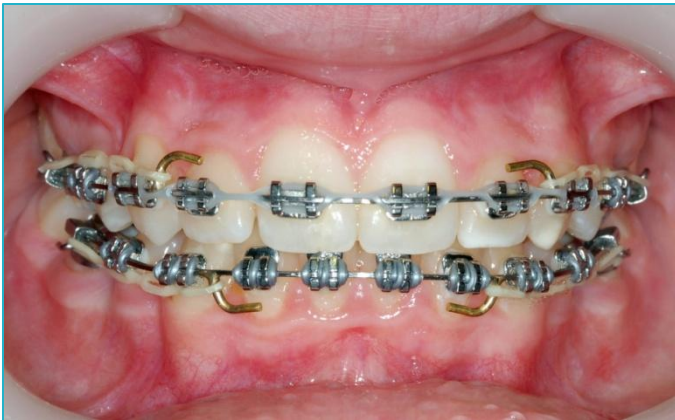Progress



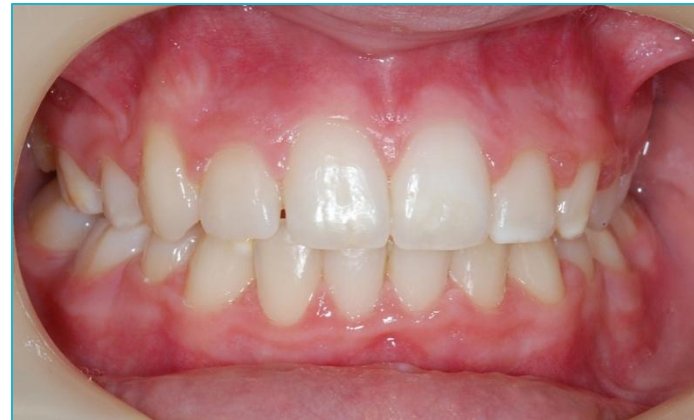1



2



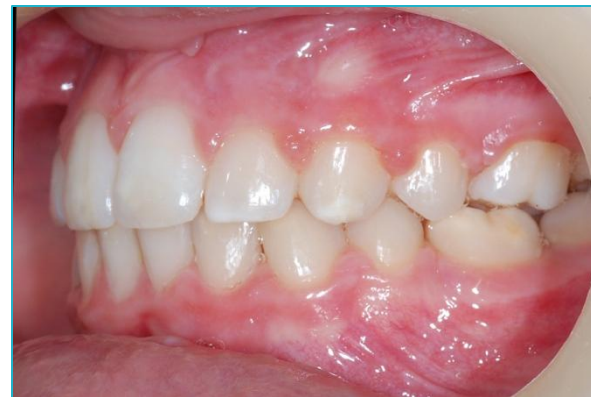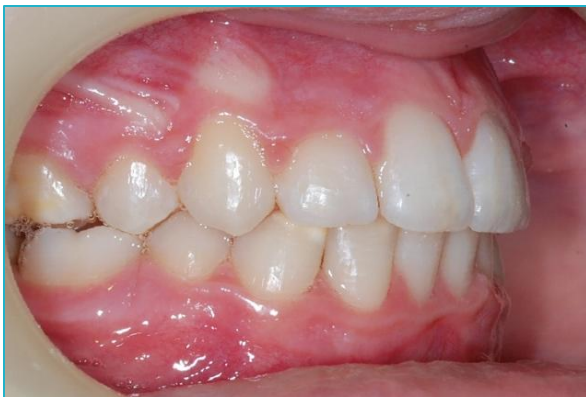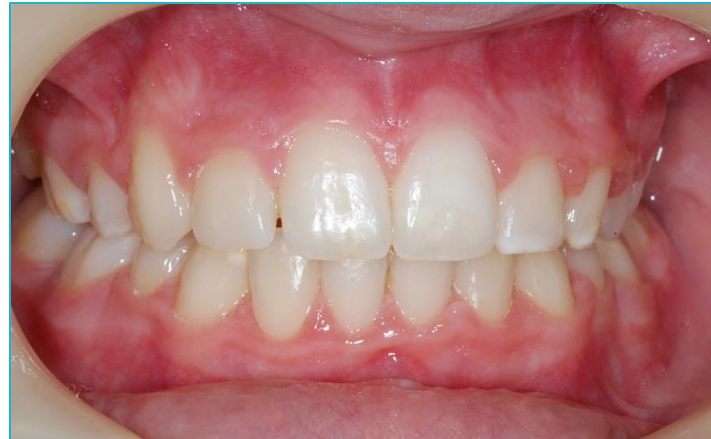3



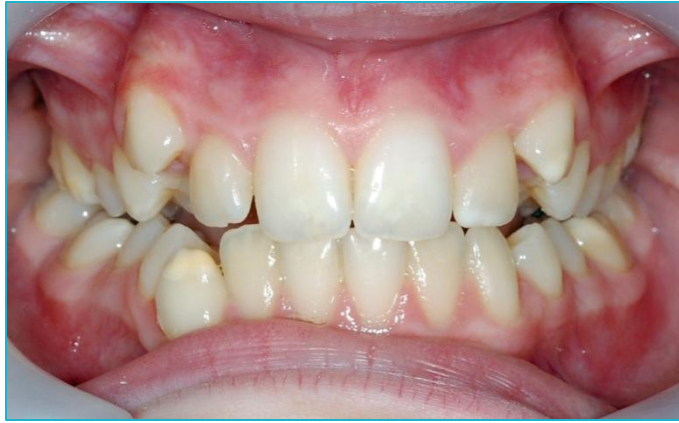4



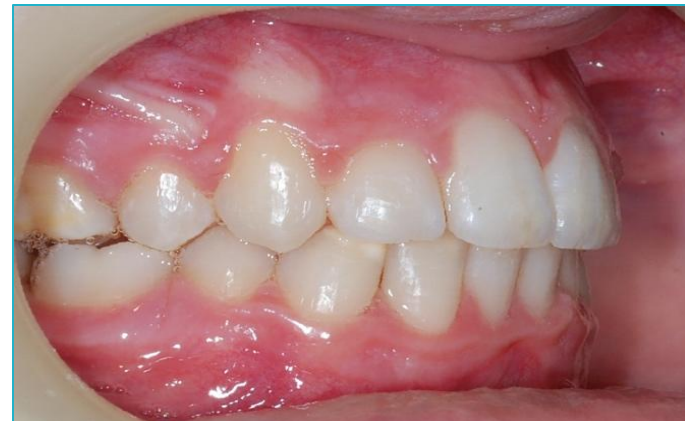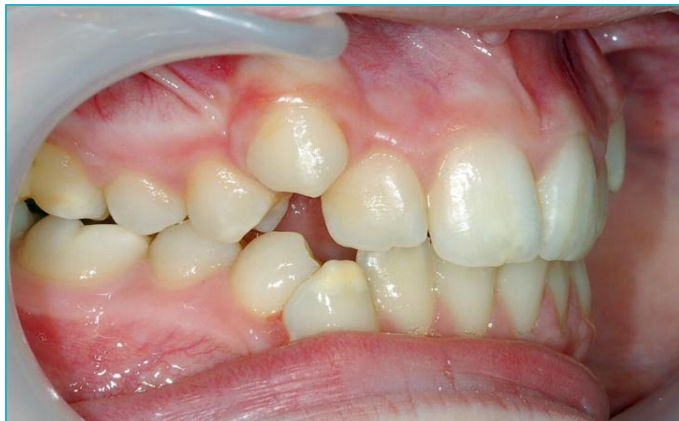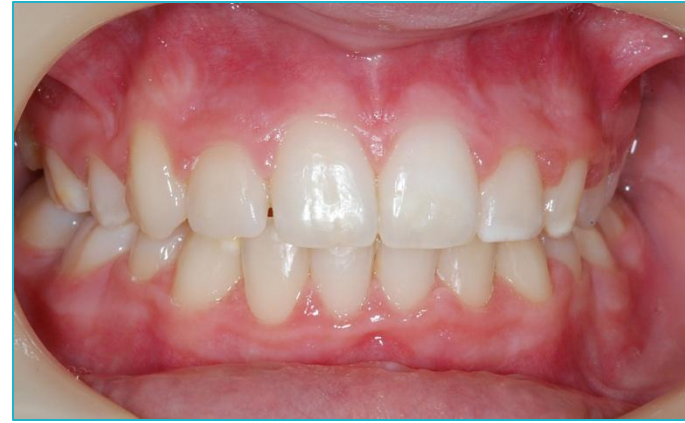Finished Result



Before



After



12 months treatment

Before



After



Smile Created By



Confidence in your smile