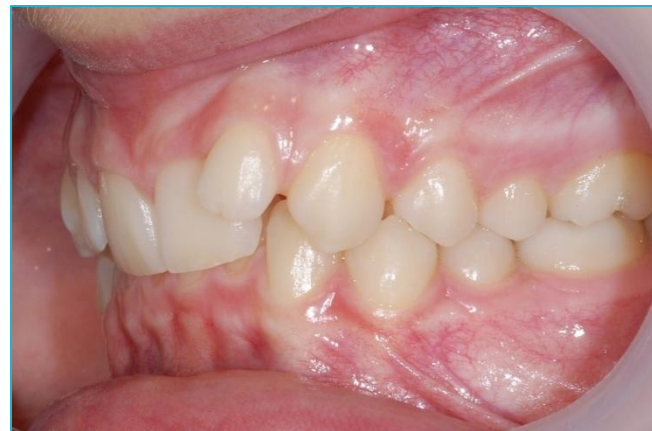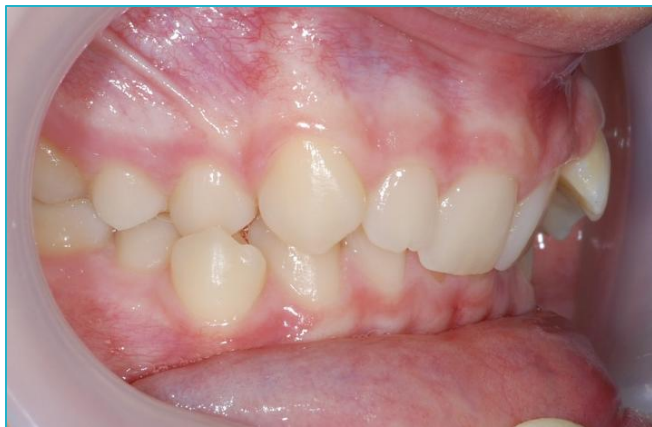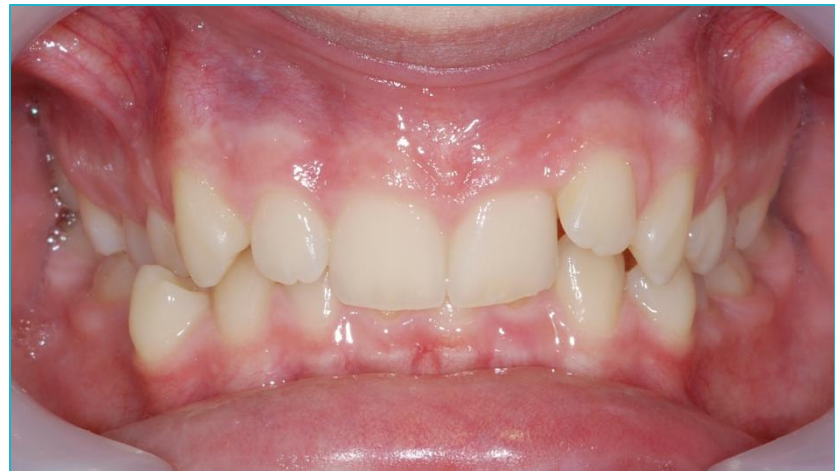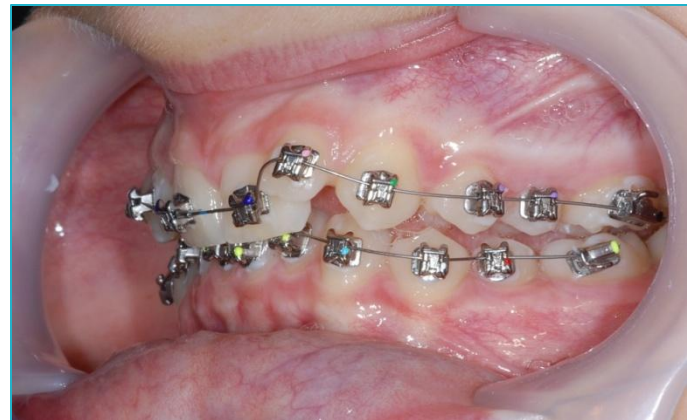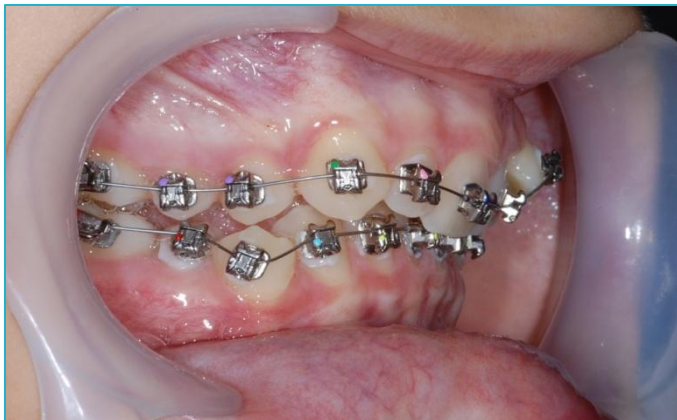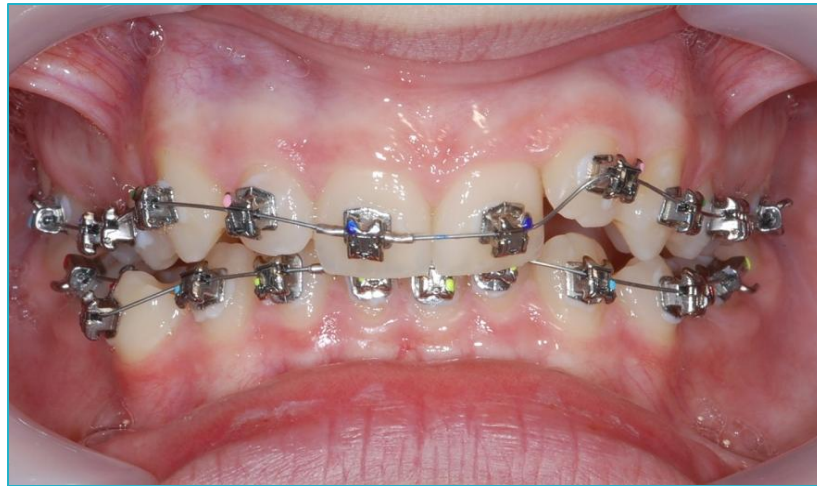




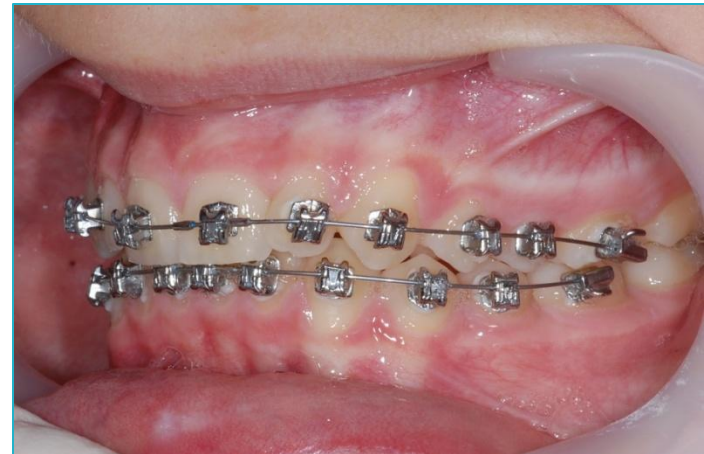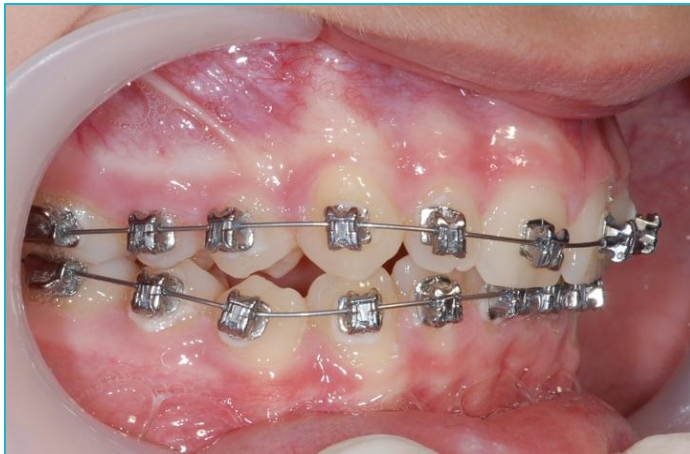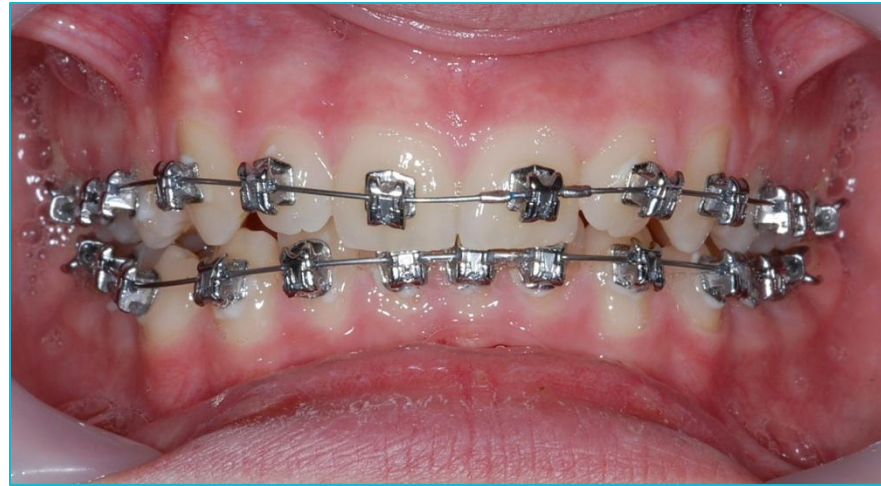**Robert presented at 12 years of age,  
concerned about his very irregular  
front teeth**



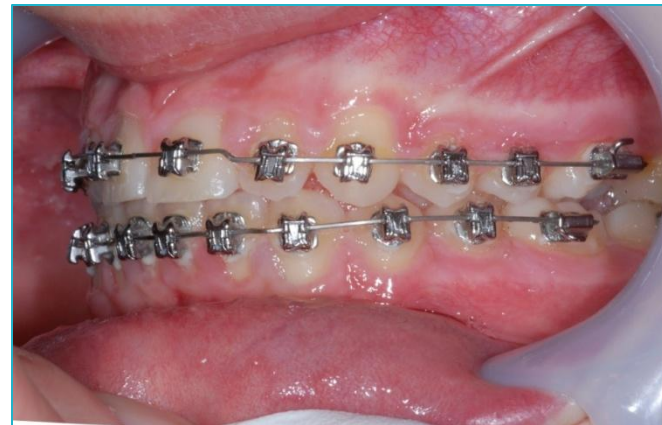
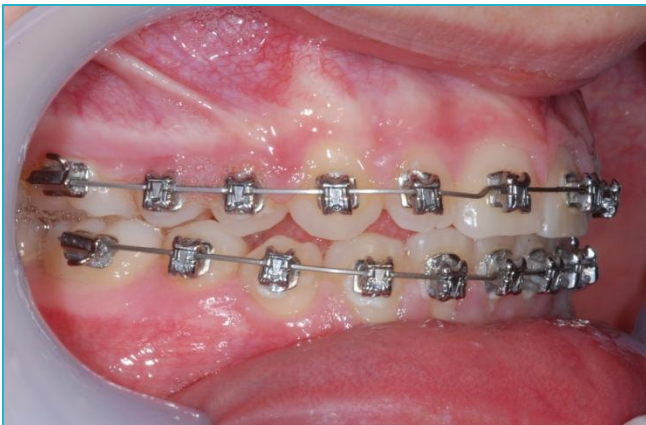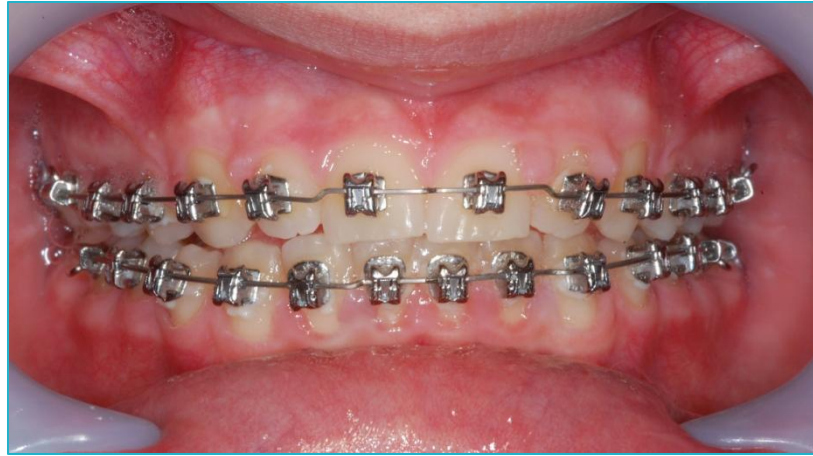**Dr Horobin used the Damon 3MX Brace, without extractions.**



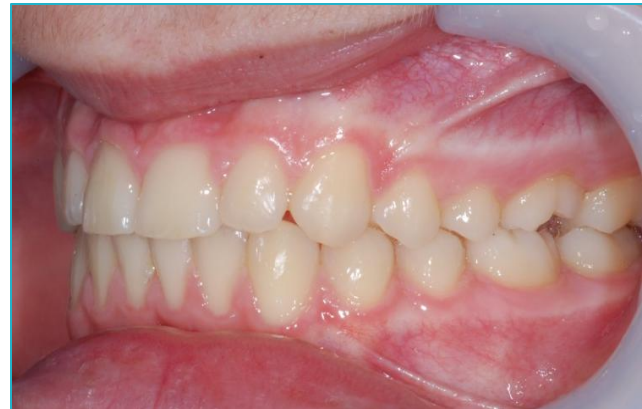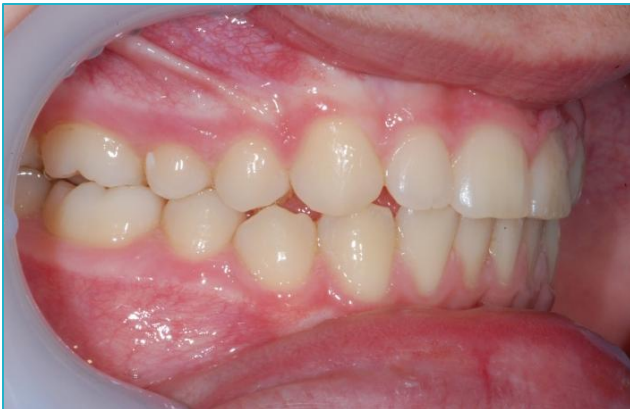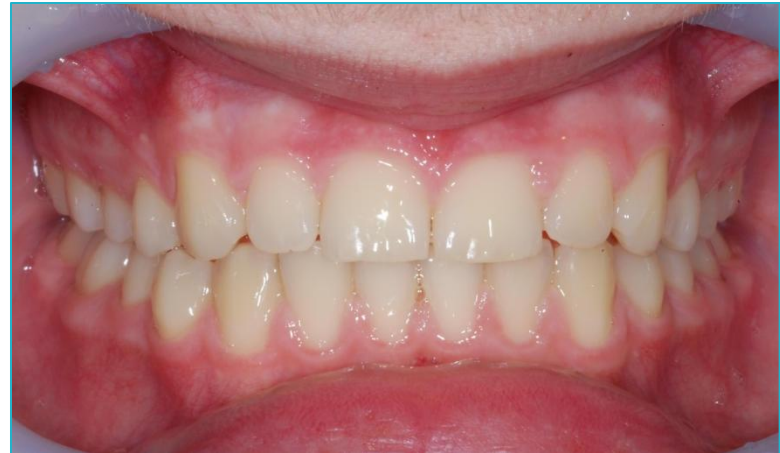## Progress after 3 months



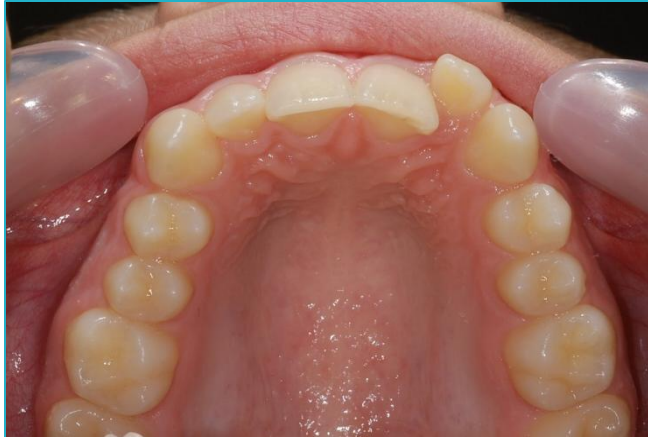## Progress after 16 months



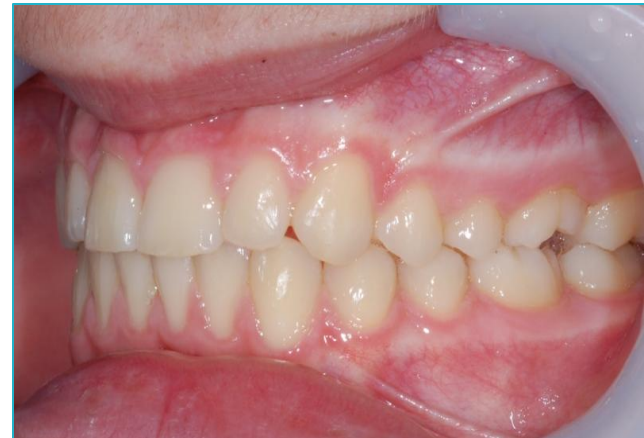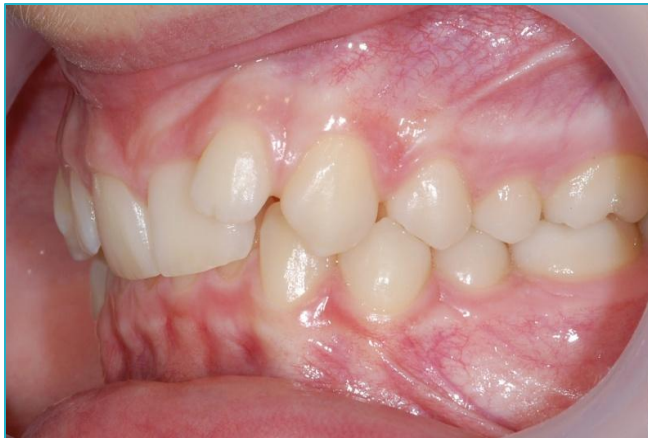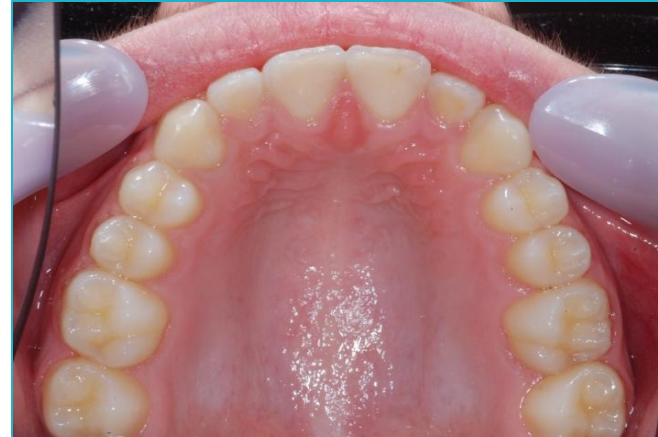## Finished Result after 18 months




**Before**



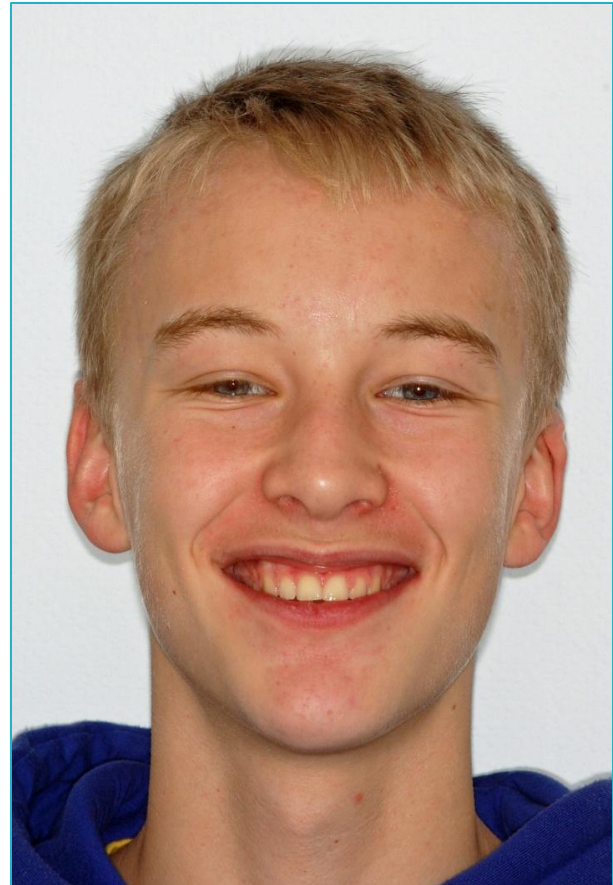**After**



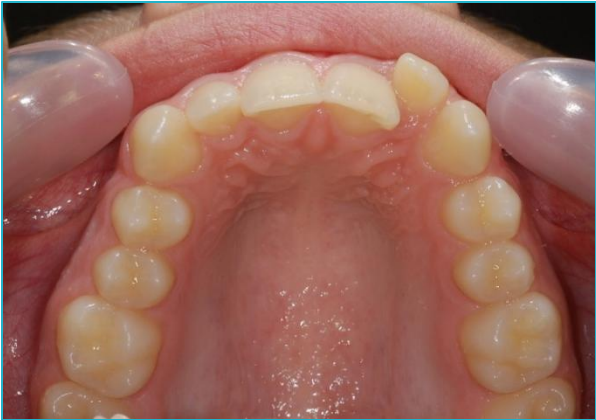**Before**



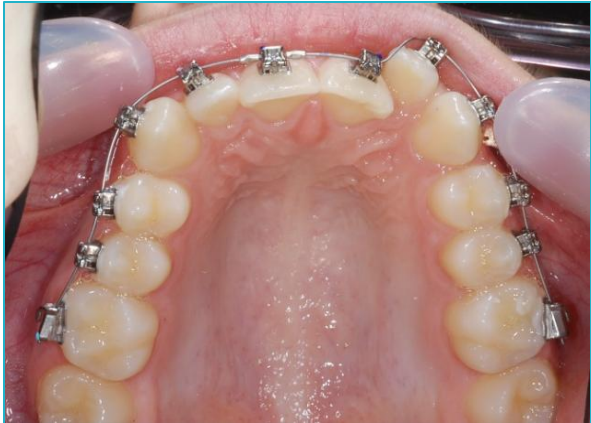**After**



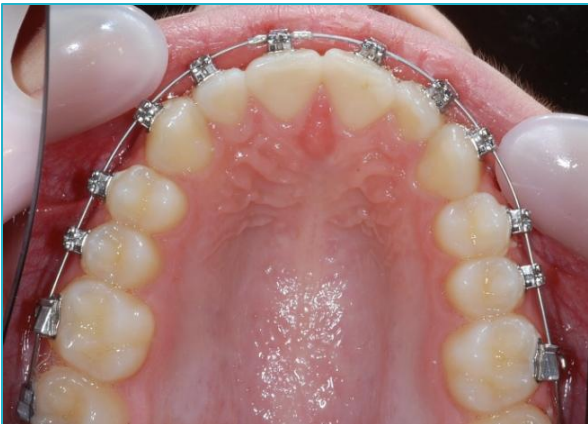# Upper arch sequence



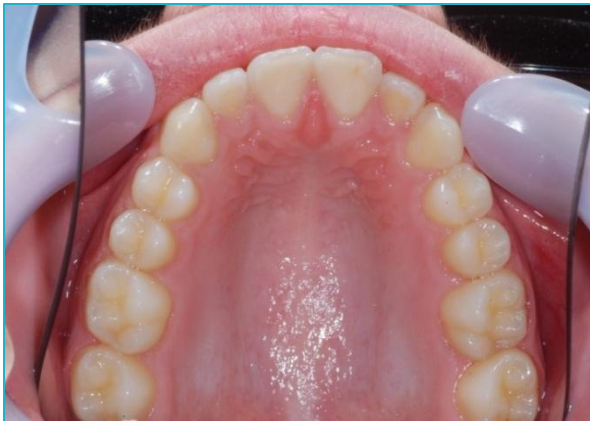1



2



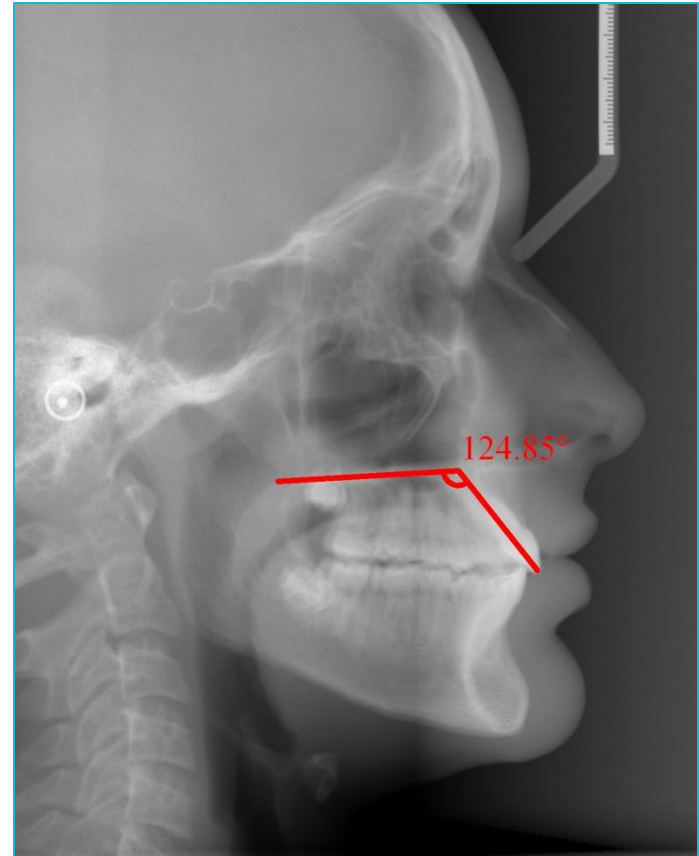
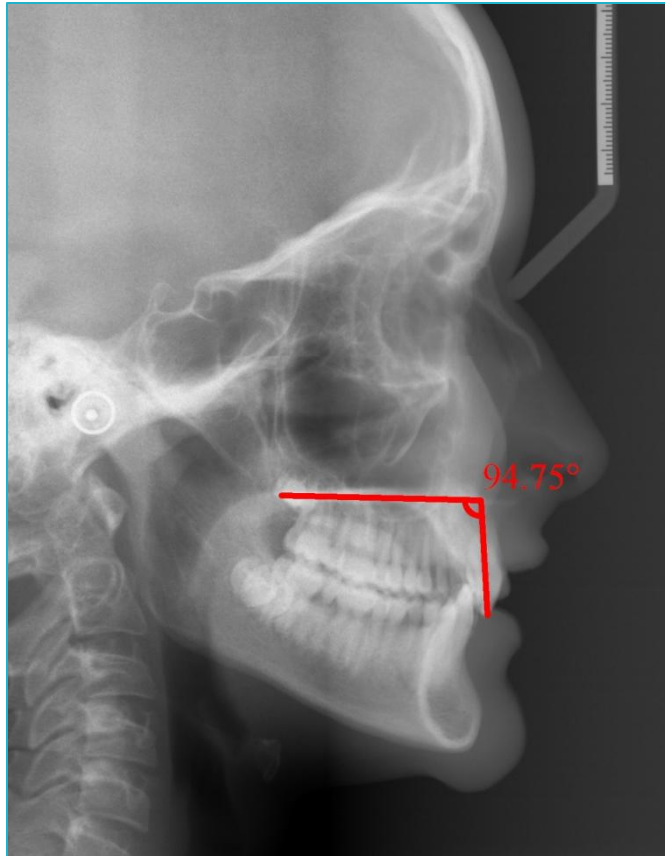3



4



## Before and after Lateral Skull Radiographs



**Note the change in incisor inclination**

**Before**



**After**



Smile Created by



*Confidence in your smile*