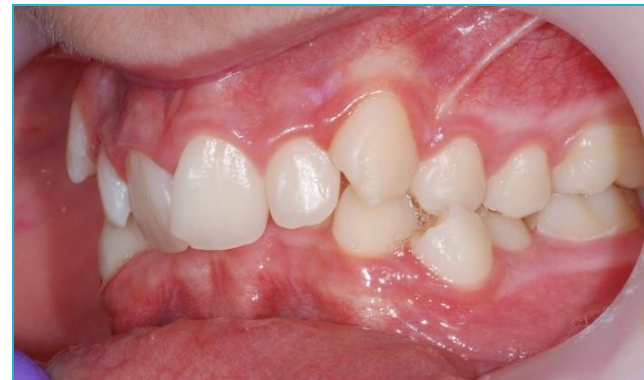
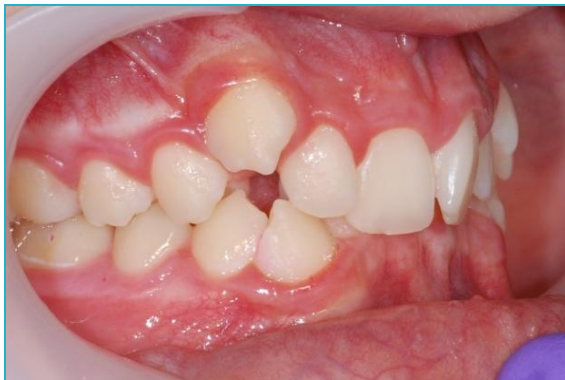
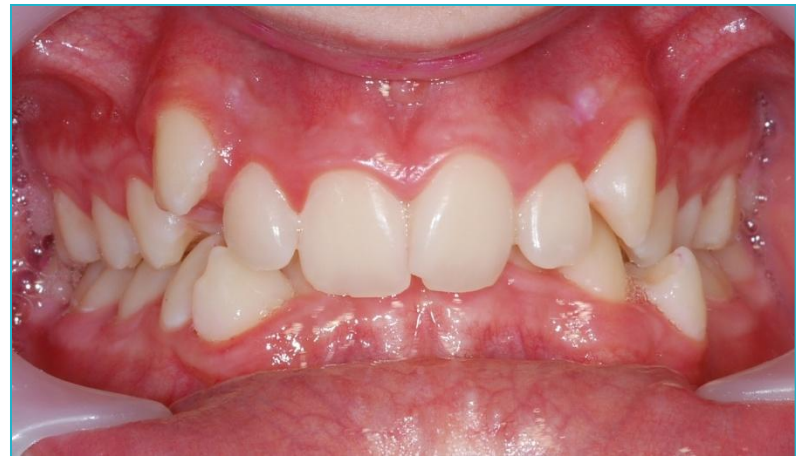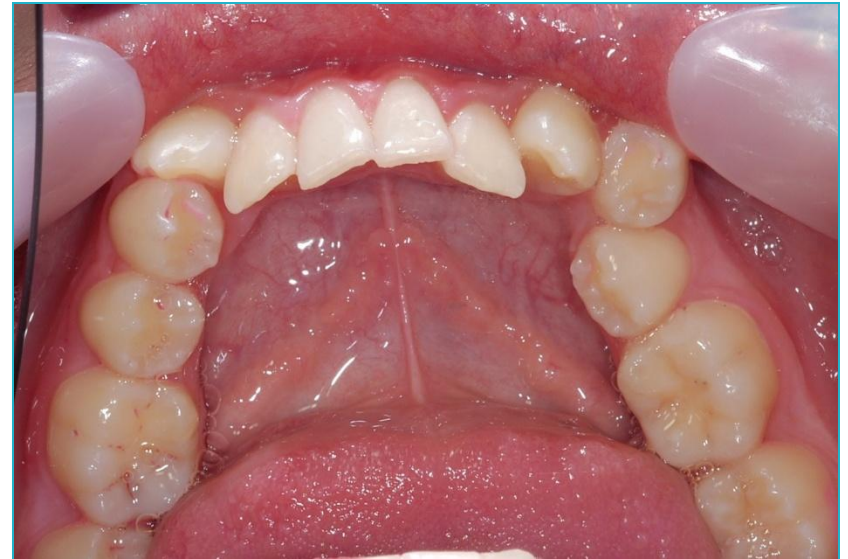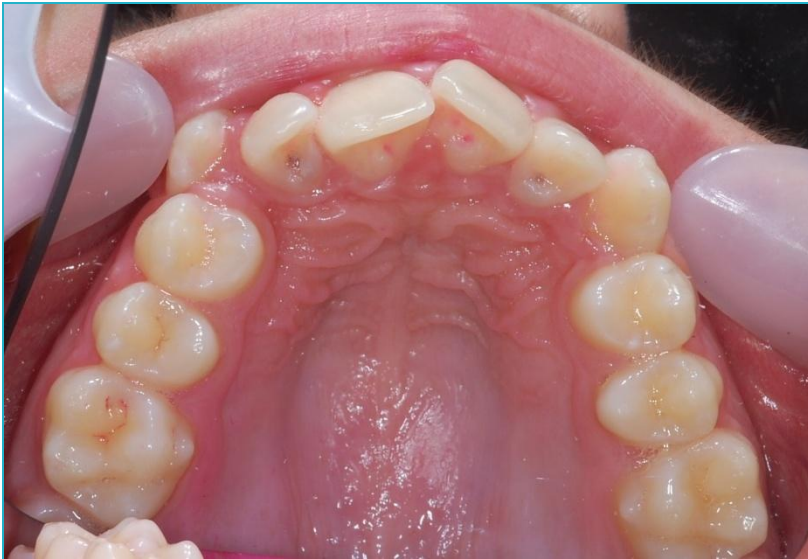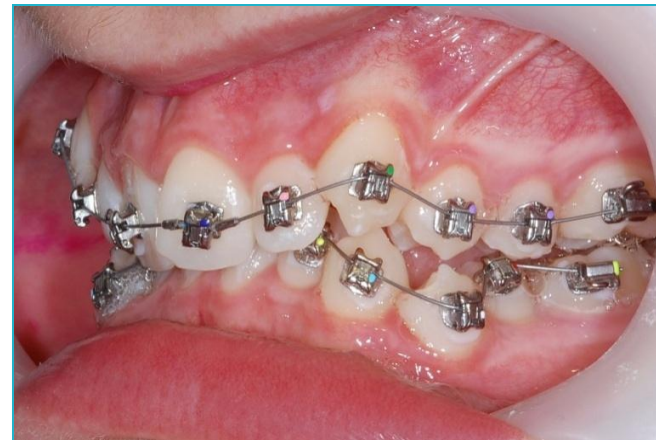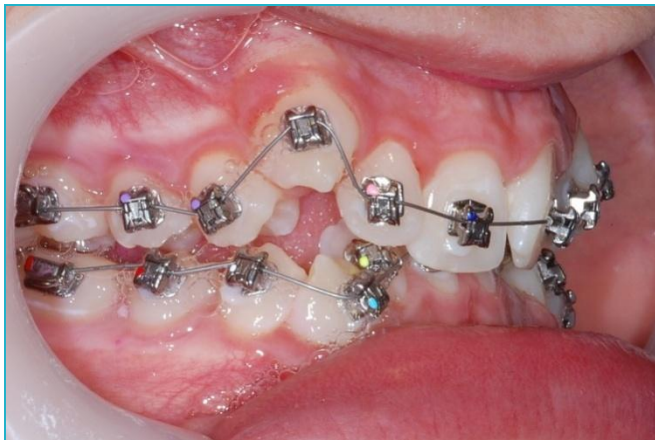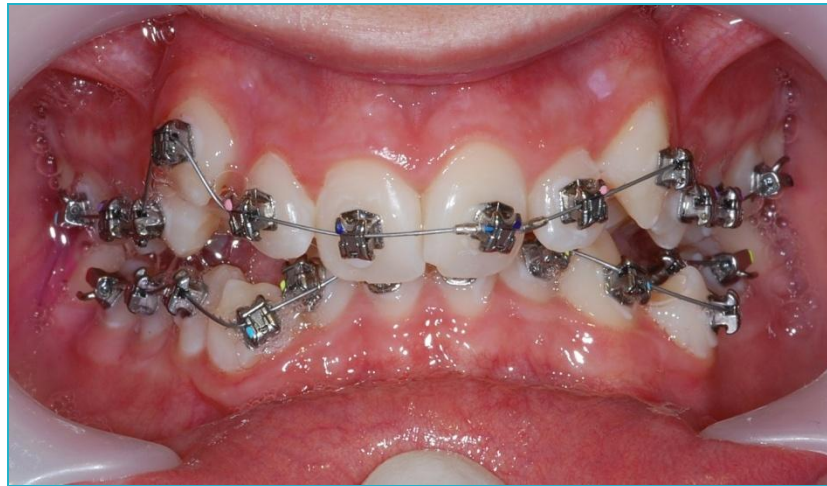
Joseph presented at 13 years of age, concerned about his irregular front teeth



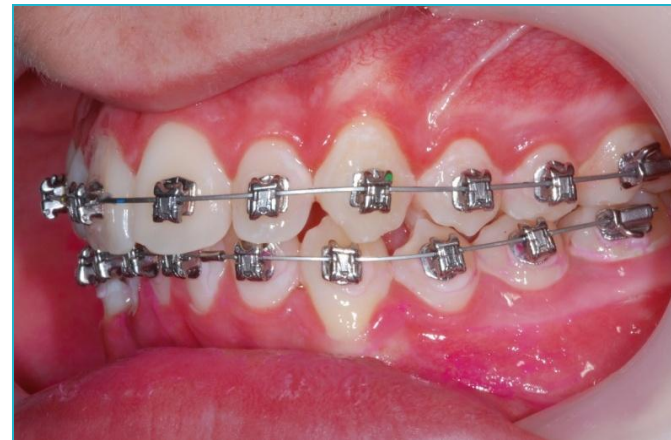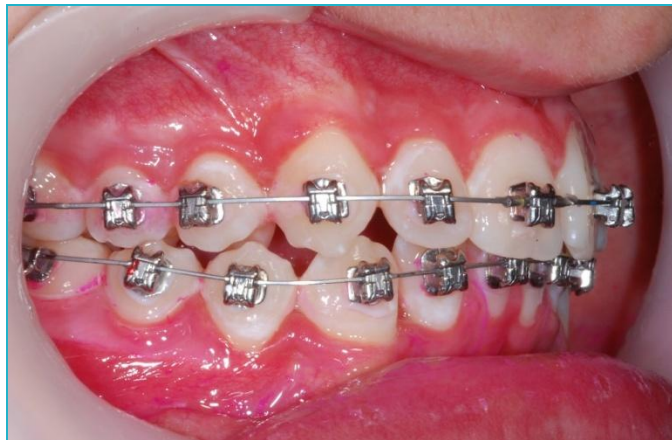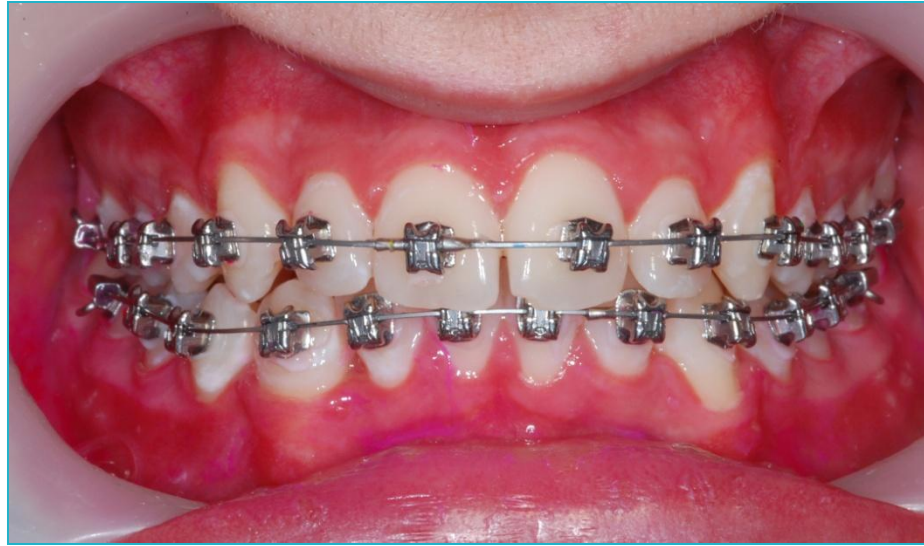Upper and lower anterior teeth were very crowded



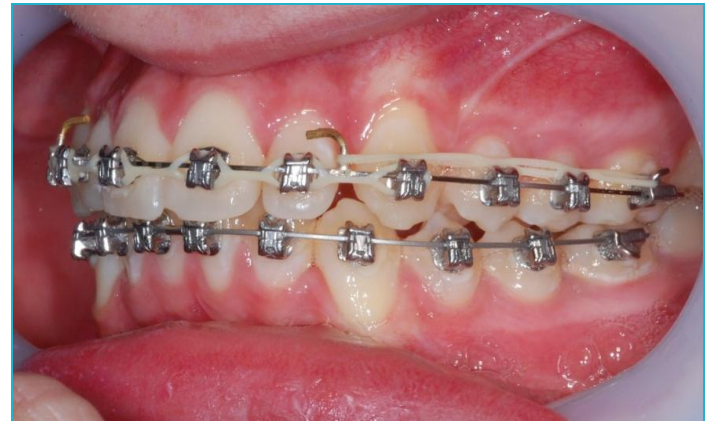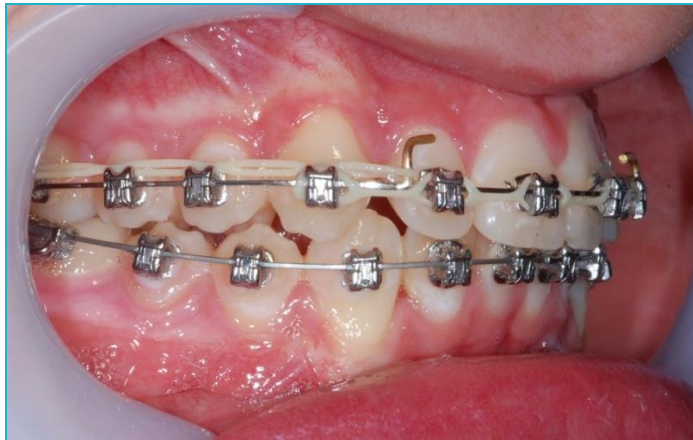
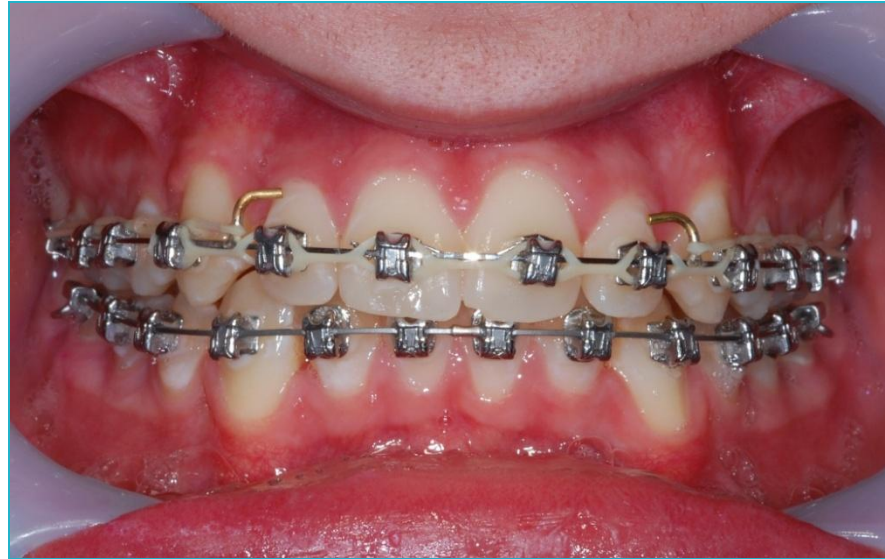Dr Horobin used the Damon 3MX Brace, without extractions.



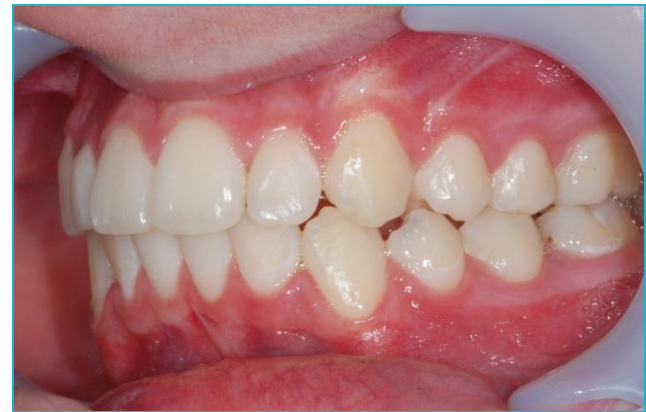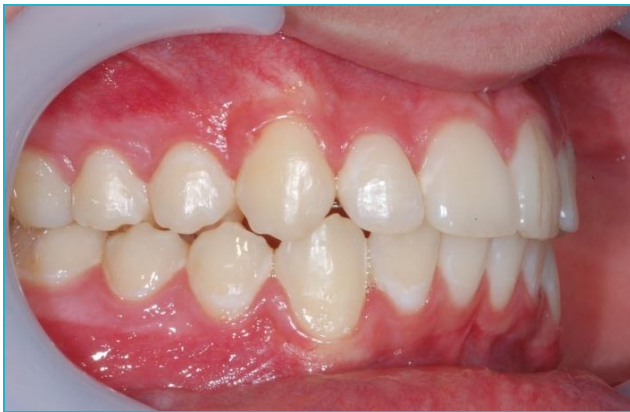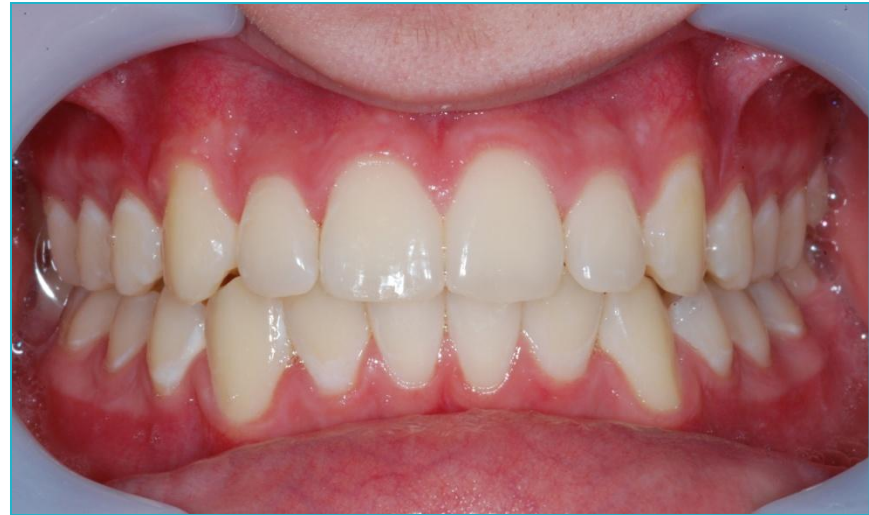Progress after 11 months



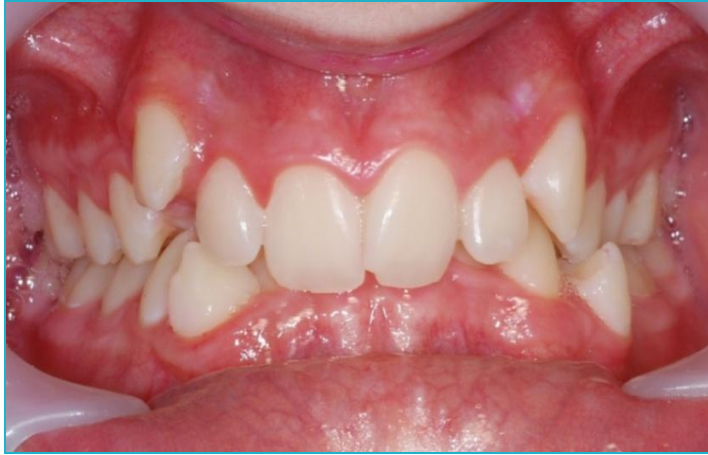Progress after 17 months



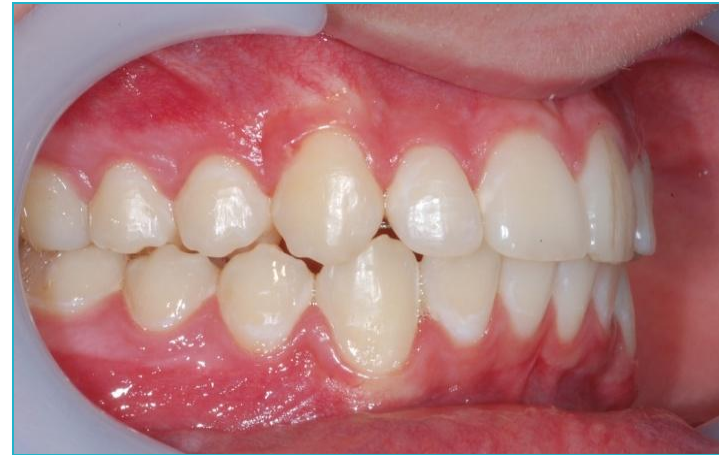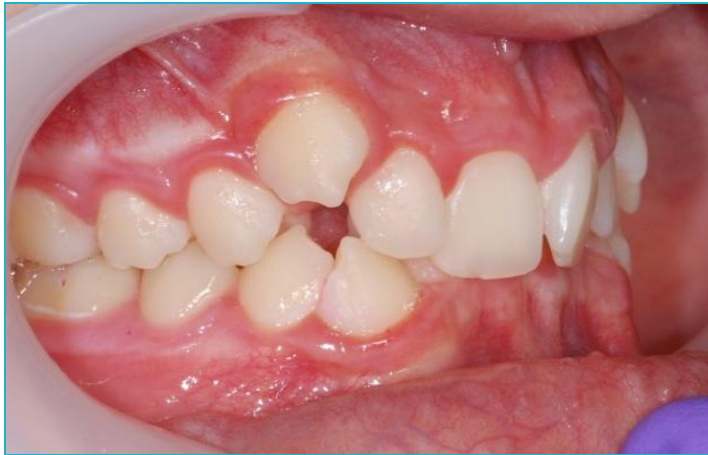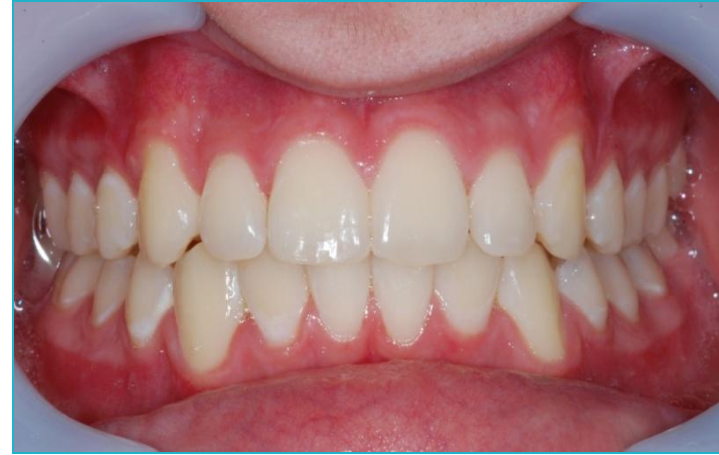Finished Result after 22 months



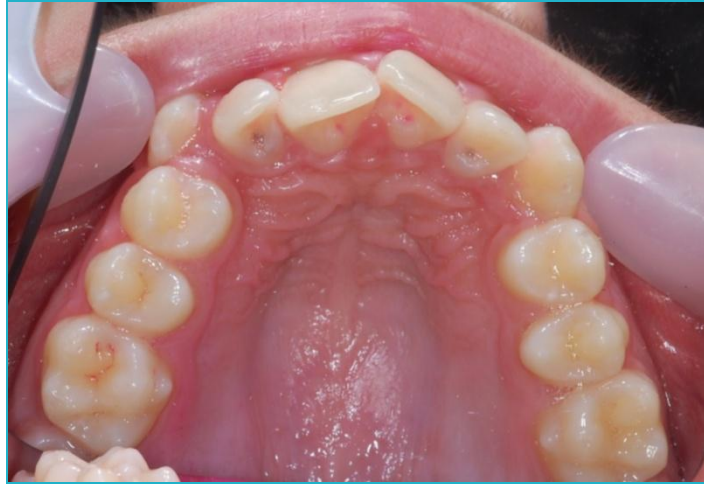Before



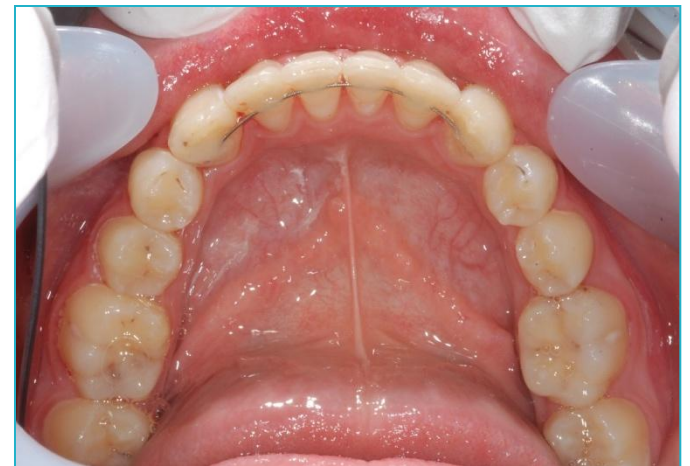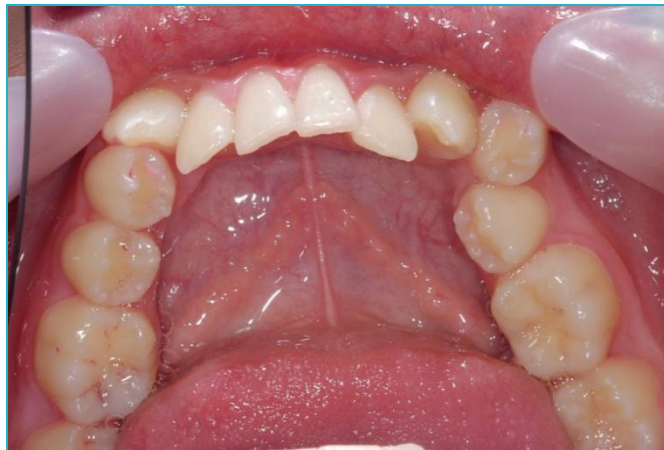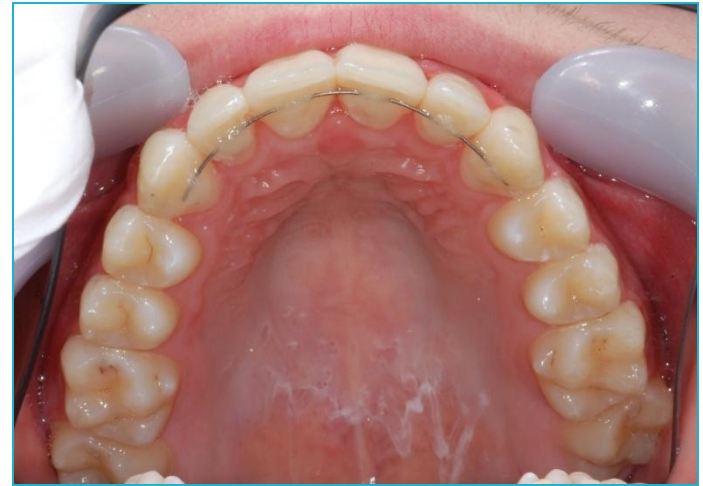After



Before



After



Note the fixed retainers

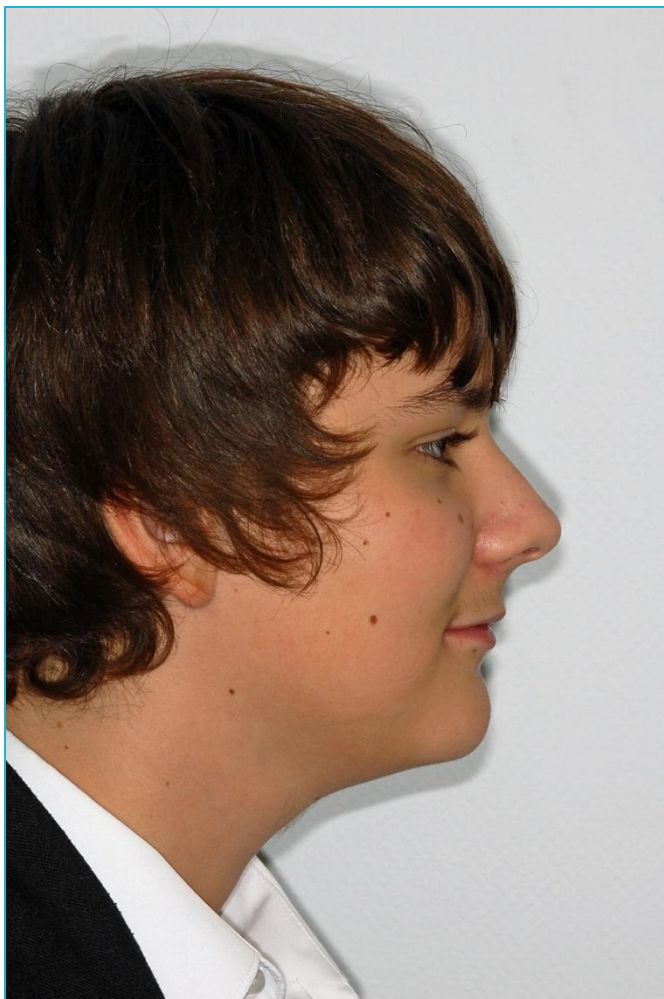
Before



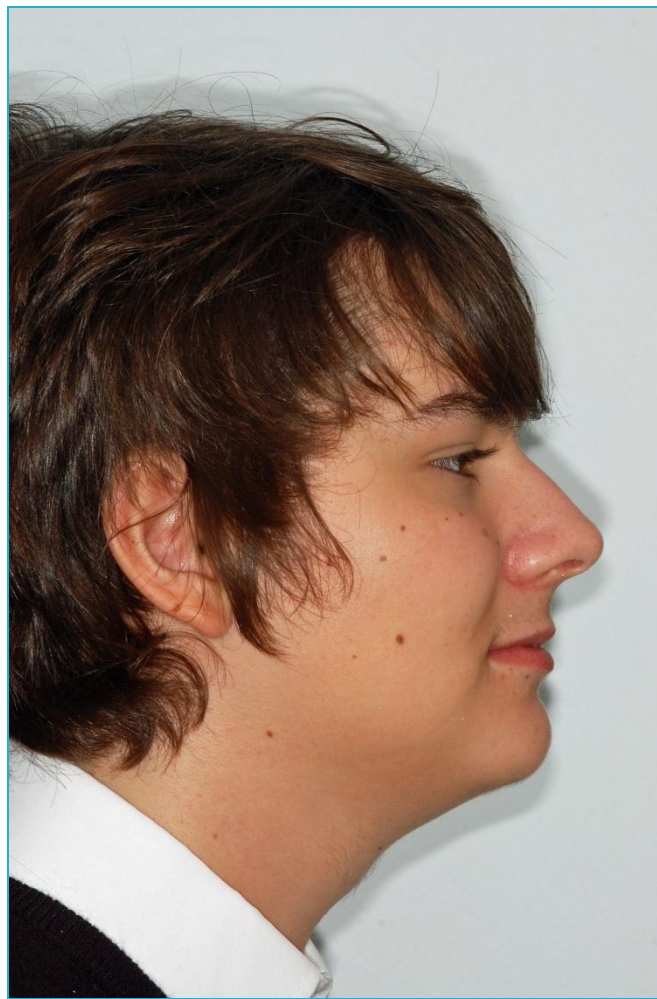After



Before

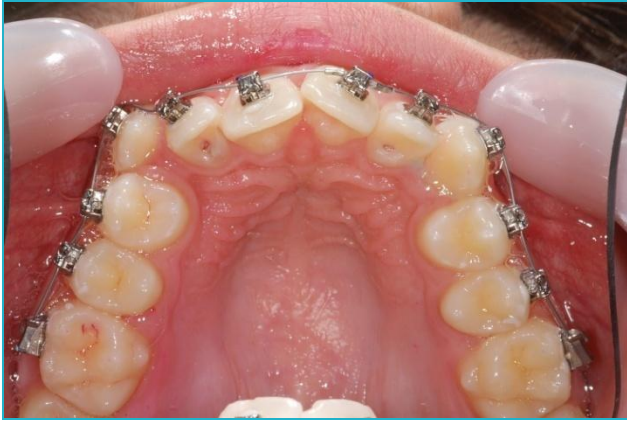

After

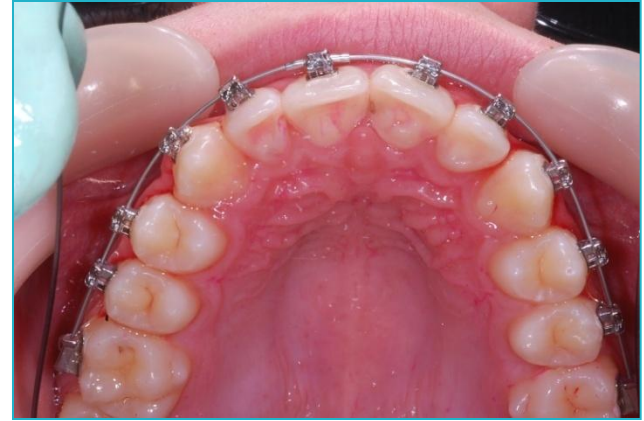

Improved profile

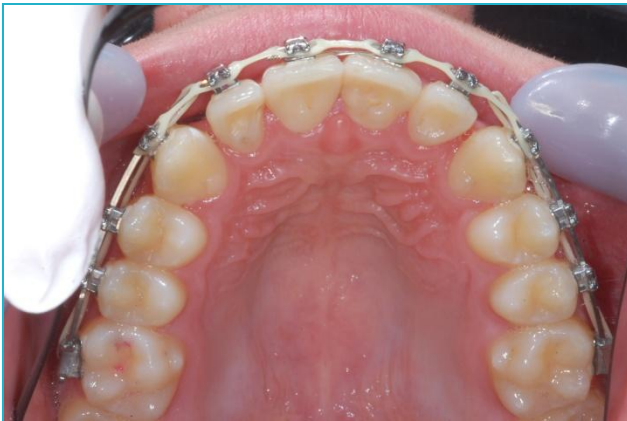Upper arch sequence



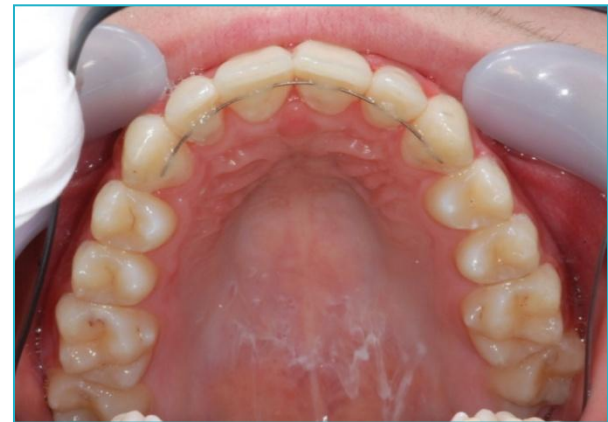1



2

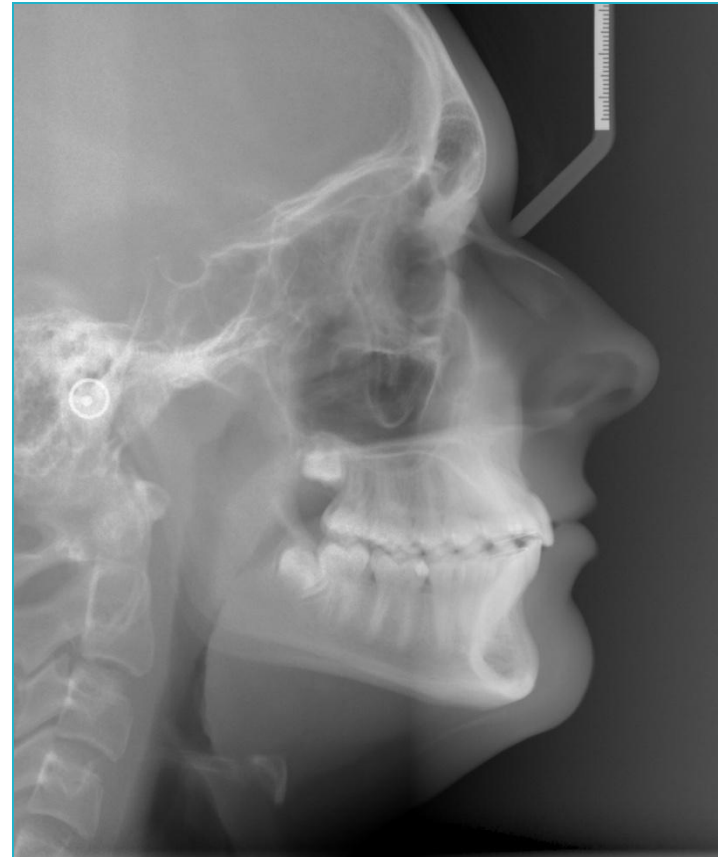
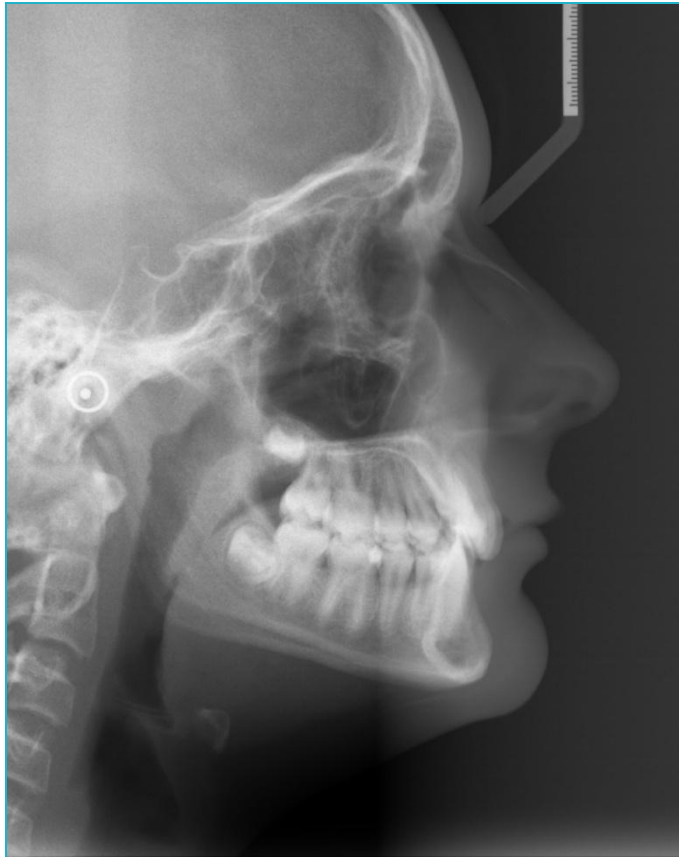
3



4

Before and after Lateral Skull Radiographs



Note the change in incisor inclination



Smile Created By



Confidence in your smile