



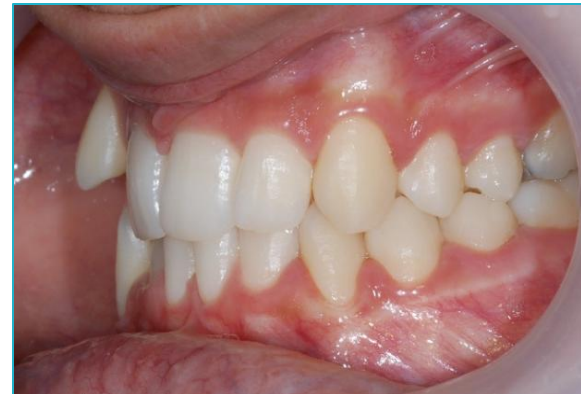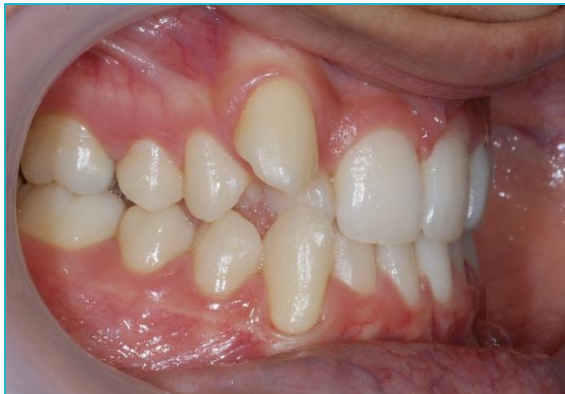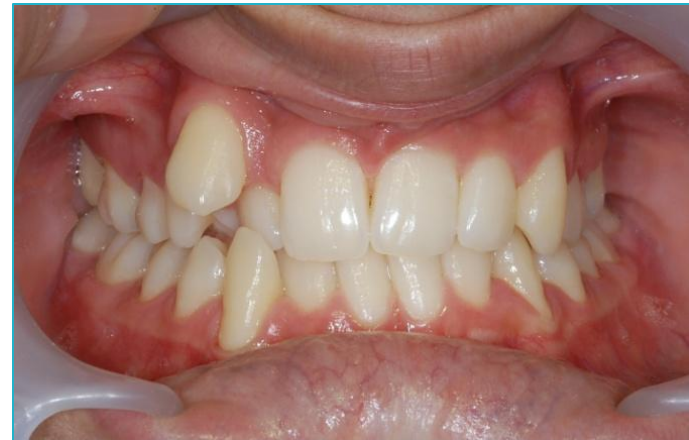Confidence in your smile

presents

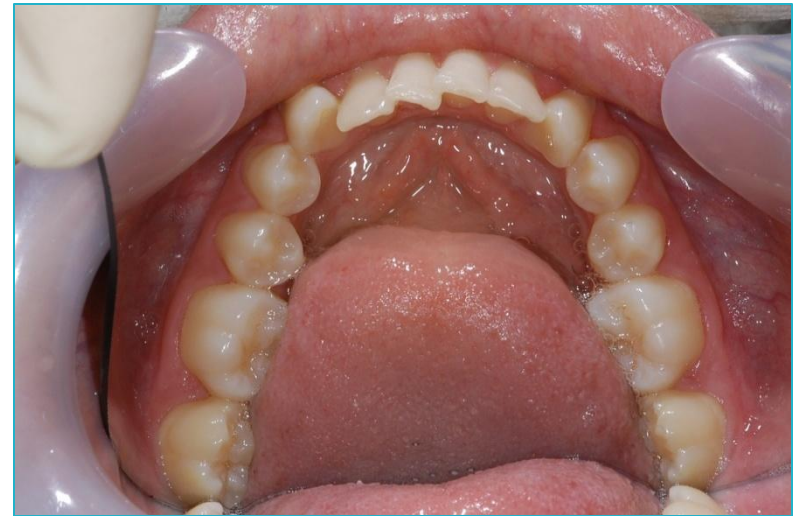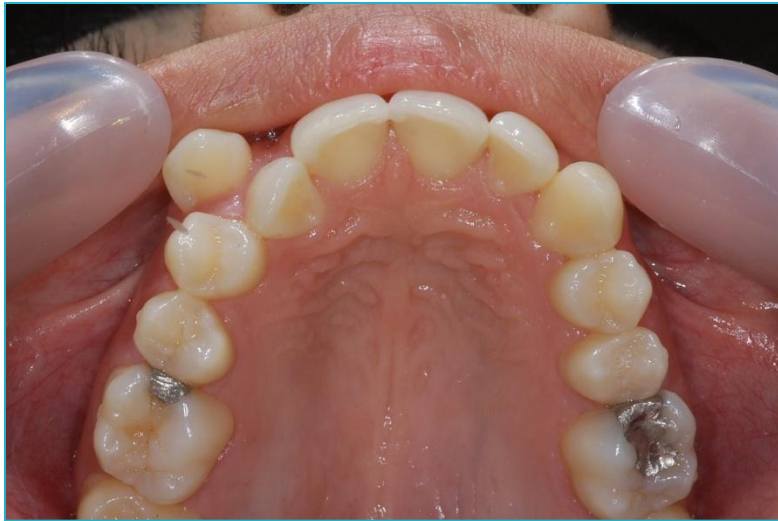DAMON[®]3 *MX*

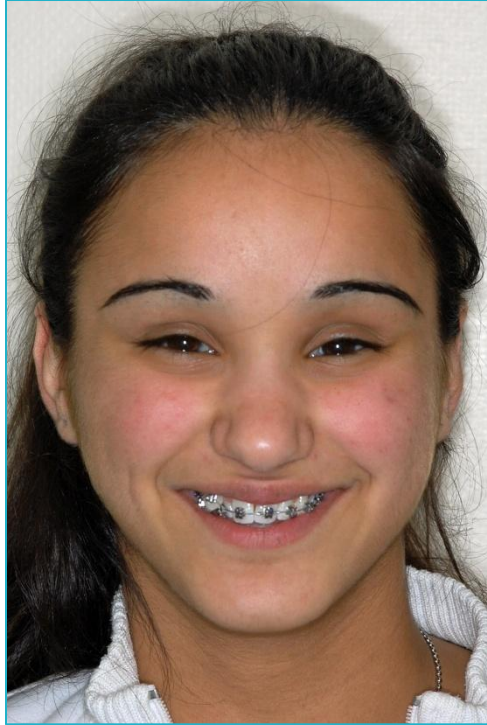


At 14 years, Harminder was concerned about her crowded teeth.

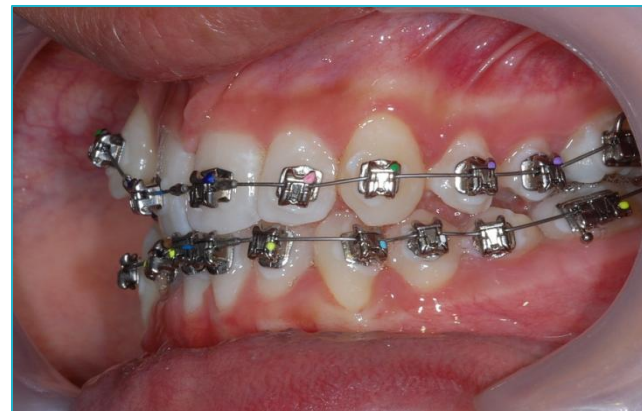
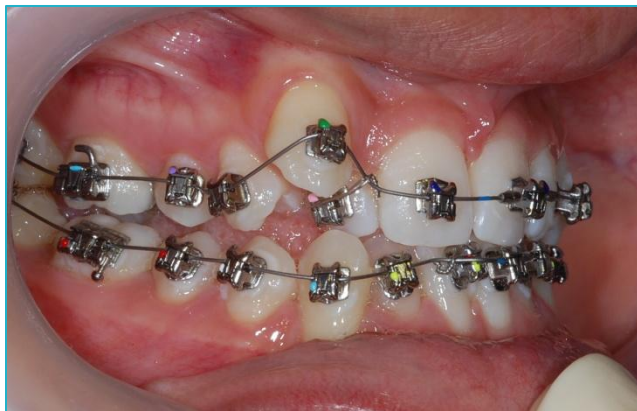
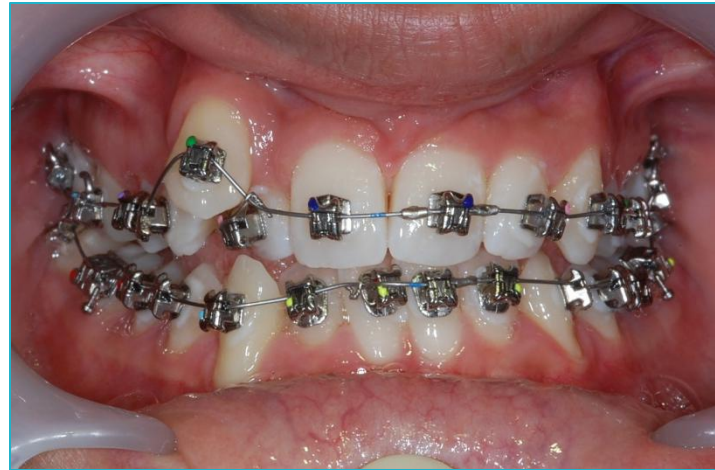Severe crowding with an upper canine blocked out of the arch

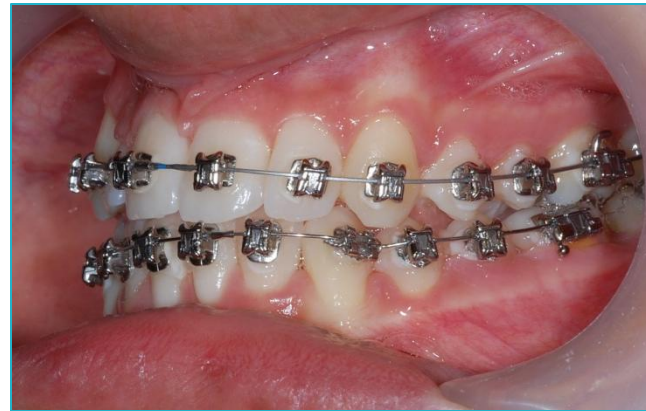
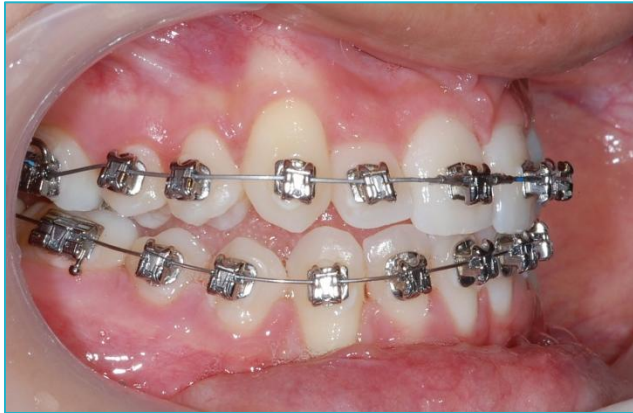
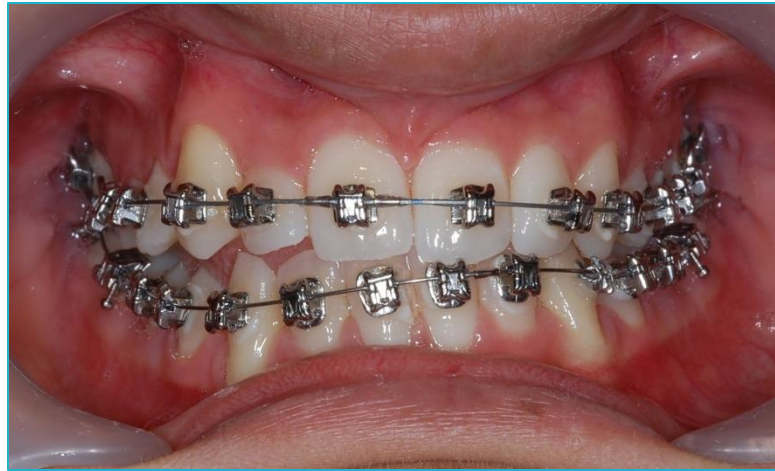

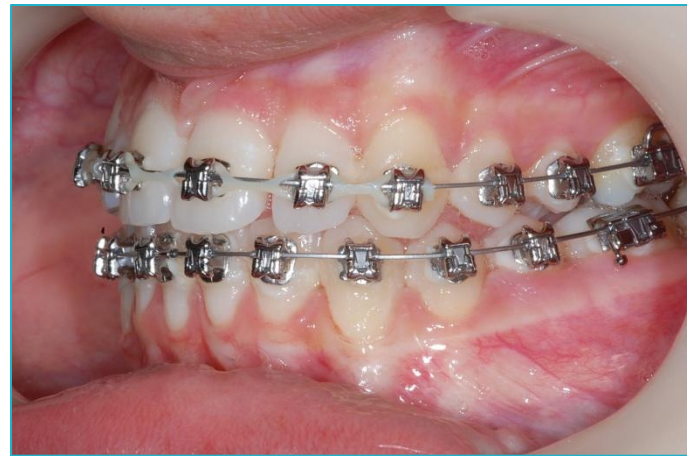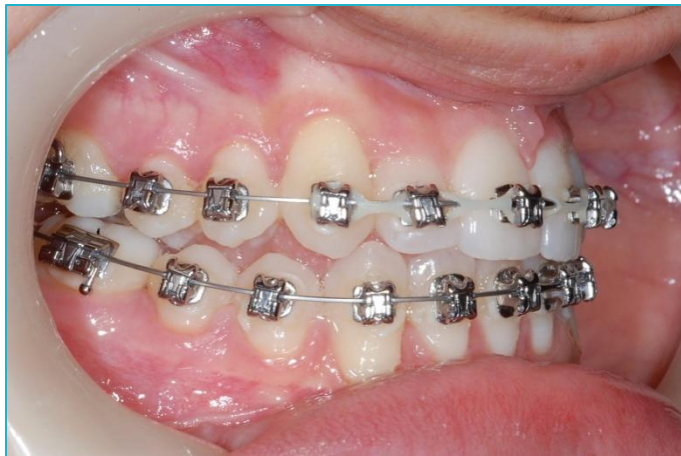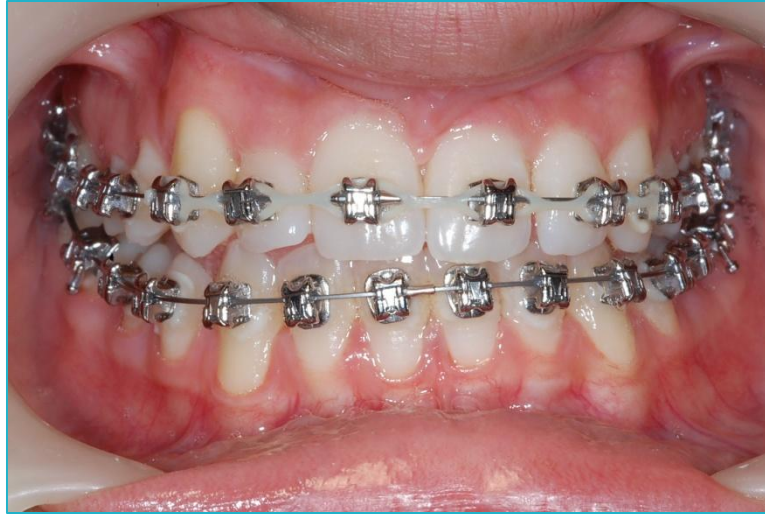**Dr Horobin used the Damon 3MX brace
without extractions.**



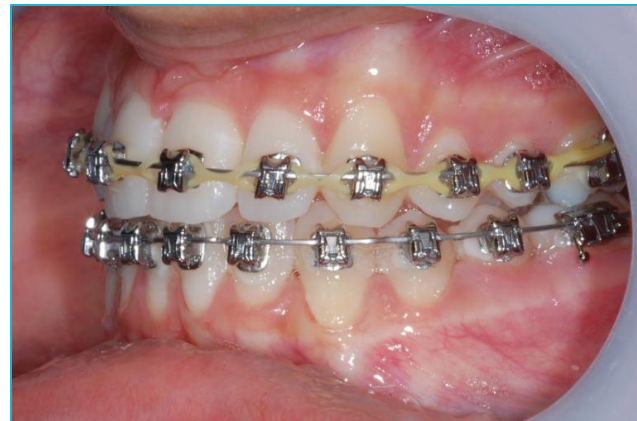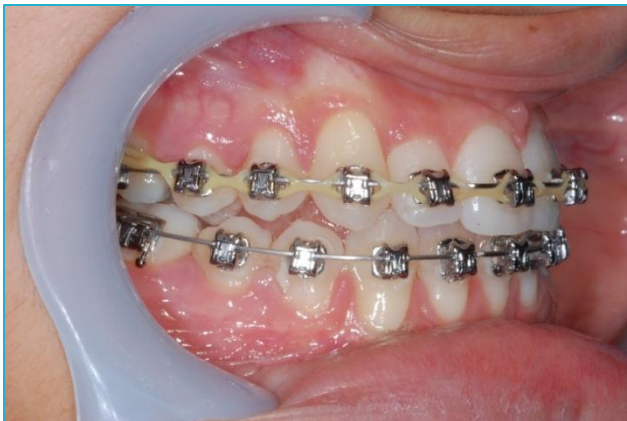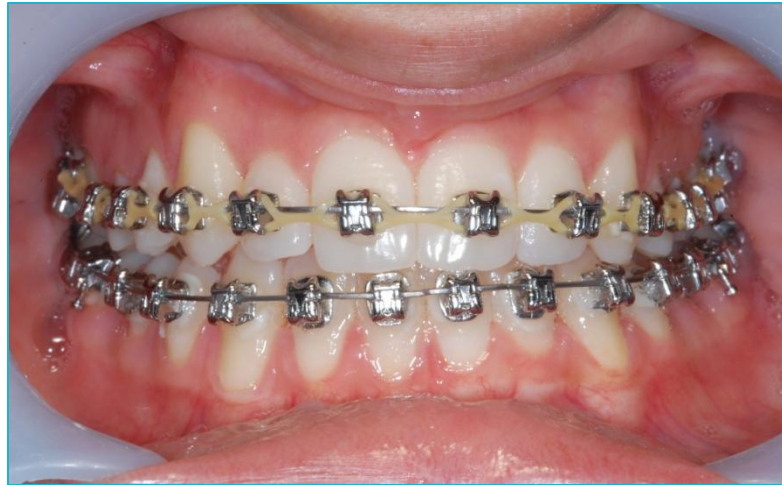Progress after 5 months



Progress after 11 months

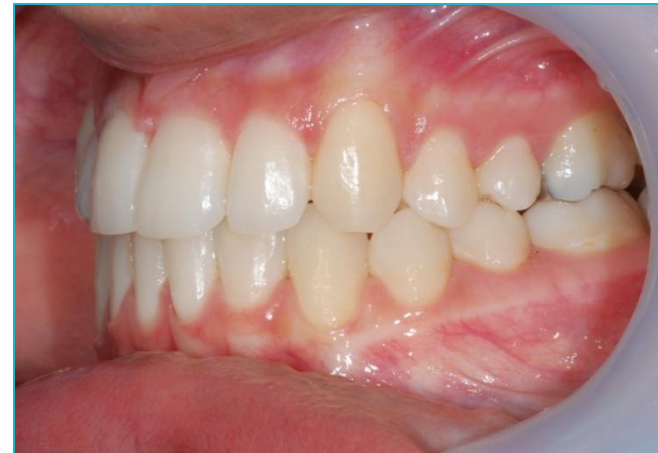
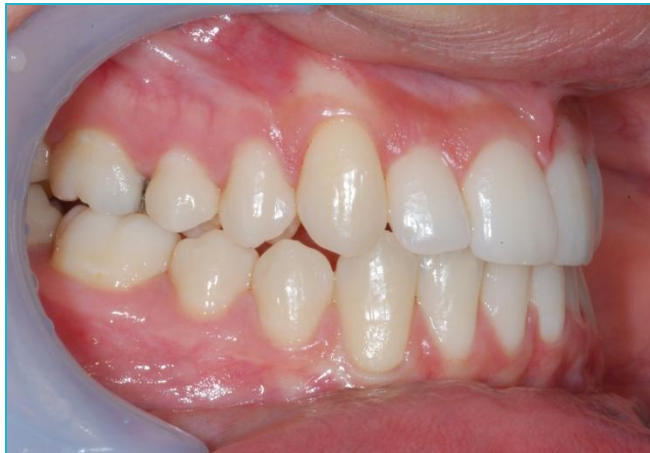
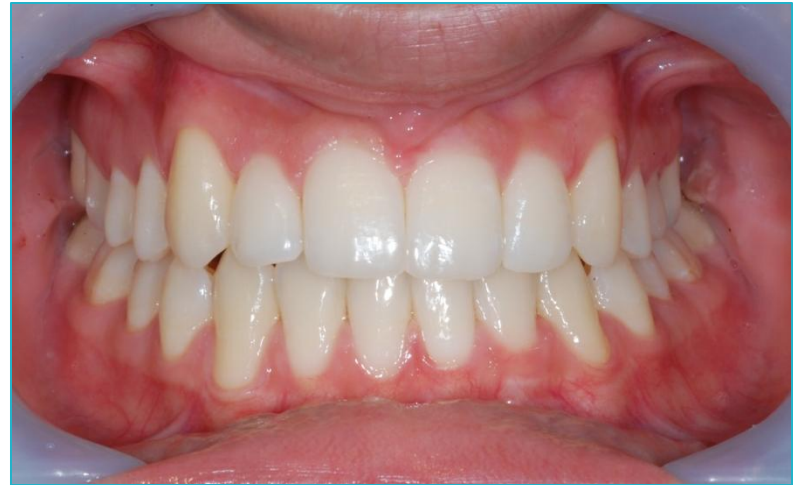Progress after 19 months

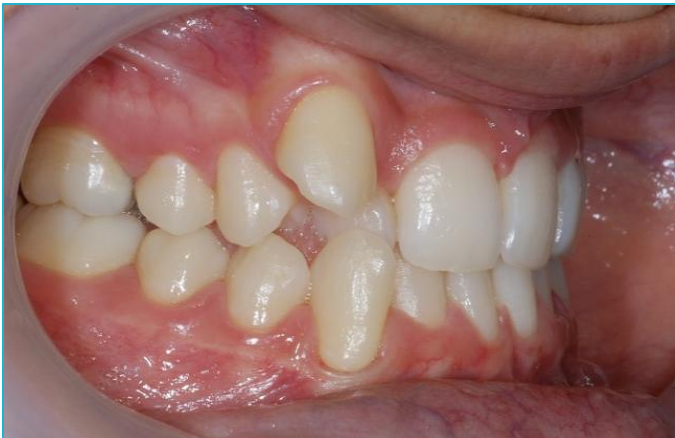
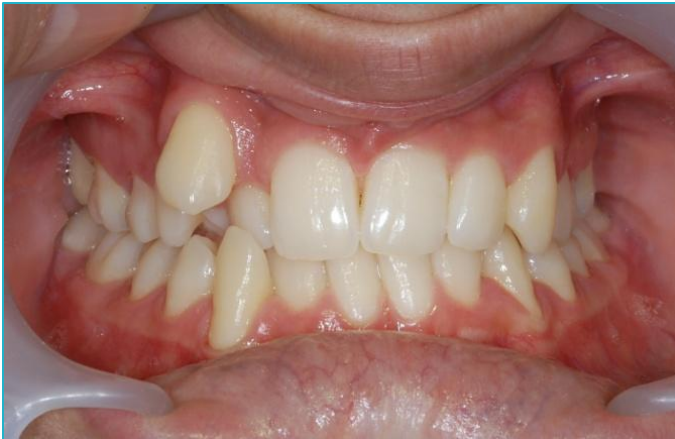


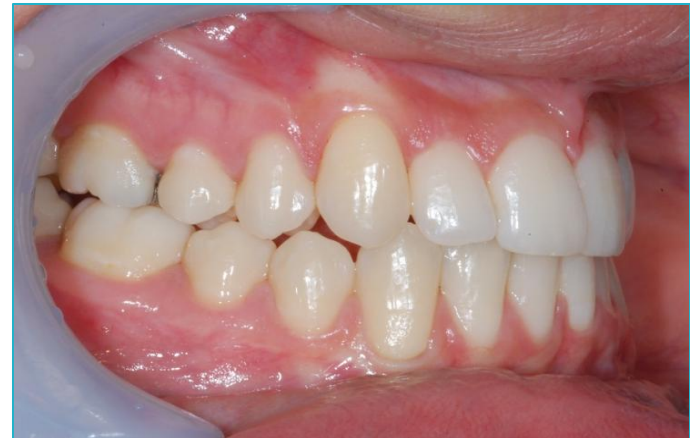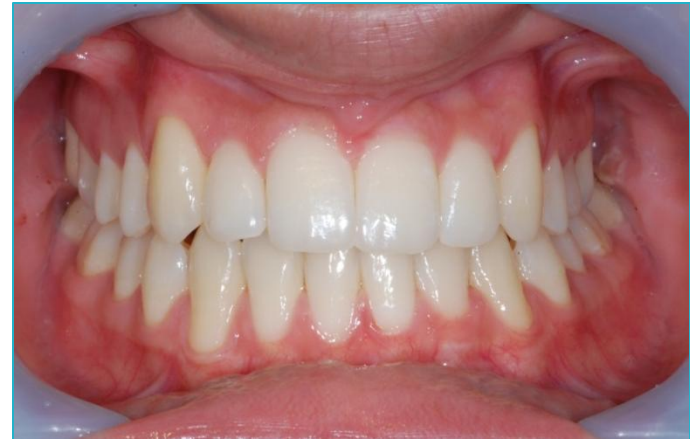**Finished Result
after 17 months**



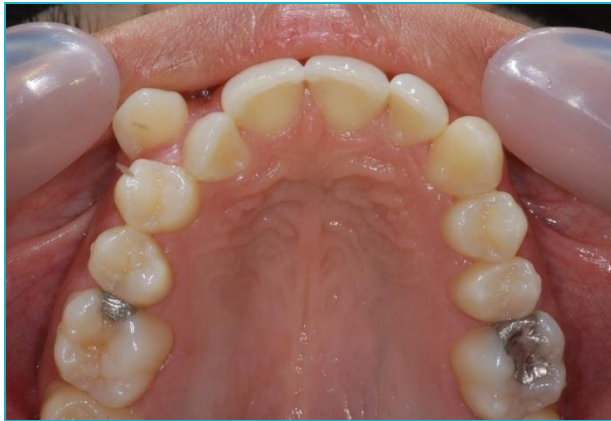Before



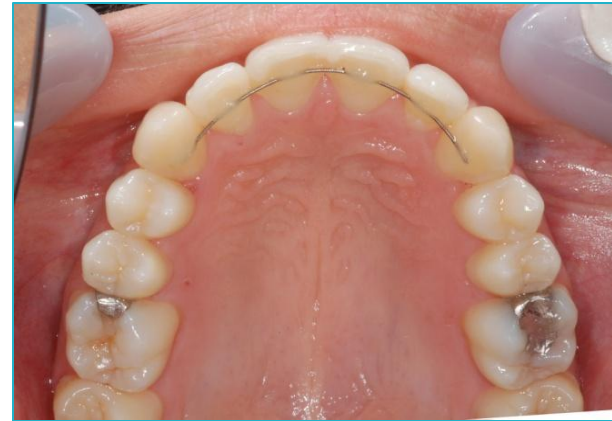After



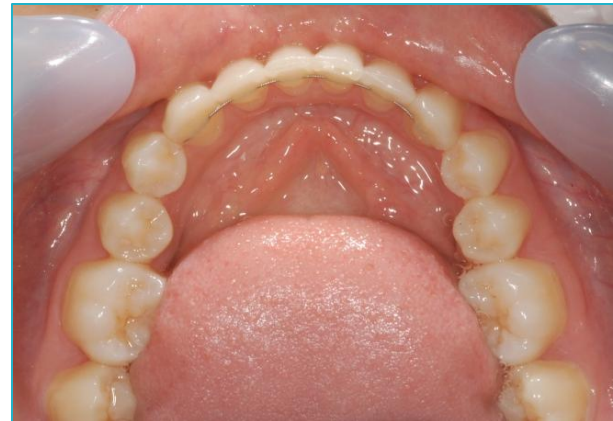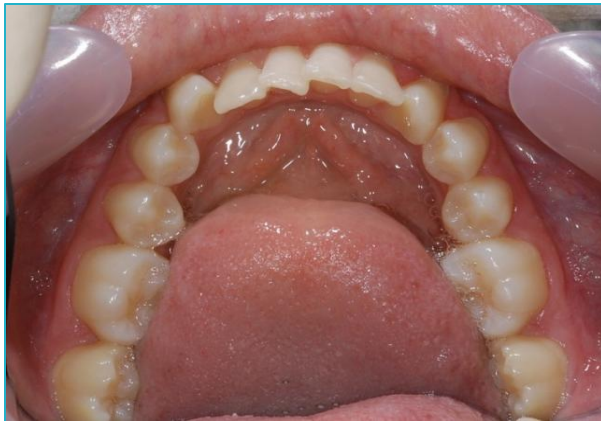Before



After



Note the fixed retainers



17 months treatment, without extractions

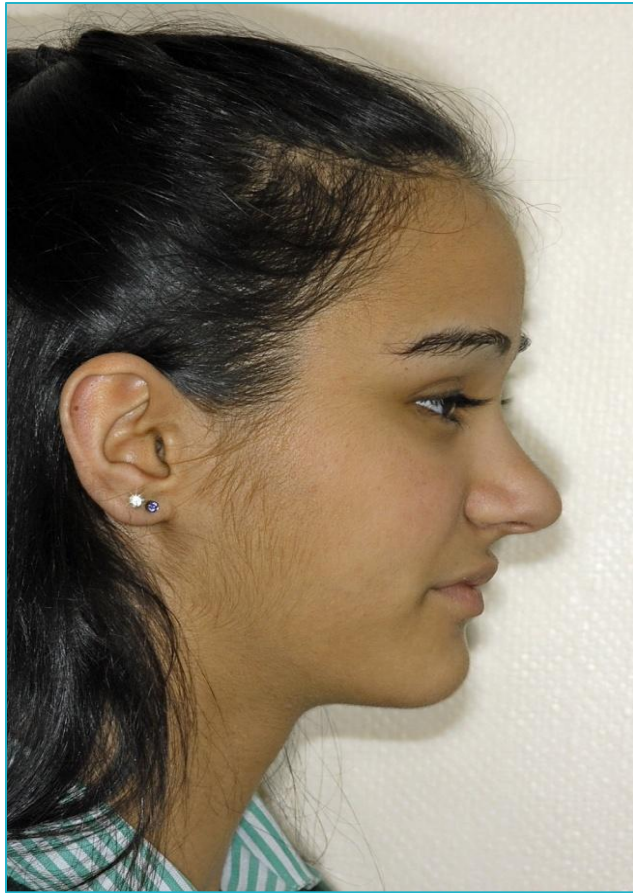Before



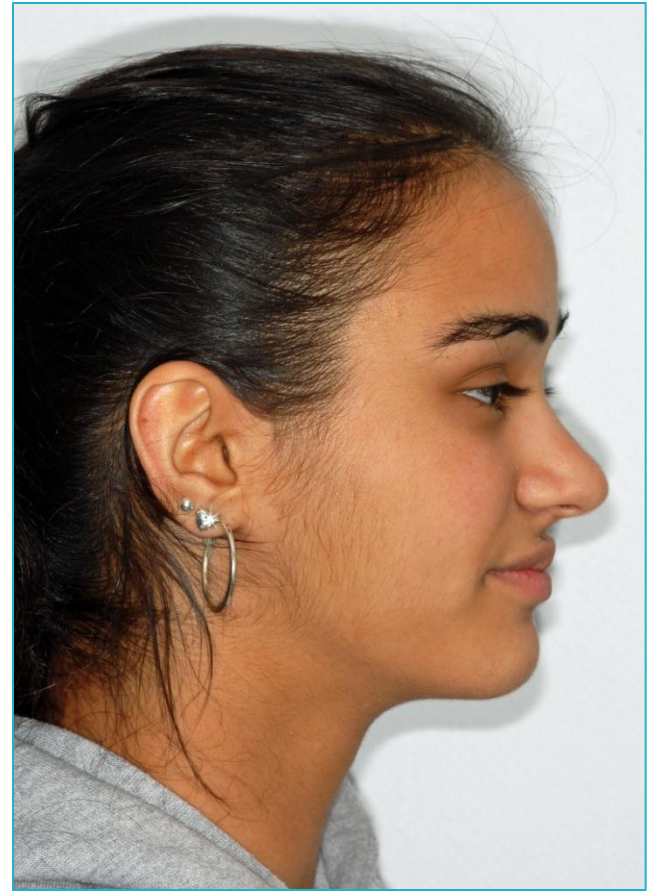
After



Before

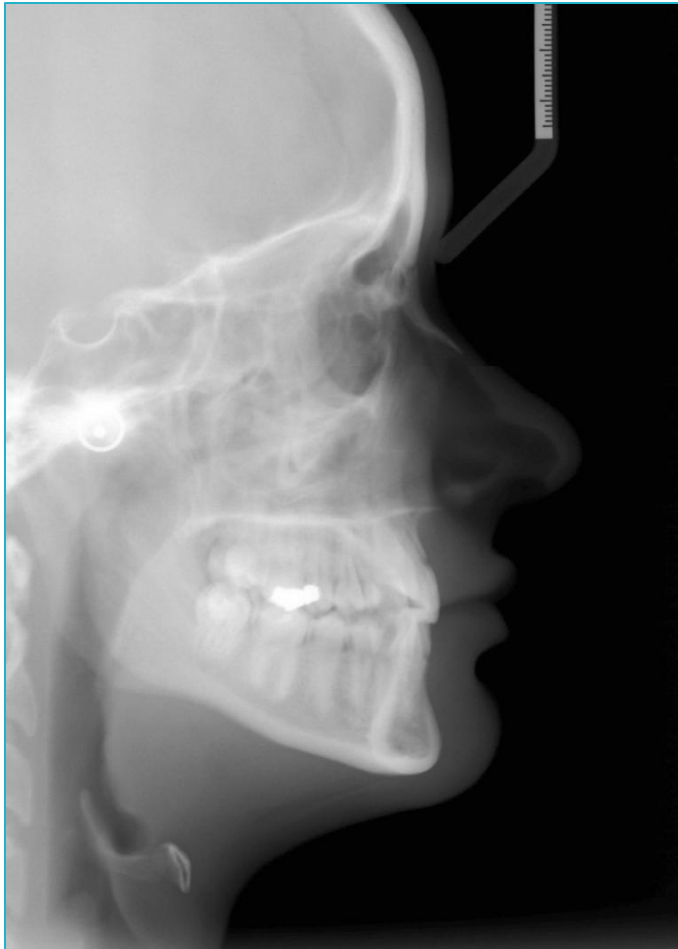

After

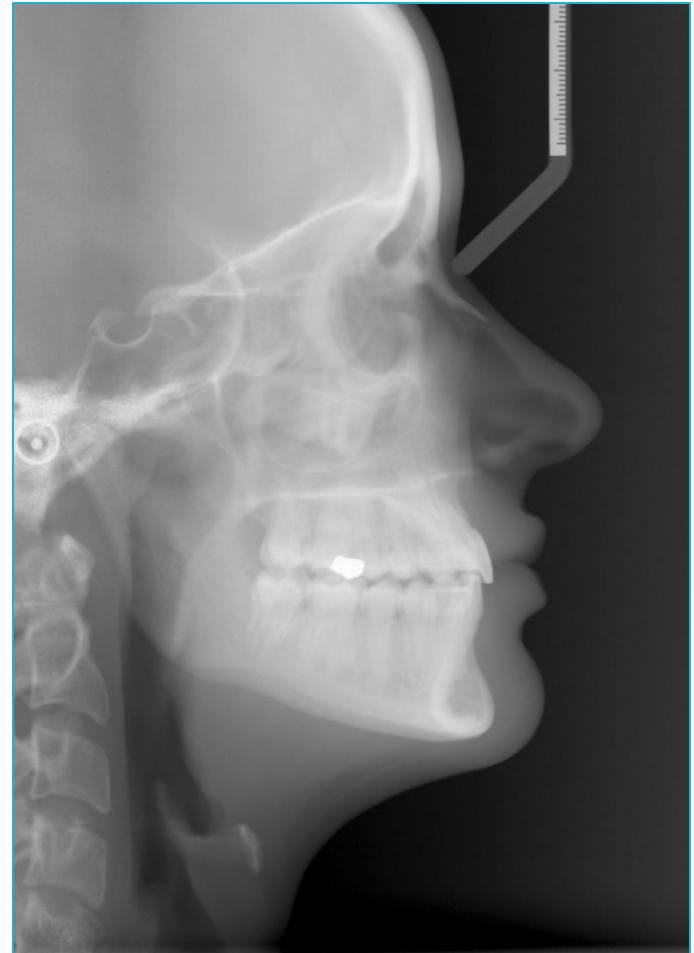


Facial Profile

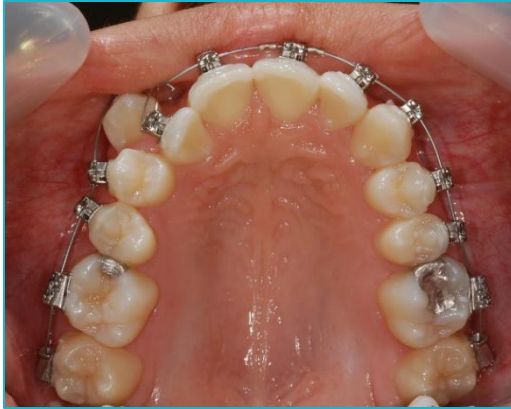Before



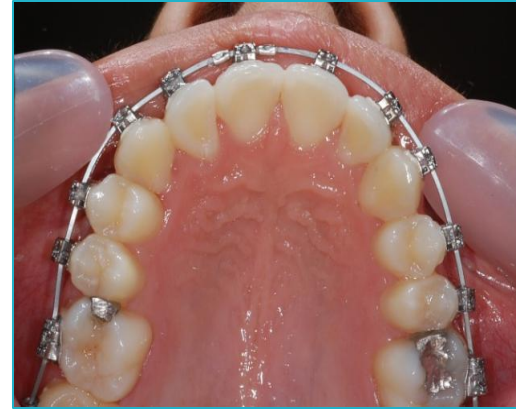After



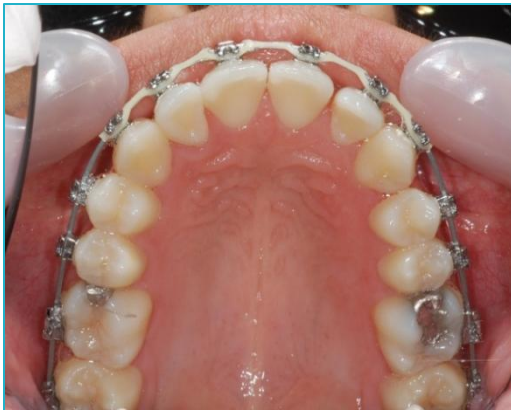Upper arch sequence



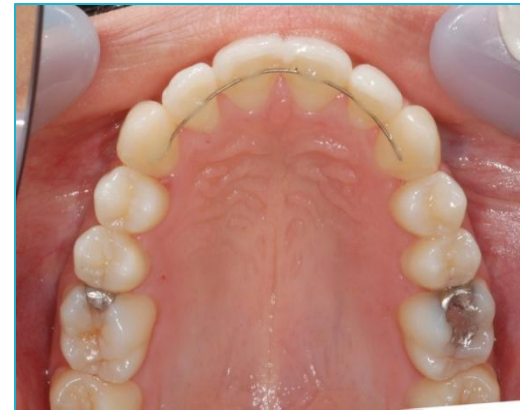1



2



3



4

Before



After



Smile Created by



Confidence in your smile