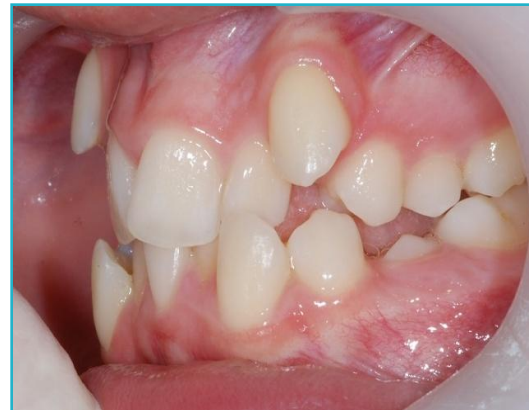
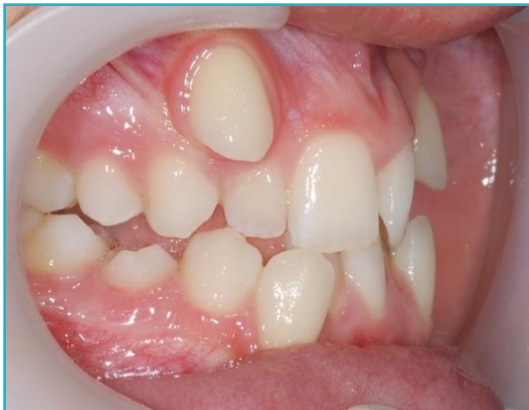
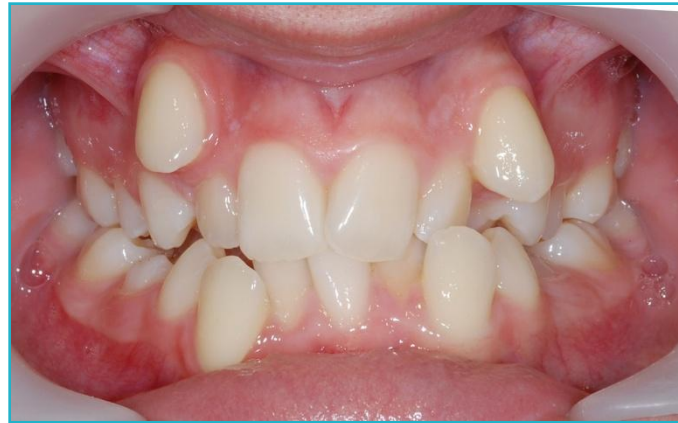
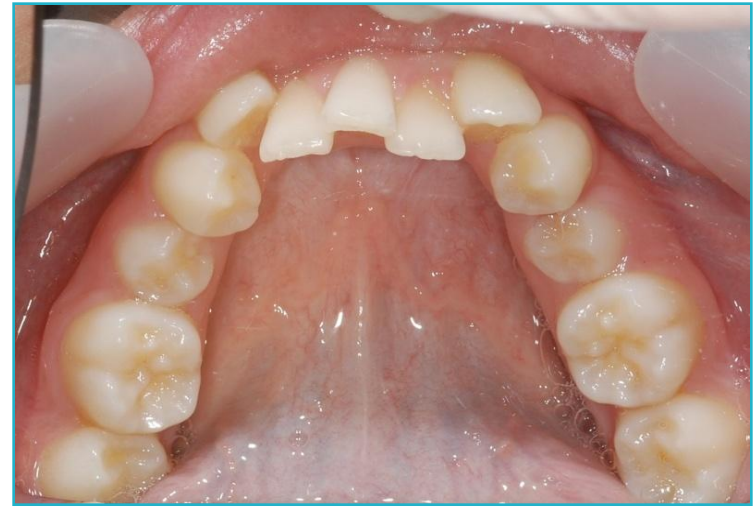
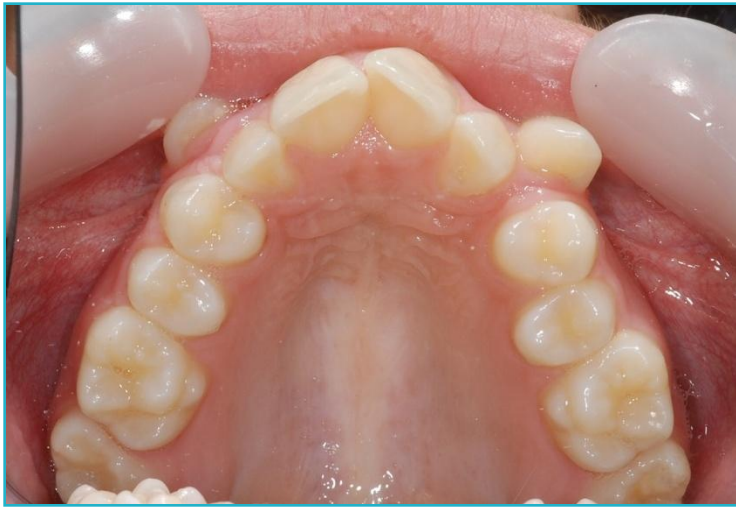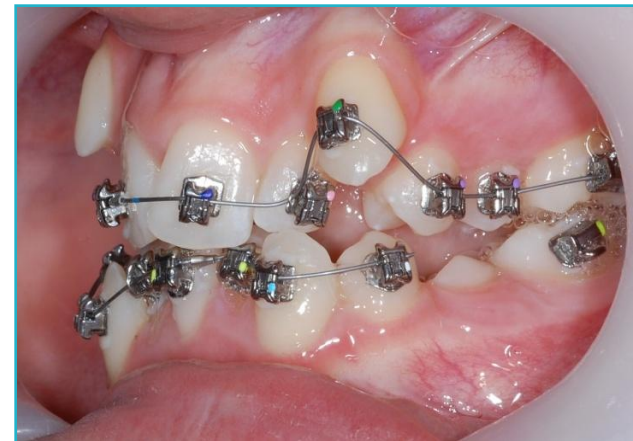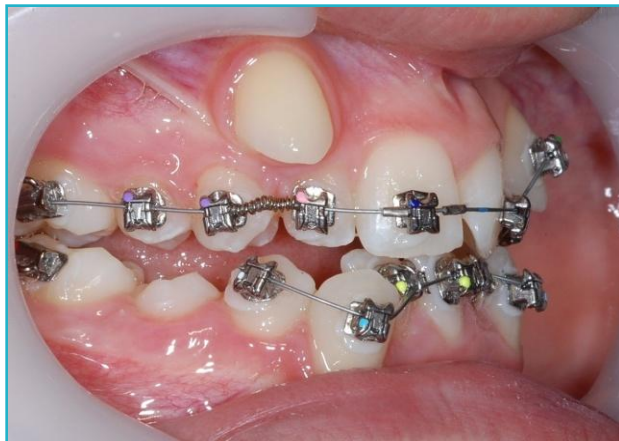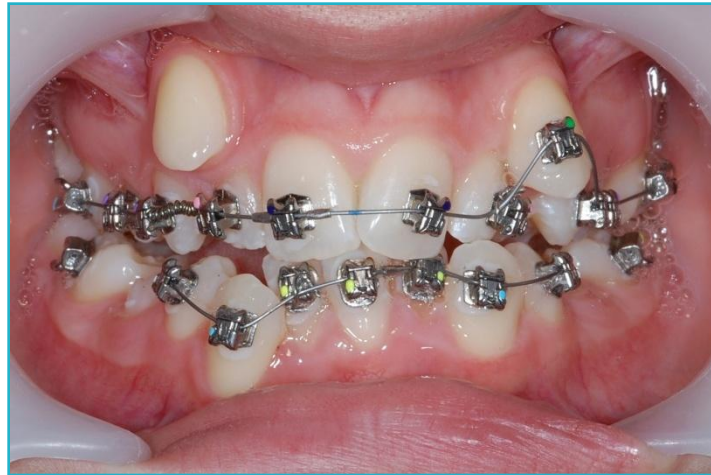**At 13 Emilia was concerned about  
her very crowded front teeth**



**A lower incisor was missing and the upper canines were  
outlocked**

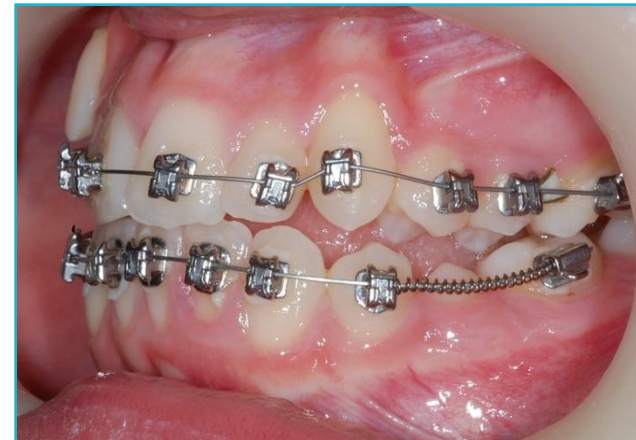
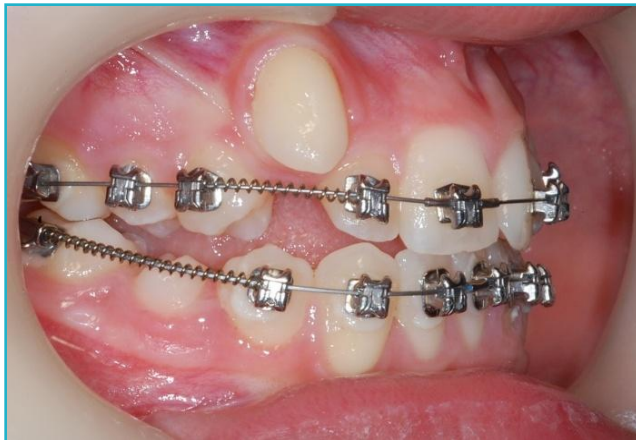
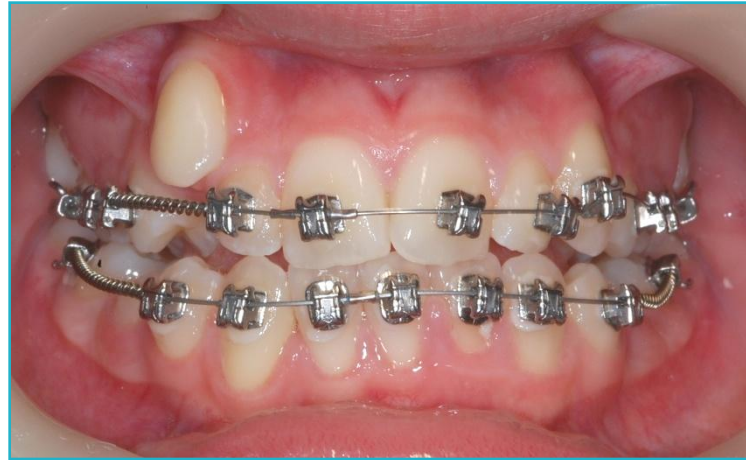## Treatment commenced with the Damon 3mx Brace

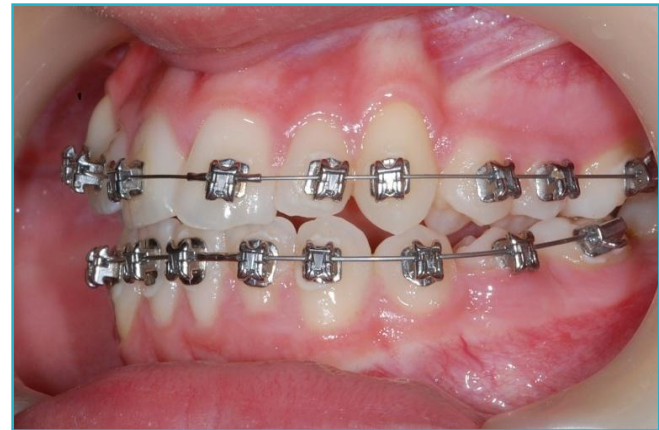
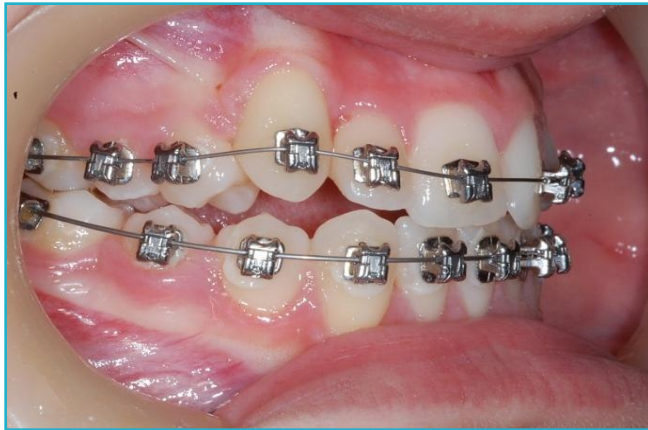
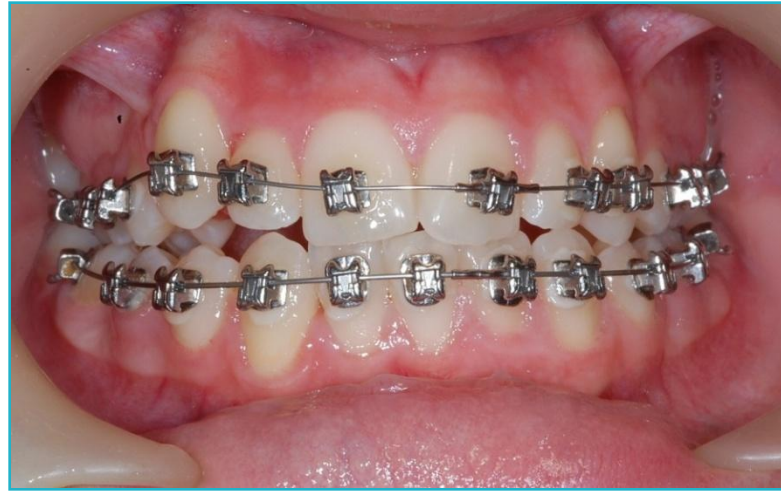

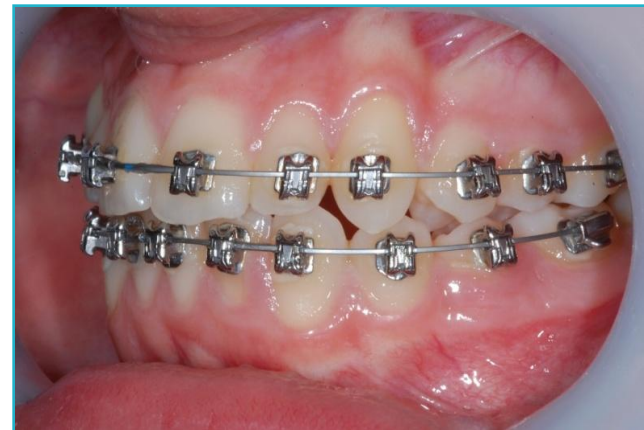
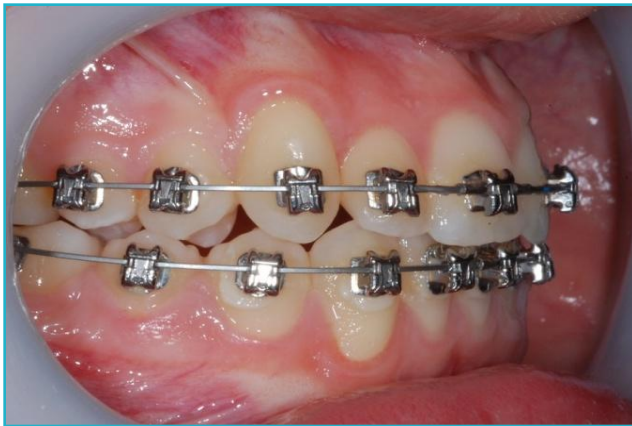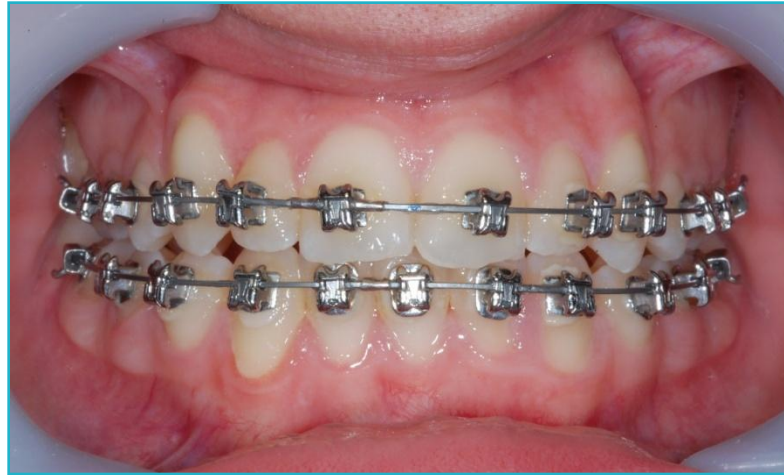## Progress after 4 months



## Progress after 8 months



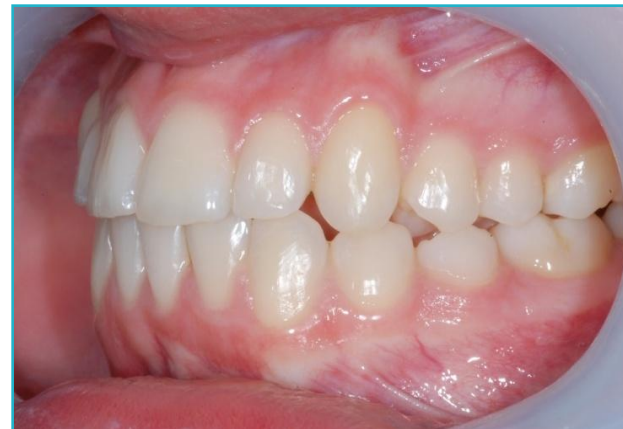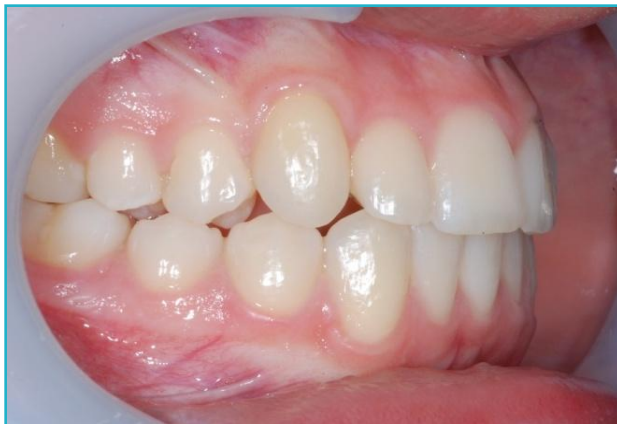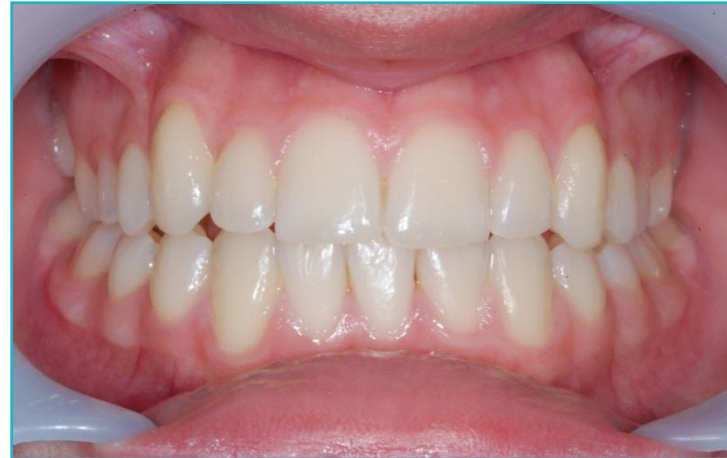## Progress after 17 months



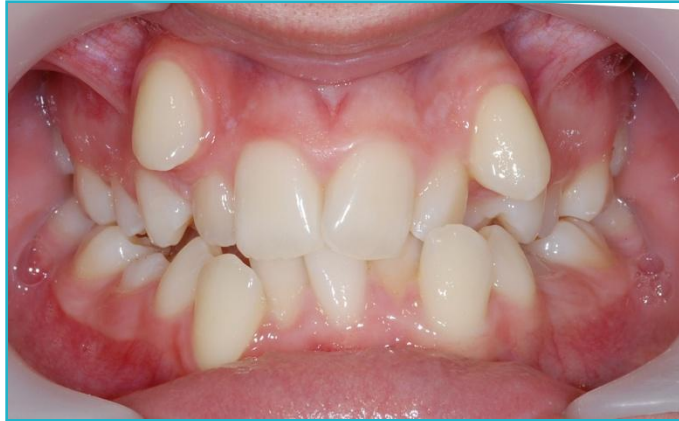



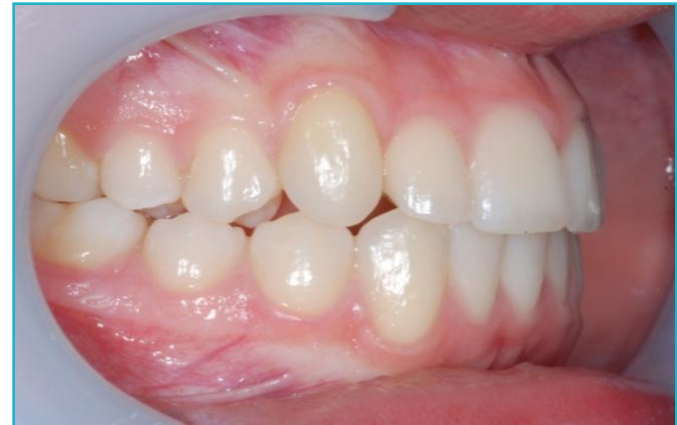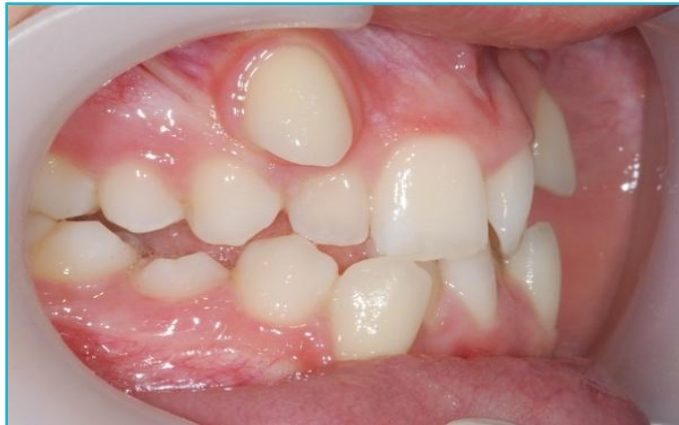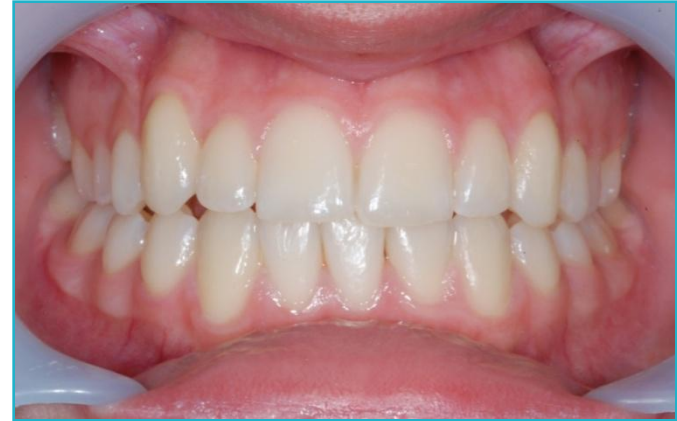**Finished Result  
after 19 months**



**Before**

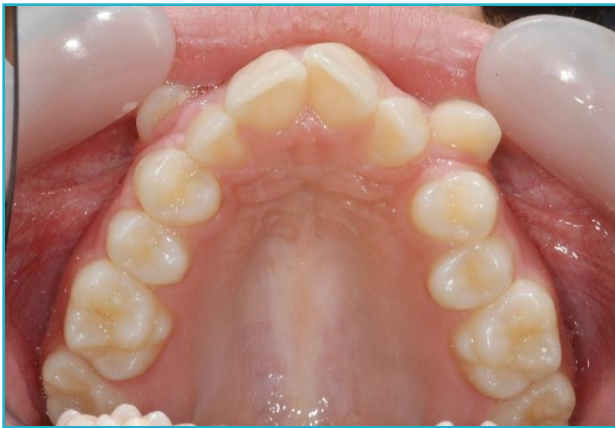

**After**

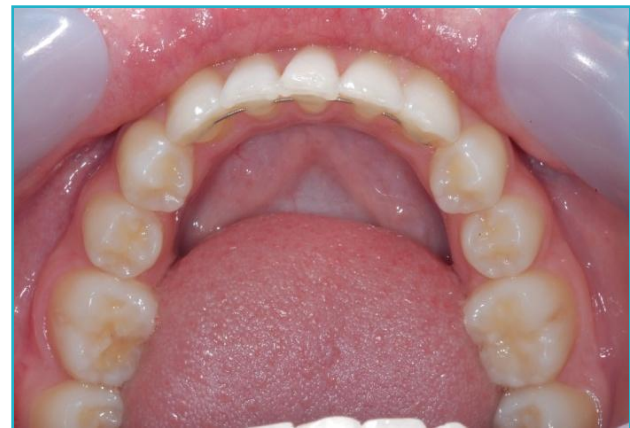
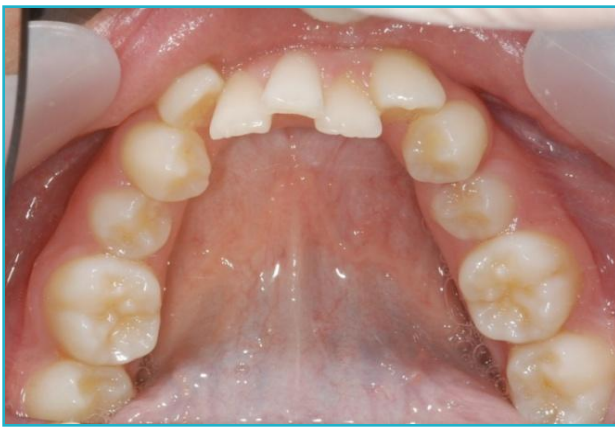
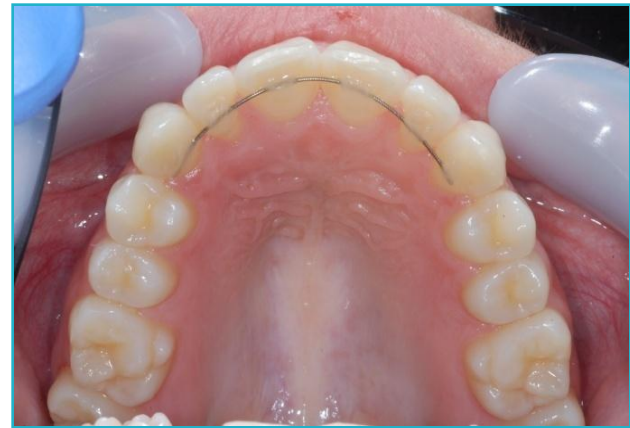

**Before**

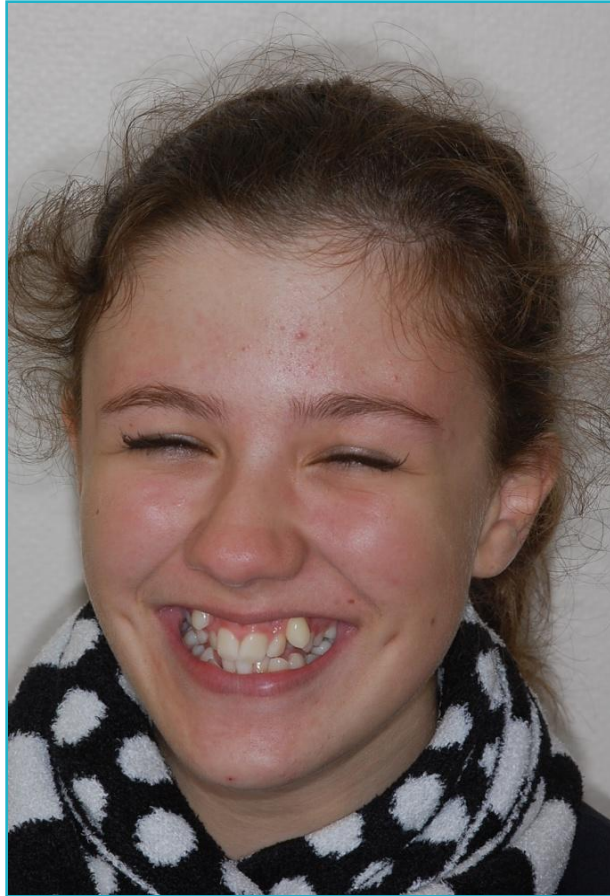


**After**



**Note fixed retainers and missing lower incisor**

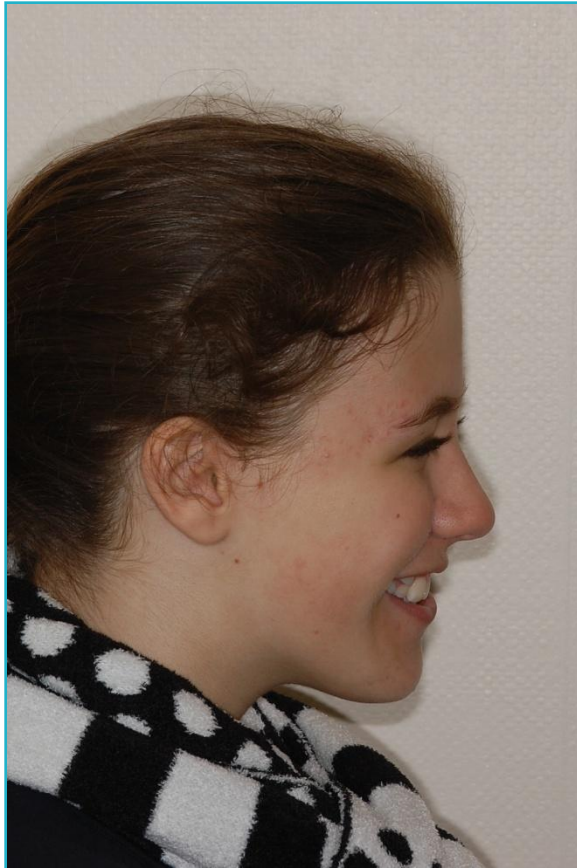**Before**



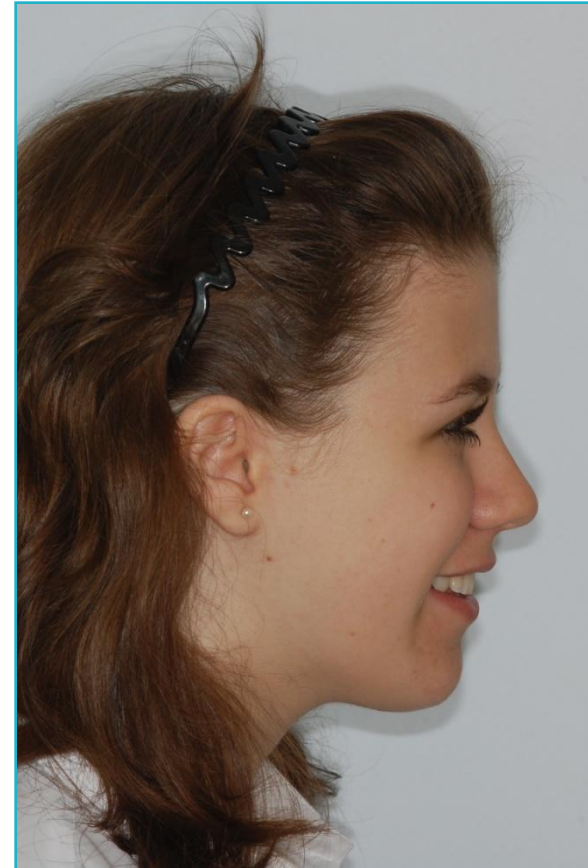**After**



**Before**

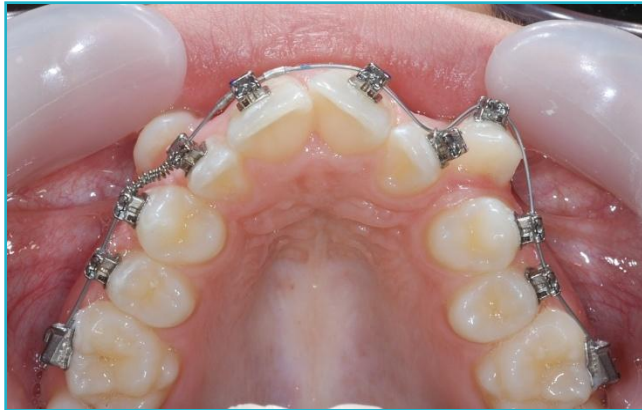

**After**

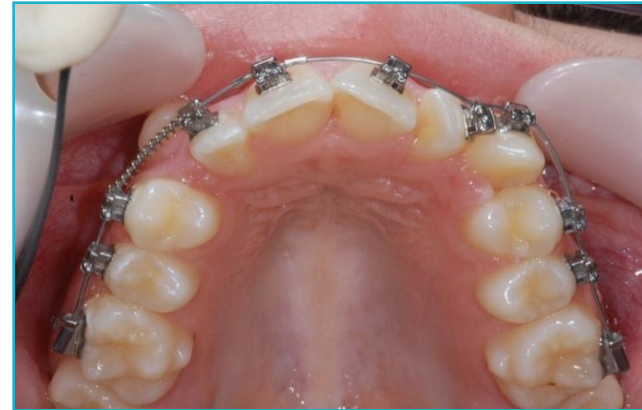



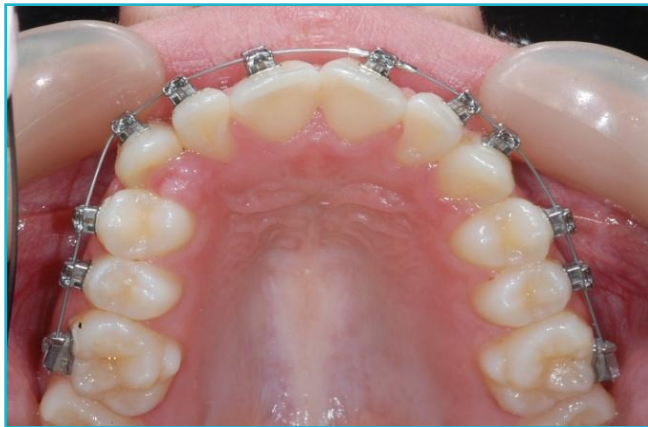## Upper arch sequence



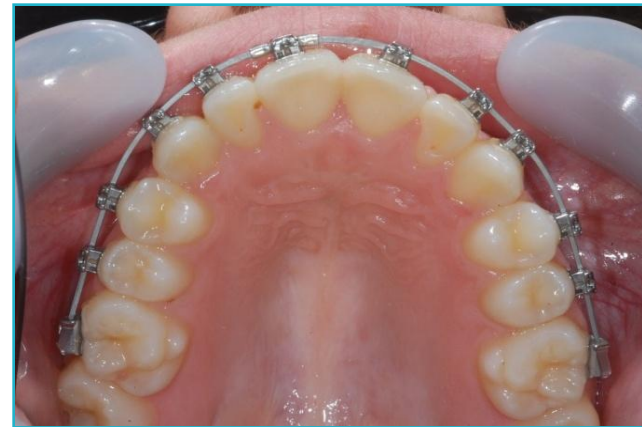1



2

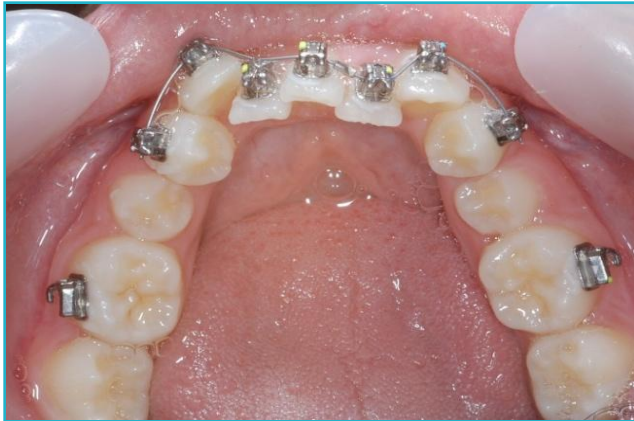

3

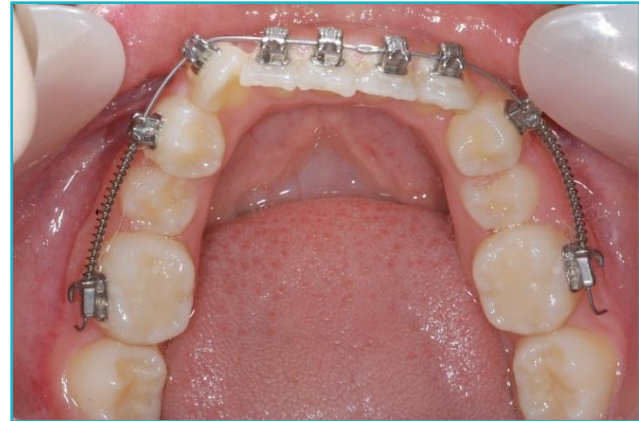

4

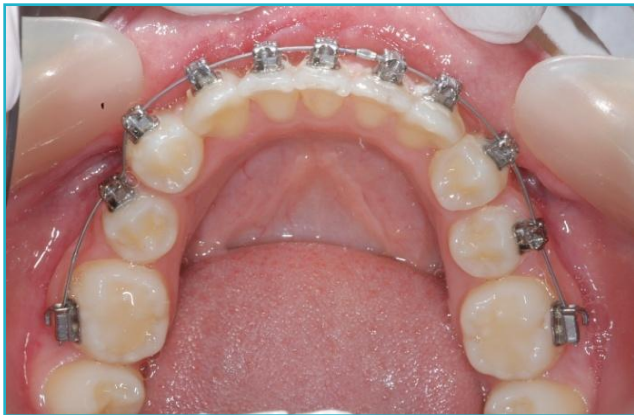## Lower arch sequence



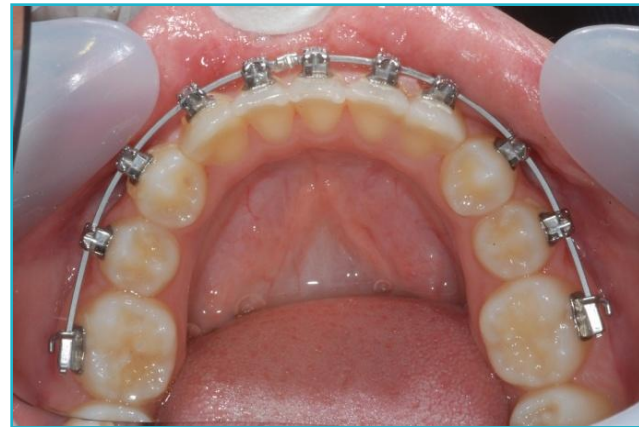1



2



3



4



**Before**



**After**





Smile Created by



*Confidence in your smile*