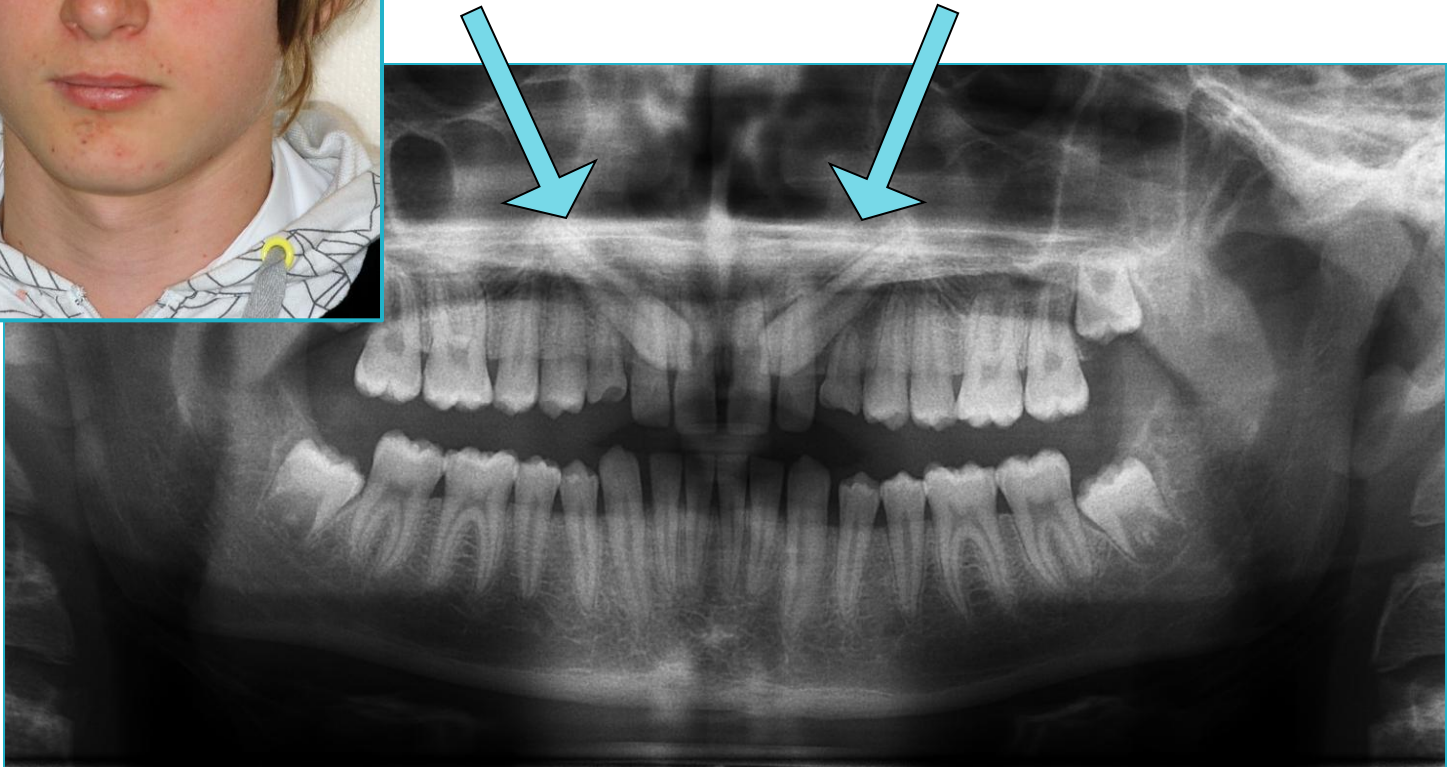
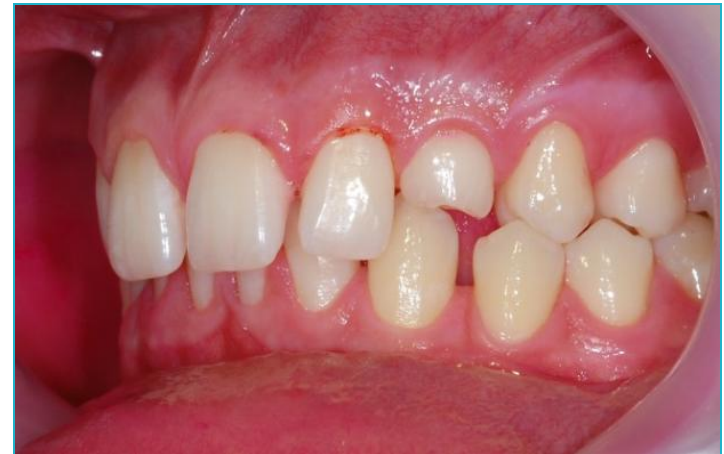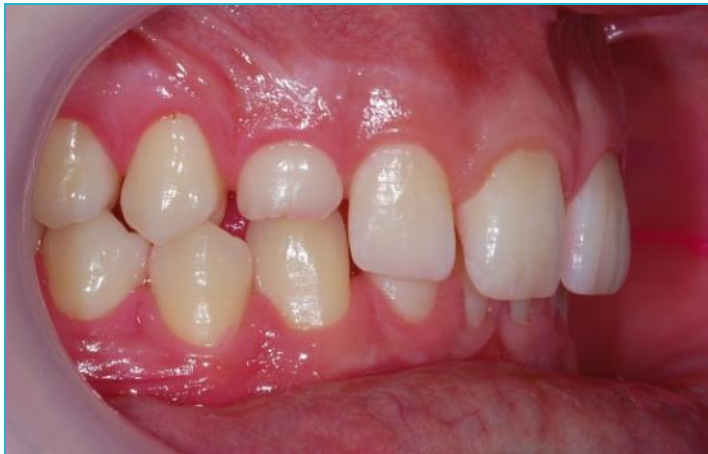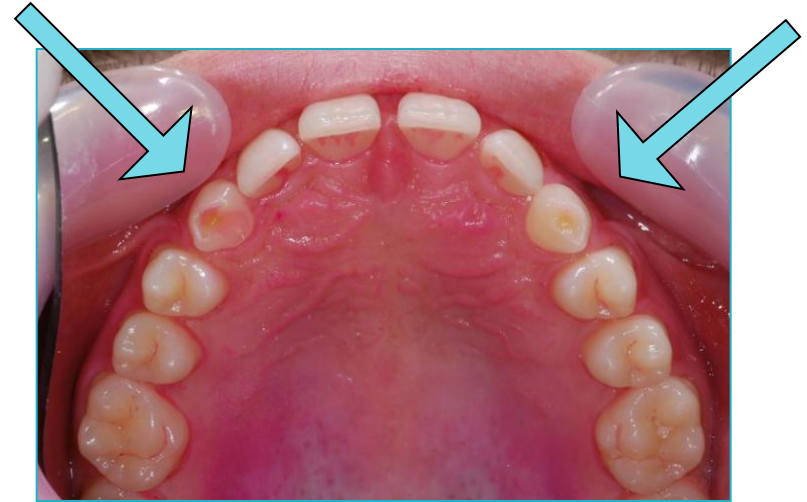


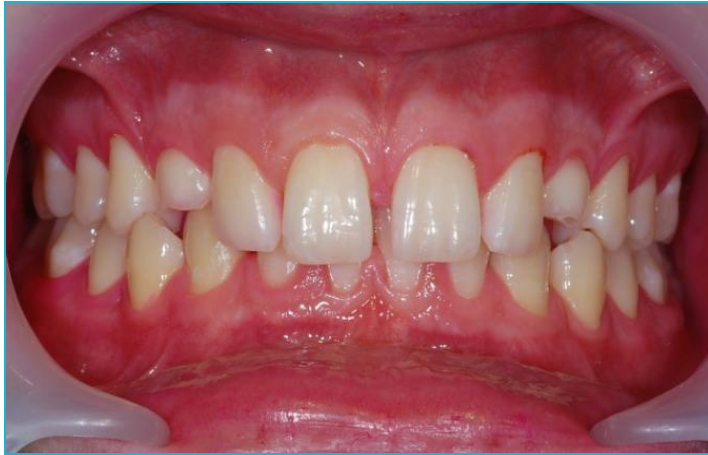

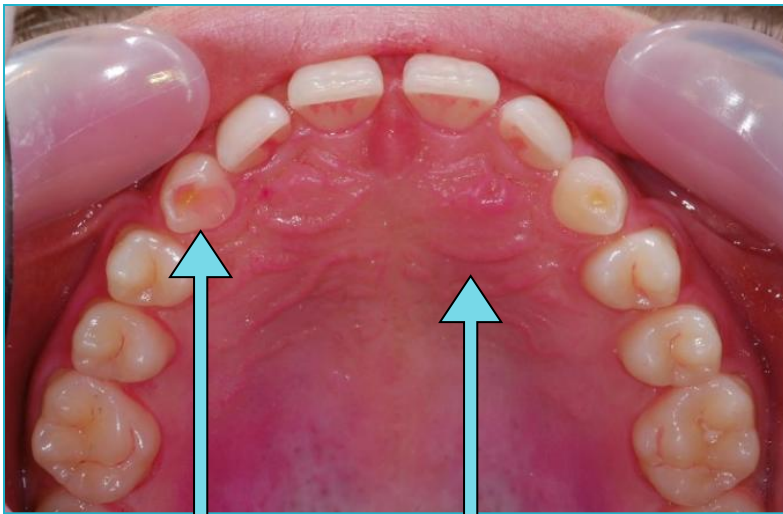
At 16 years, Callum was concerned about two upper canines which had failed to erupt and were impacted in the roof of his mouth



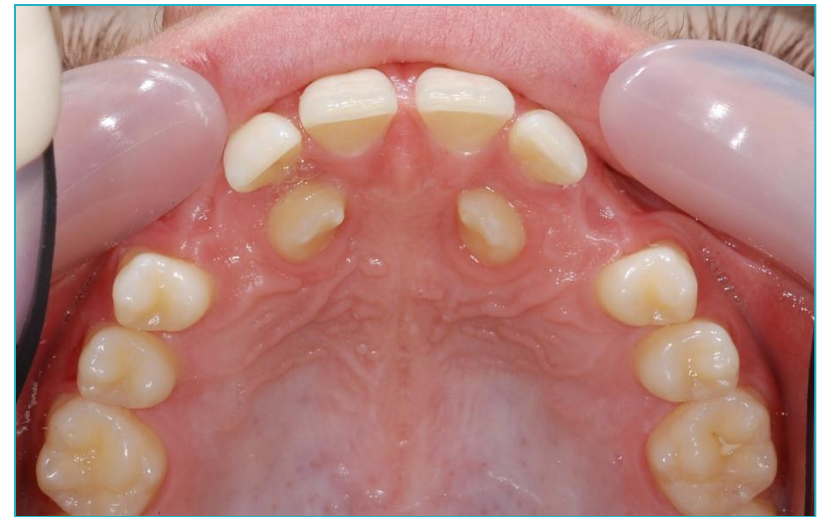The upper deciduous canines were retained



The buried canines were exposed surgically and the deciduous (baby) canines extracted. The canines then grew slowly into the palate.

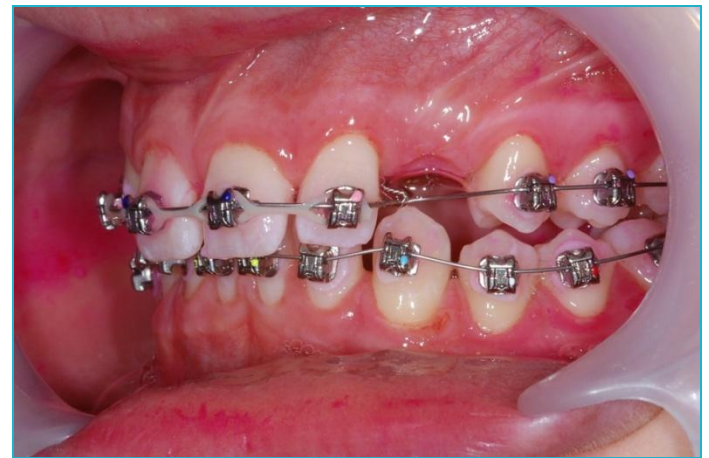
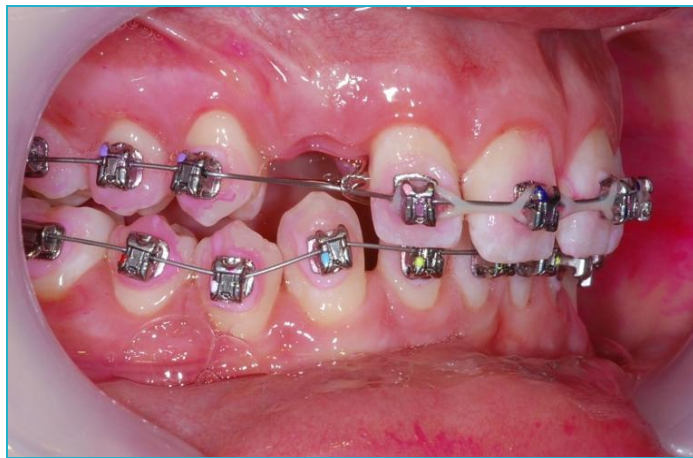
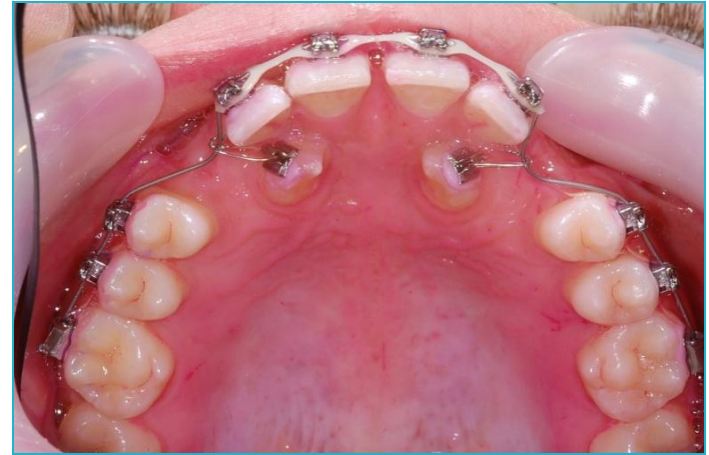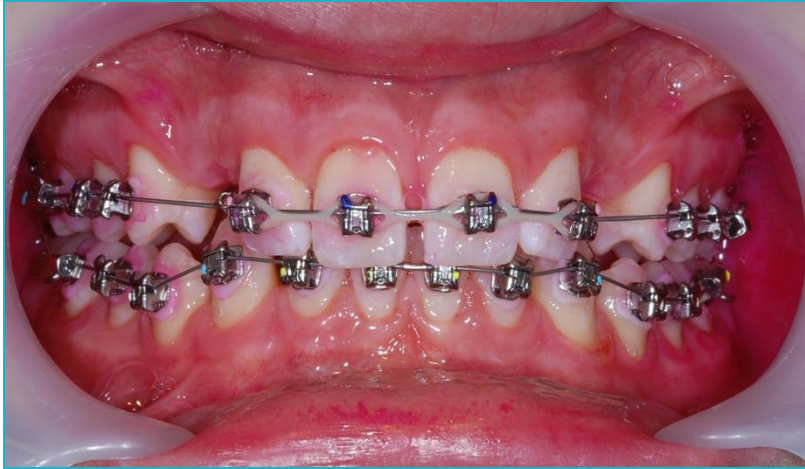Extracted

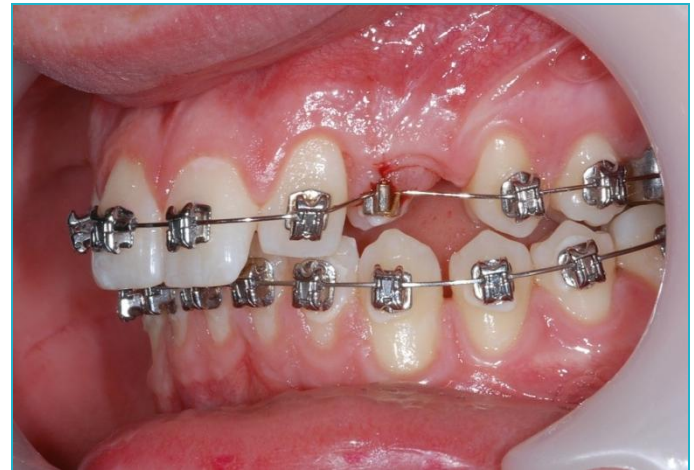
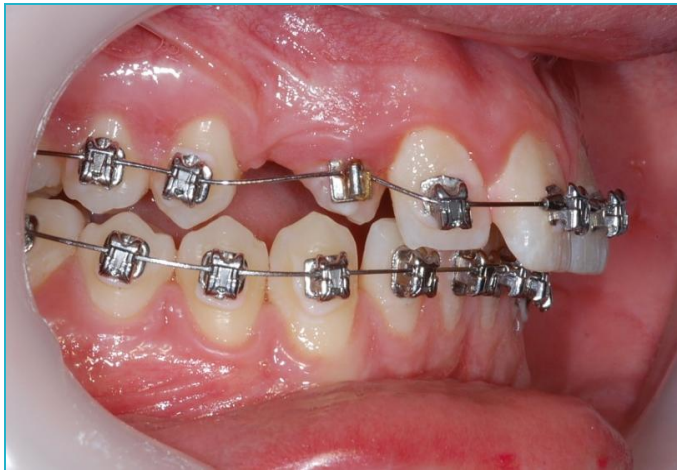
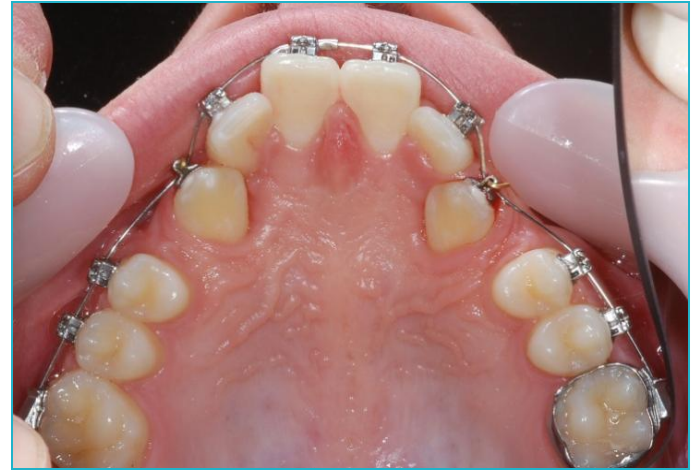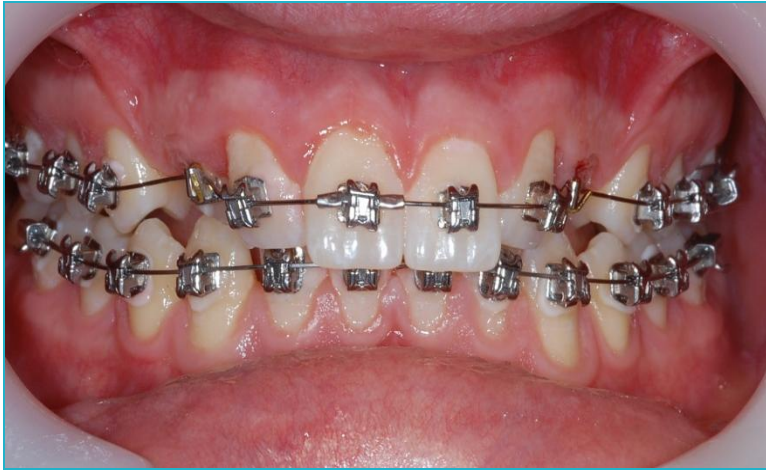Exposed

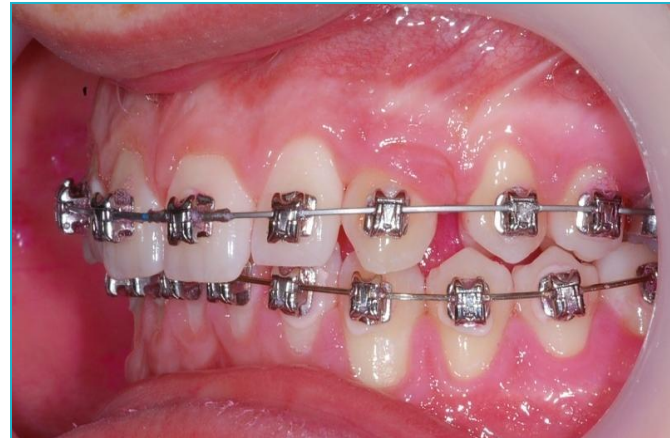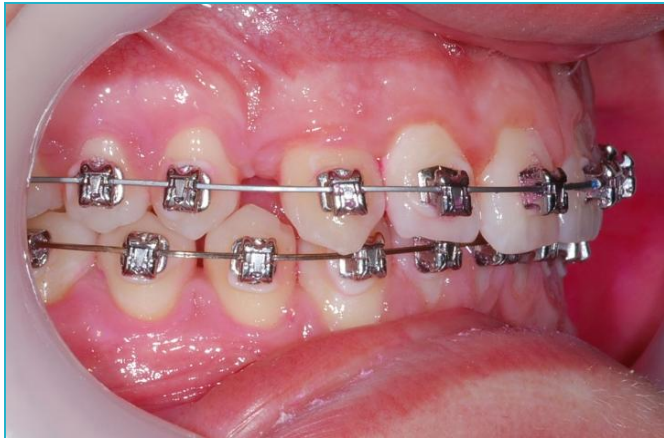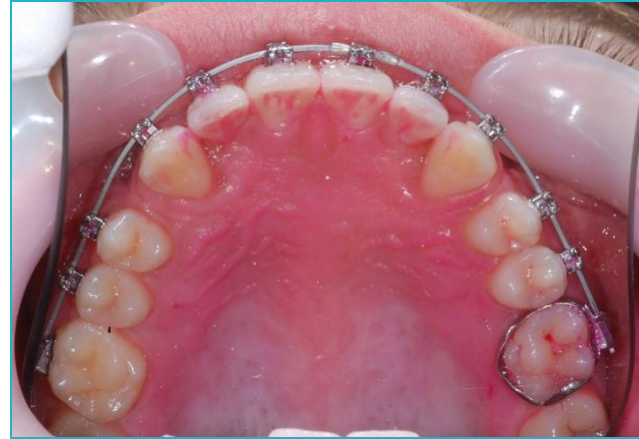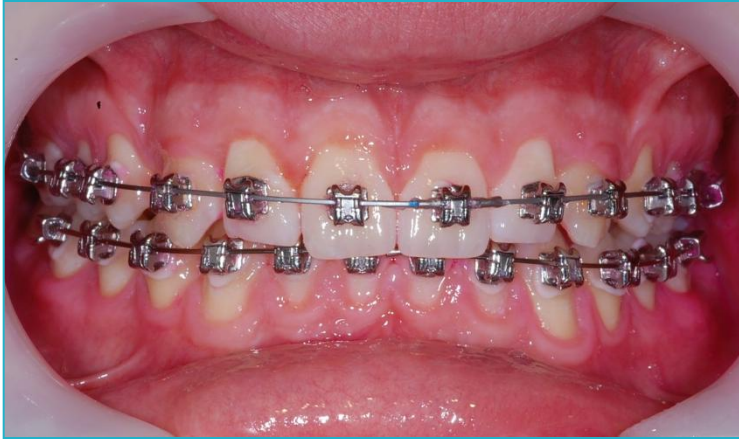Dr Horobin used the Damon 3mx brace



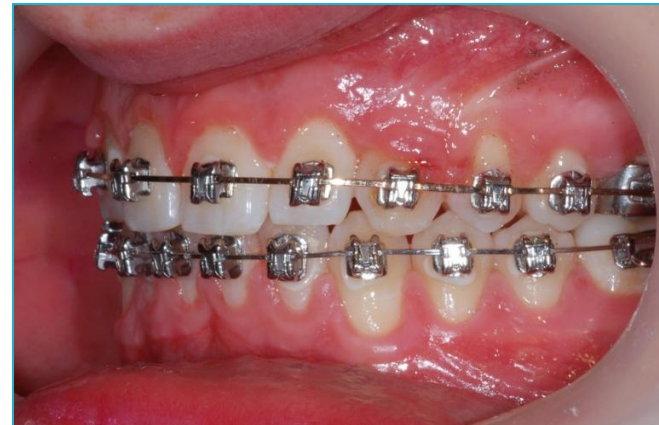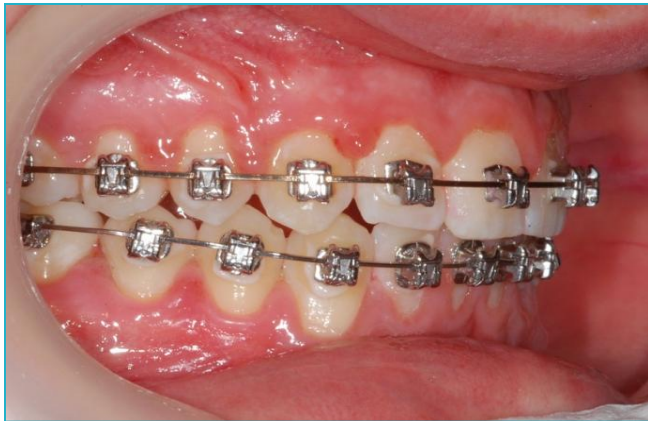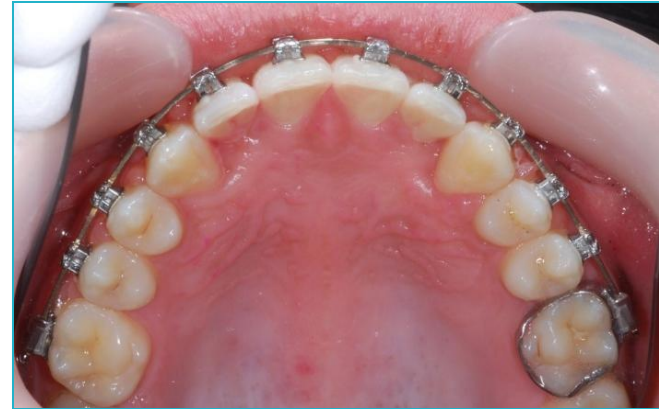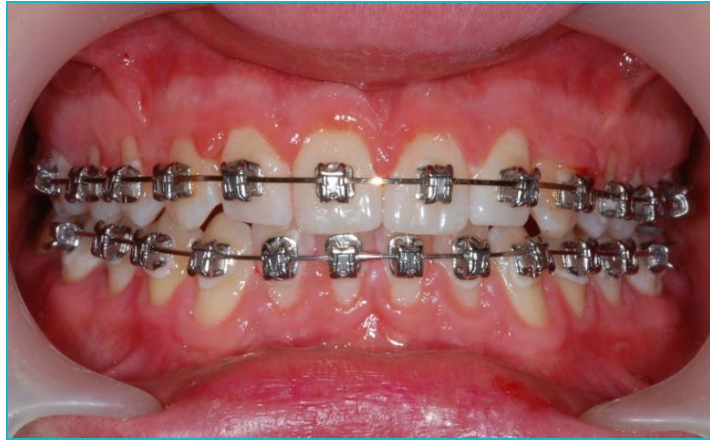Progress after 5 months



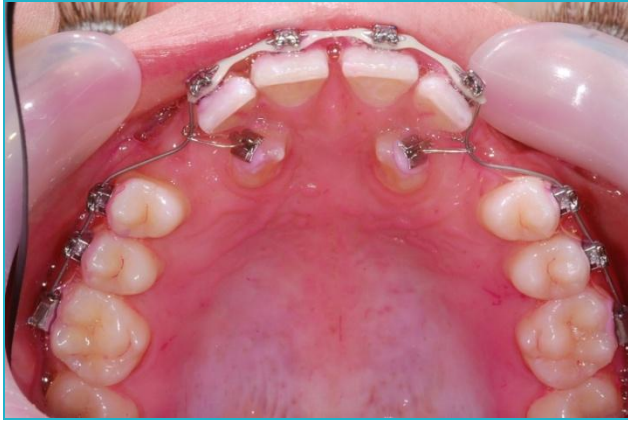Progress after 10 months



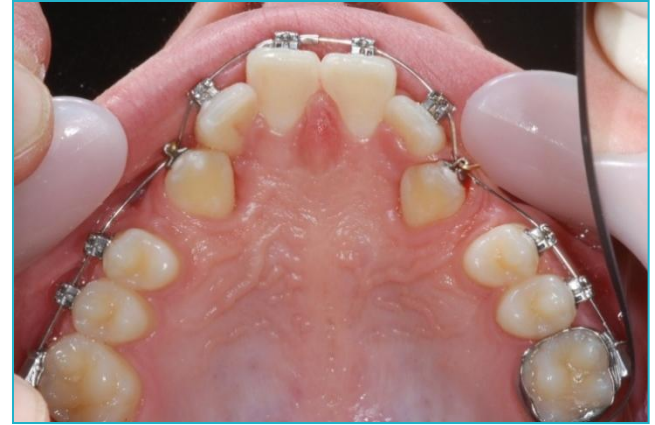Progress after 15 months



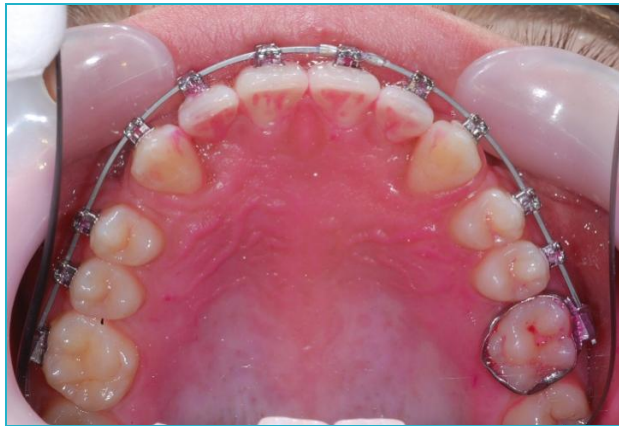Upper arch sequence



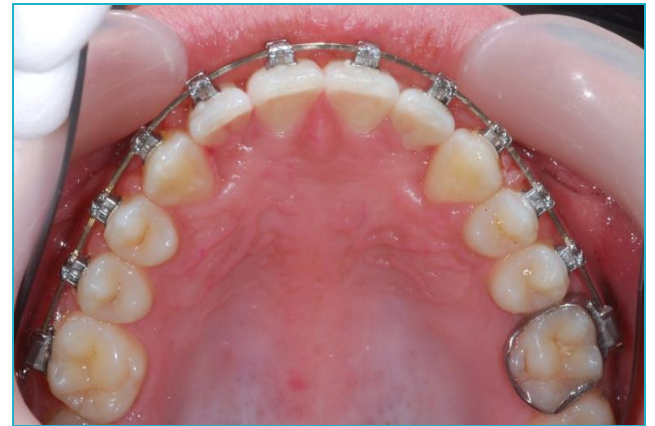1



2



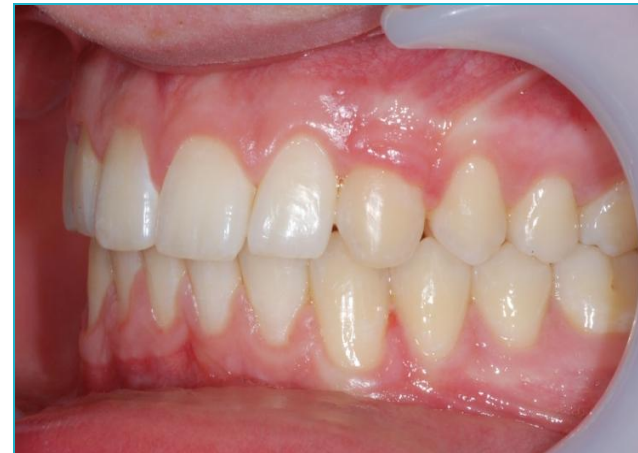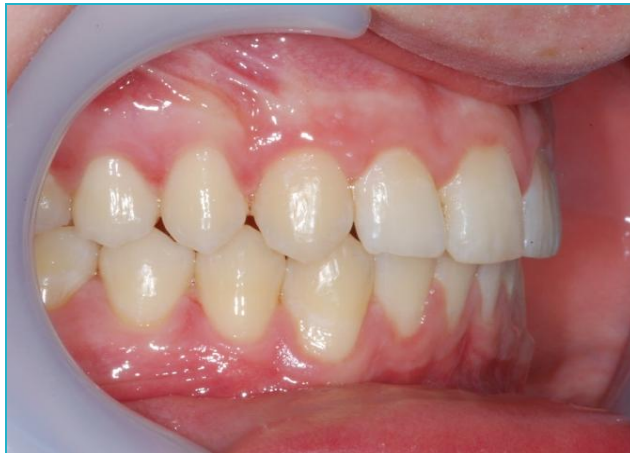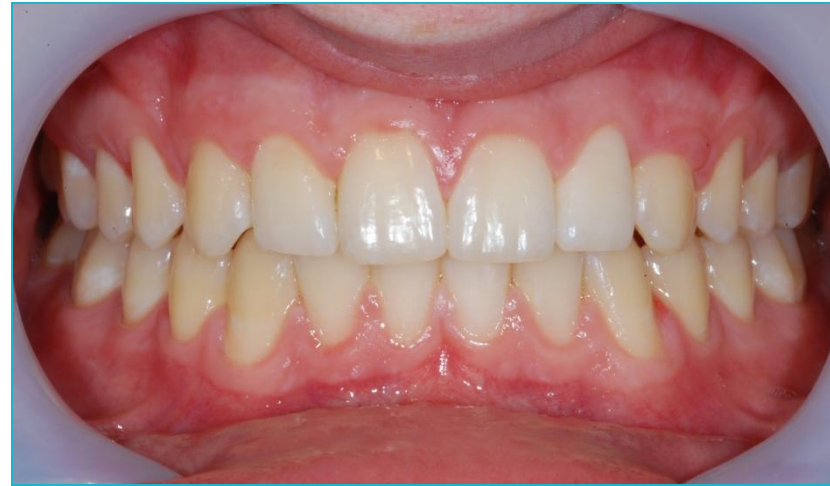3



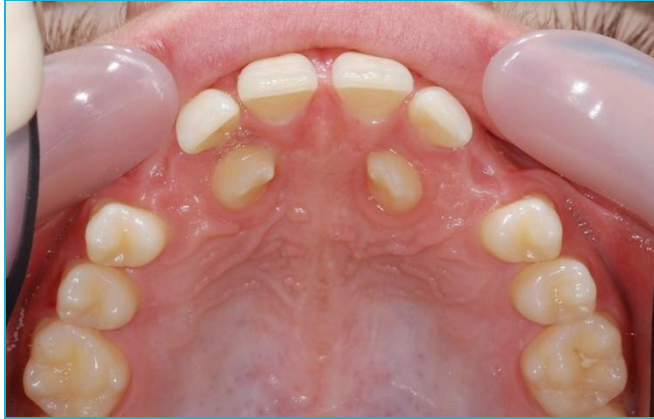4



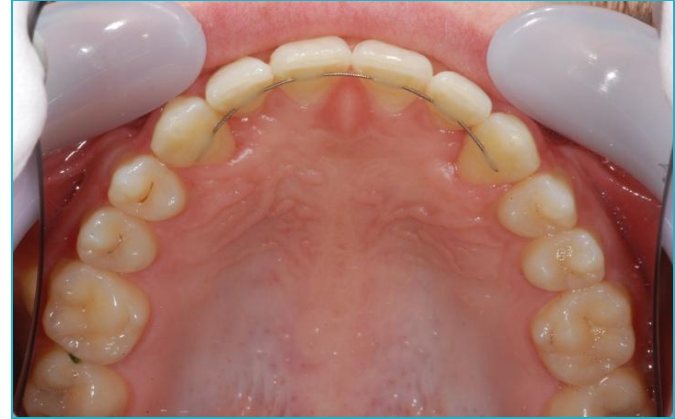**Finished Result
after 17 months**



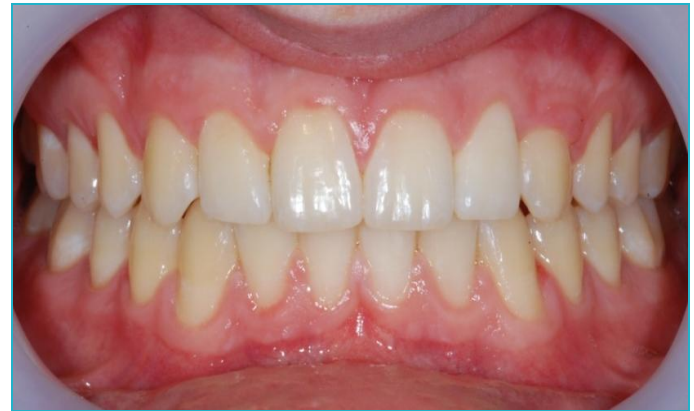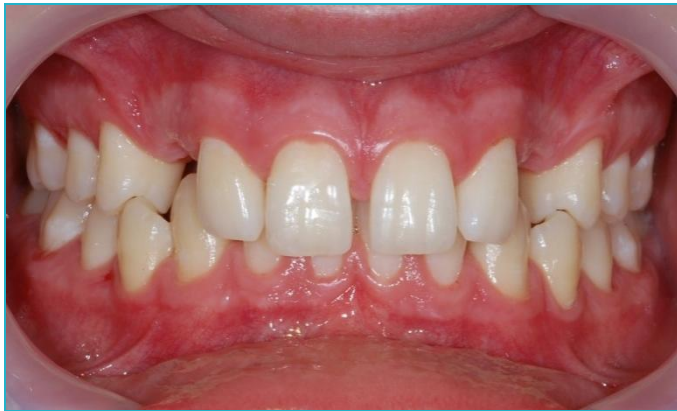Before



After



Note the fixed retainer



Before



After



Smile Created by



Confidence in your smile