

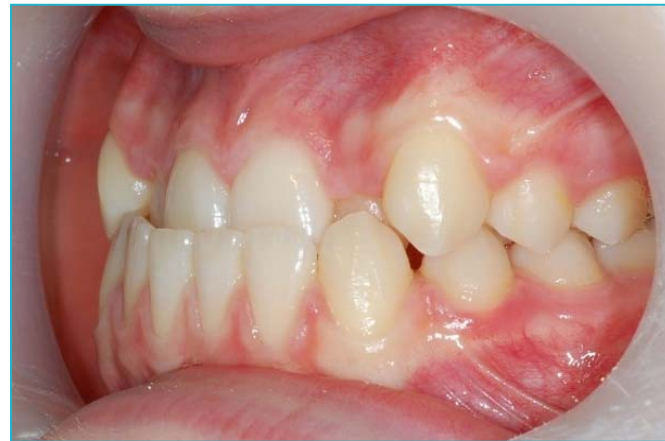
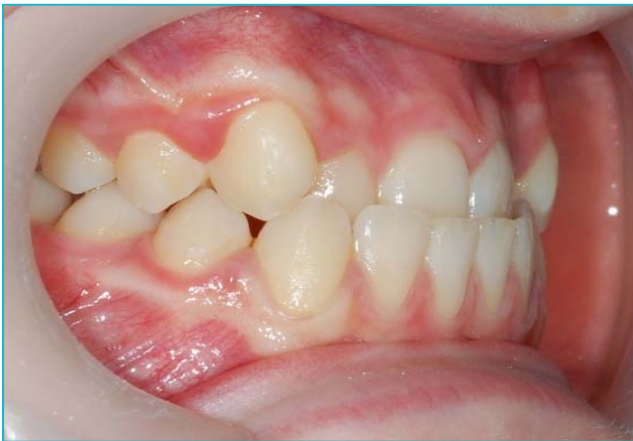
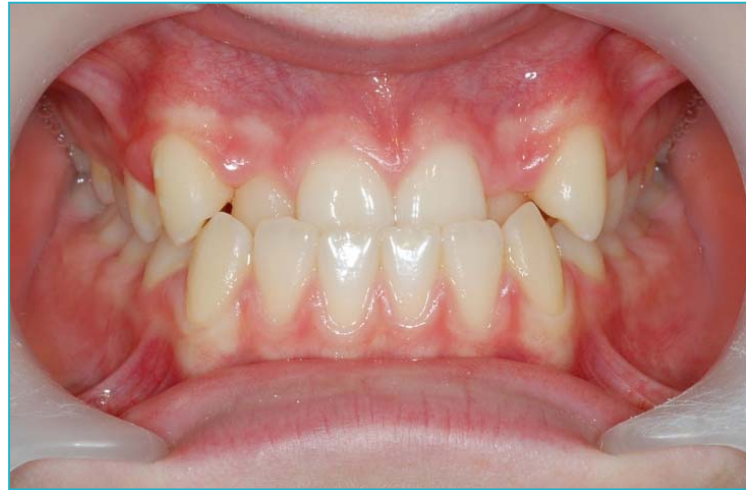*Confidence in your smile*

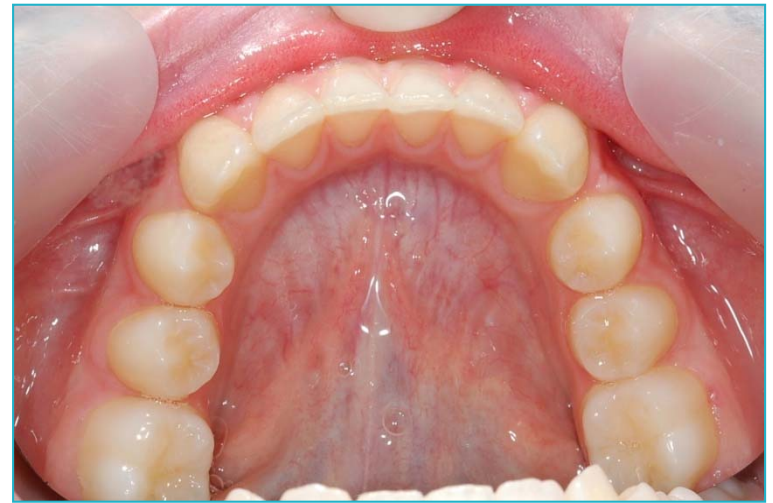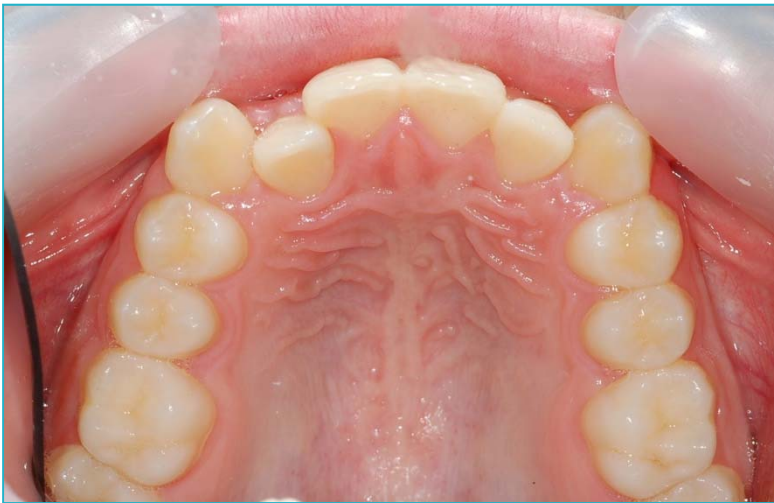presents

**DAMON<sup>®</sup>3**

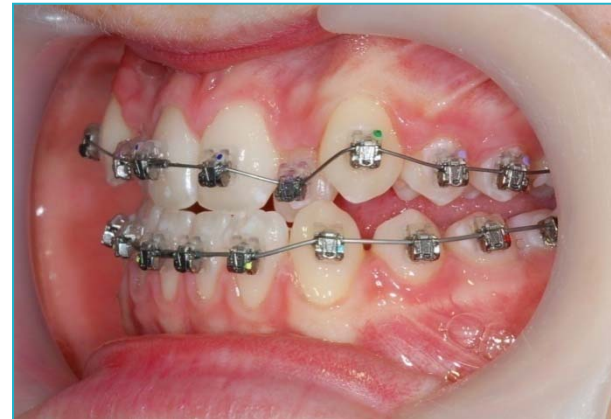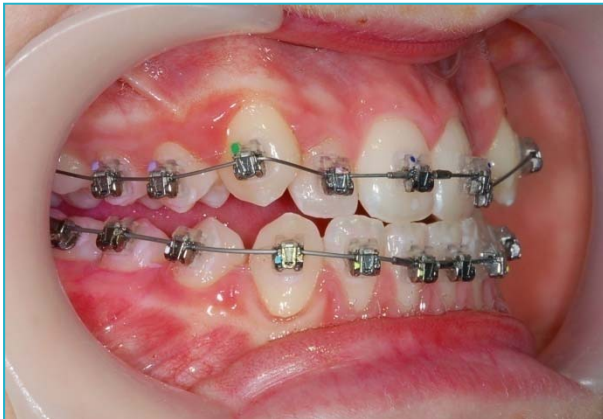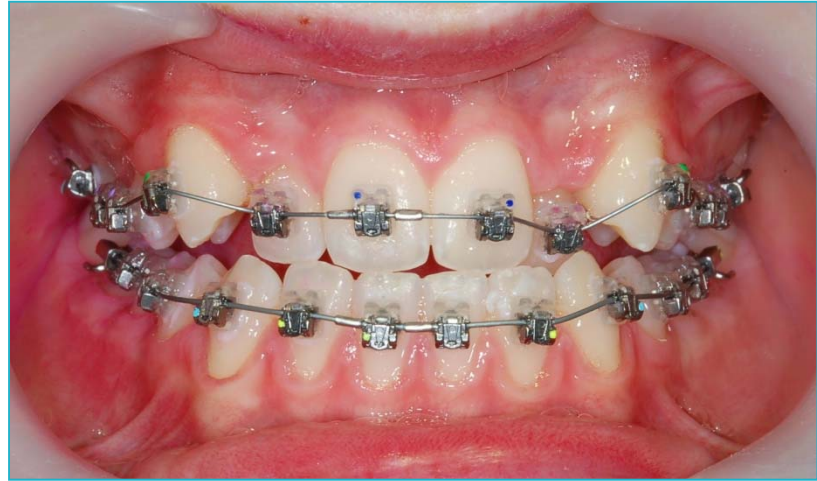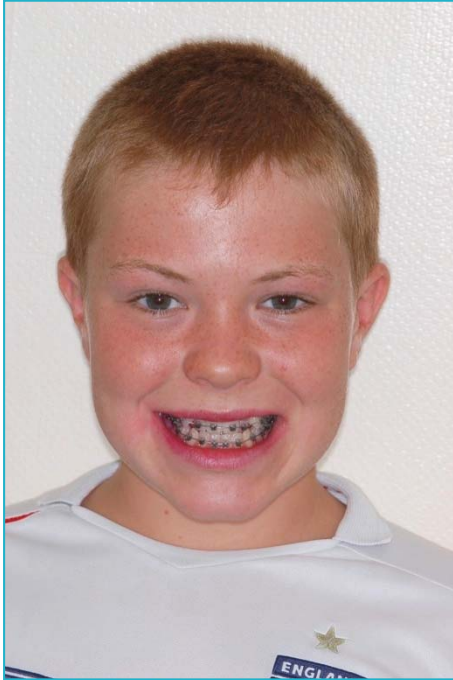**A case of severe reverse bite (Class III malocclusion) in a 12 year old boy.**



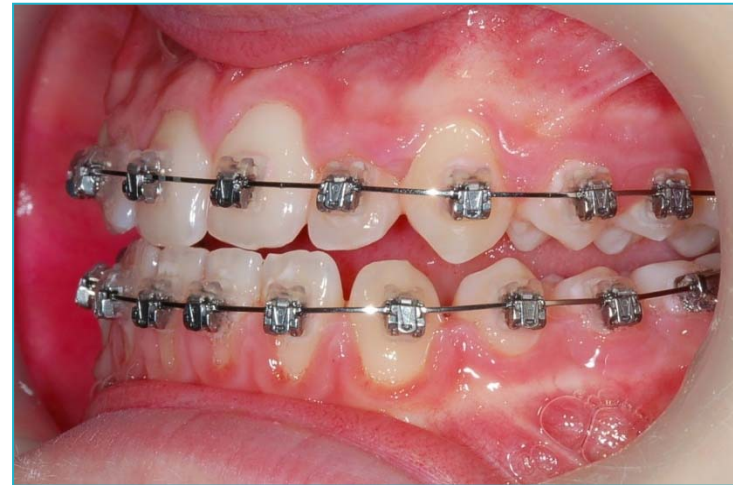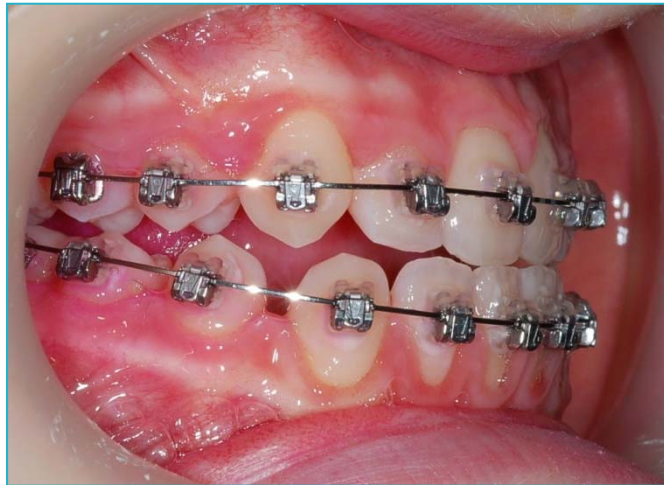
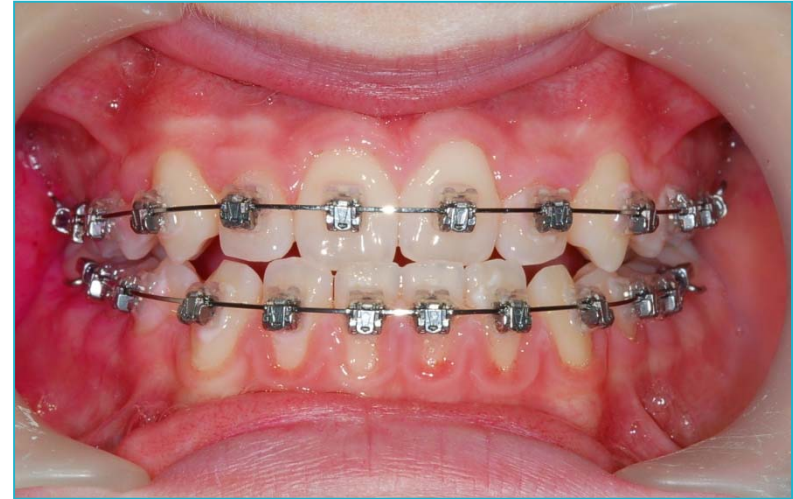
## Crowded upper arch



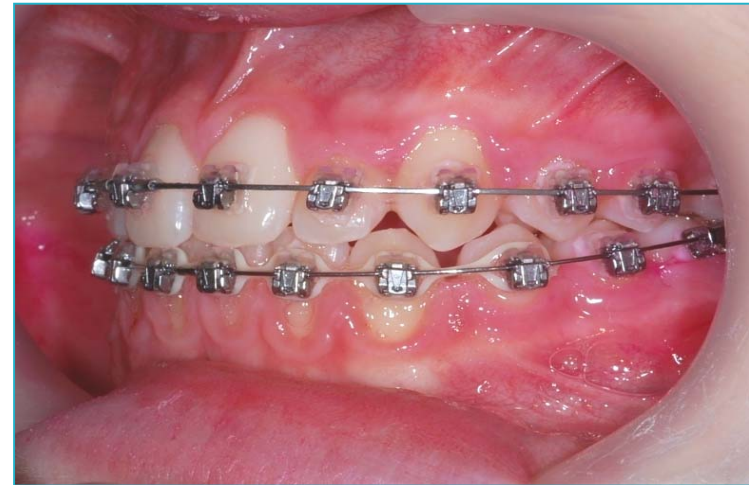
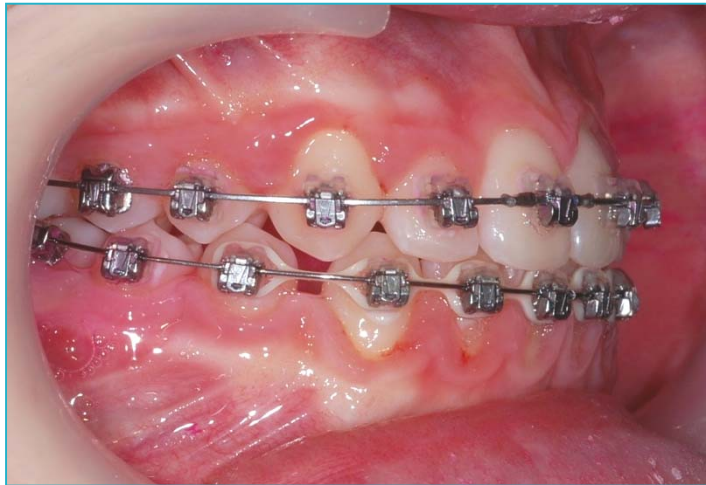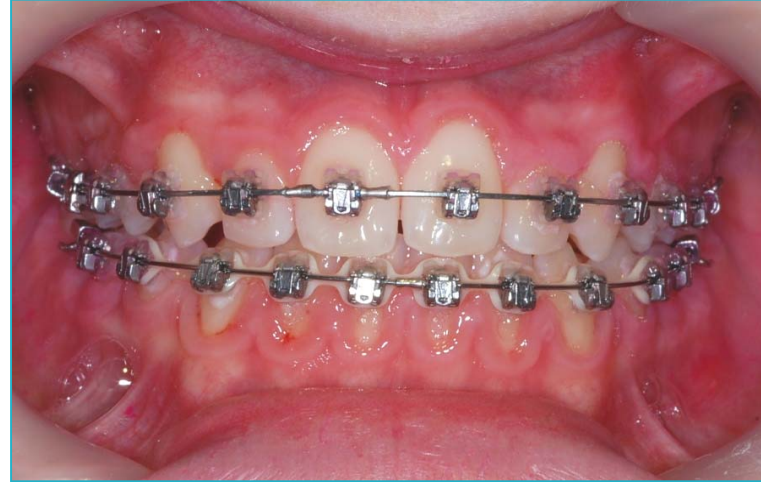
## Damon 3 Brace



## Progress after 2 months

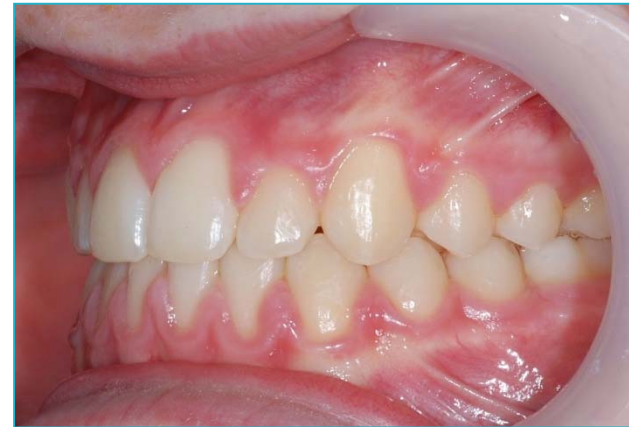
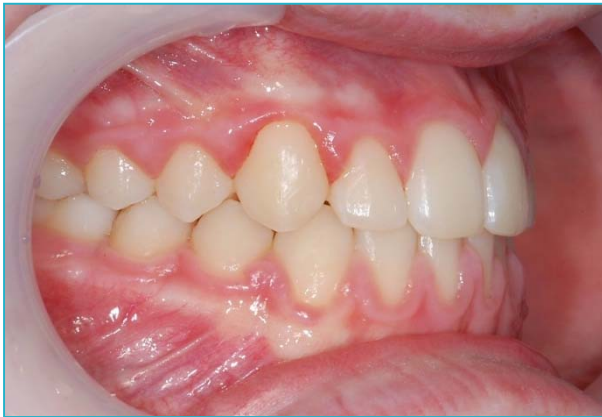
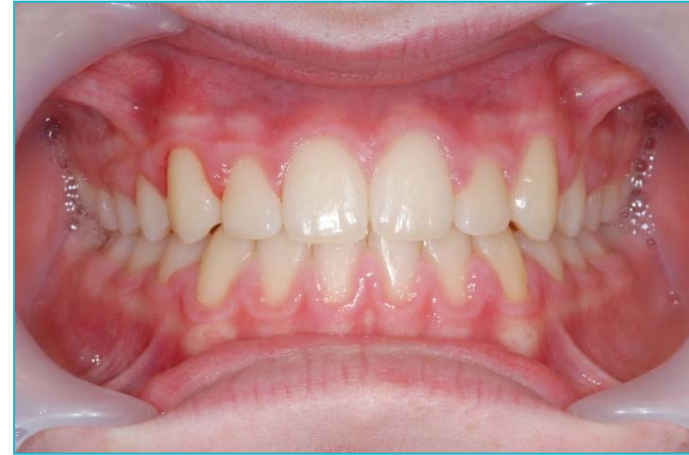## Progress after 6 months

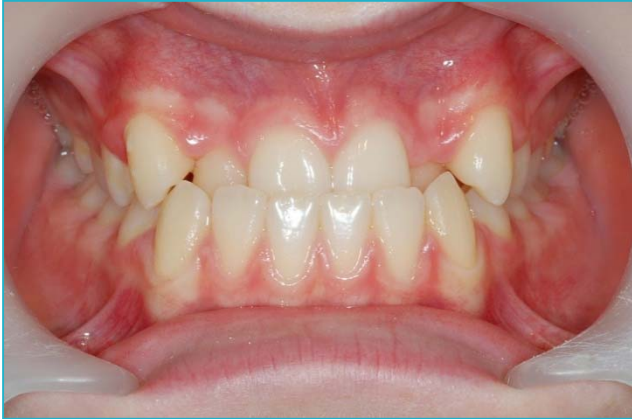



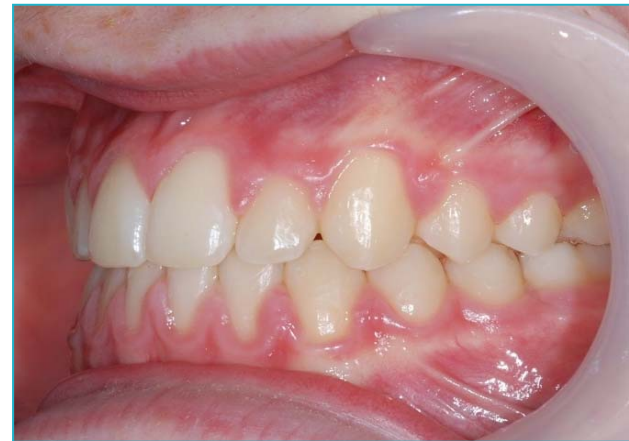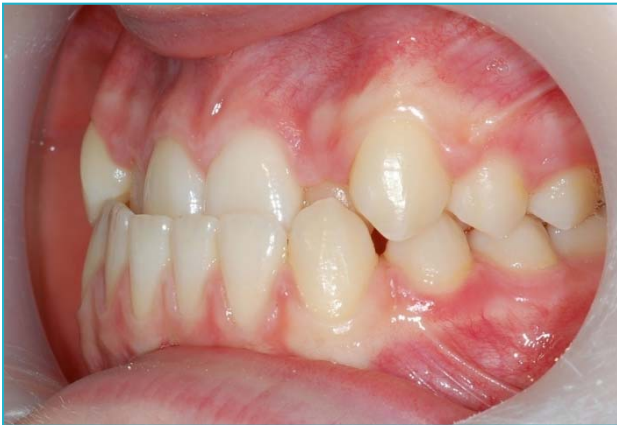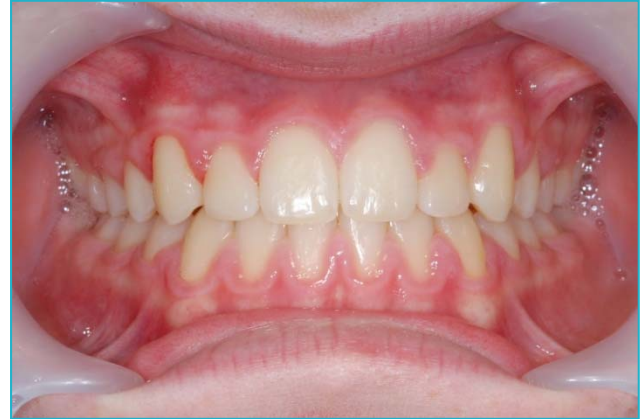## Finished Result



**Before**



**After**



**7 months treatment, without extractions**



# Smile Created By



*Confidence in your smile*