

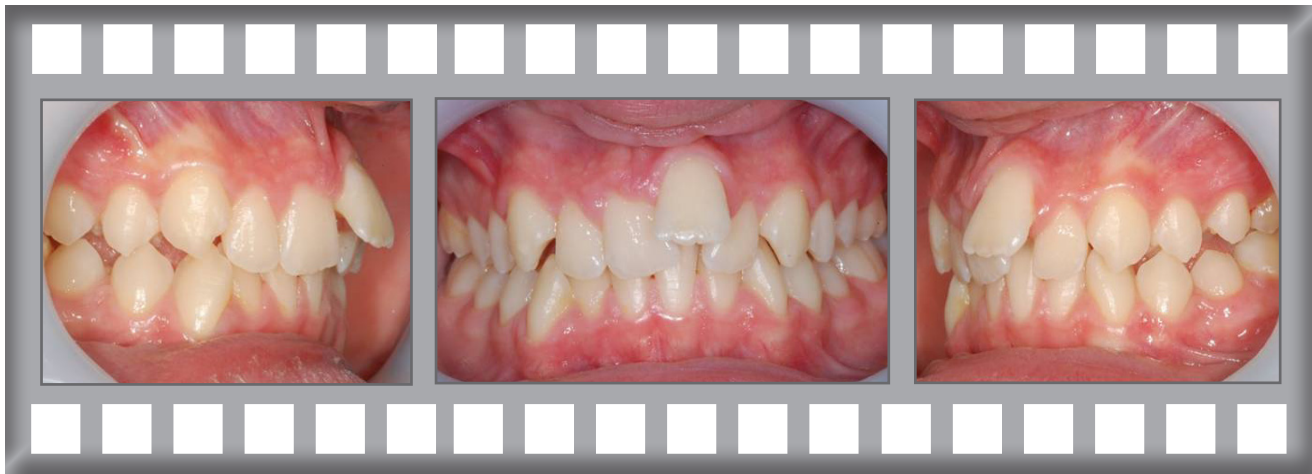Damon Q

Phoebe was concerned about her crowded upper teeth.

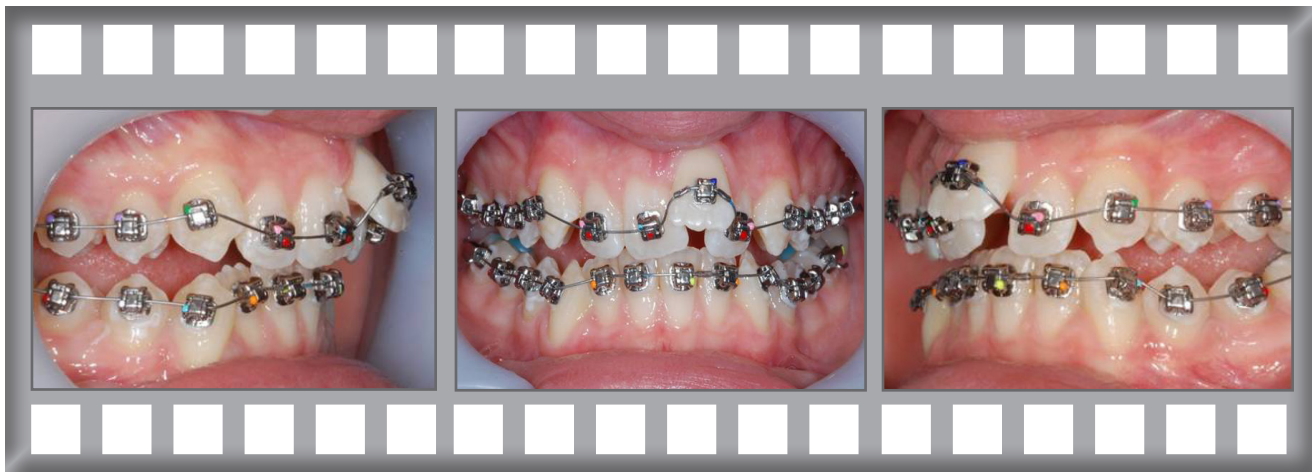
Treatment was complete after 10 months using the Damon Q system without extractions.



Phoebe

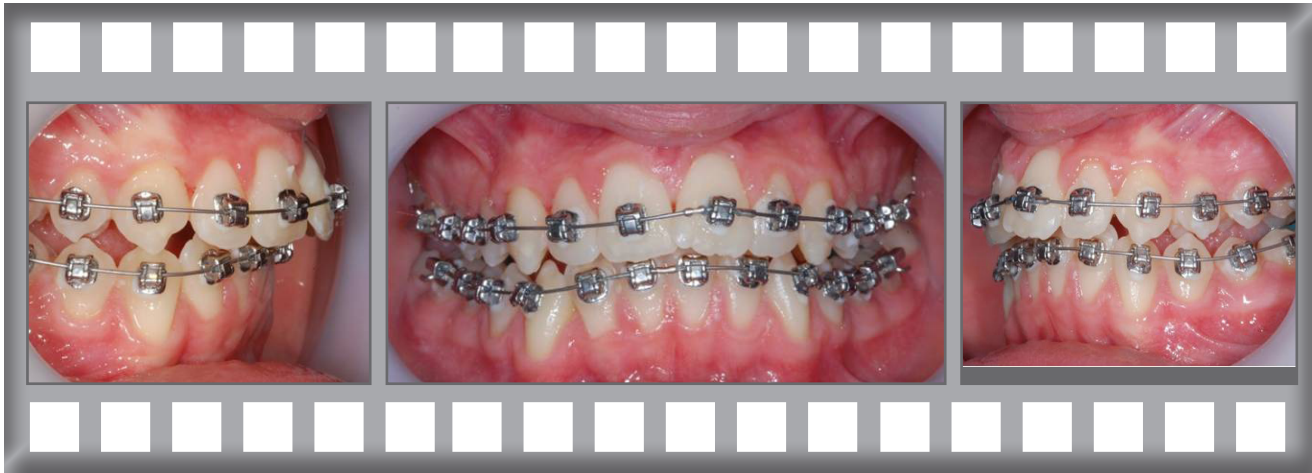

The upper incisors were very irregular and the lowers were slightly crowded.

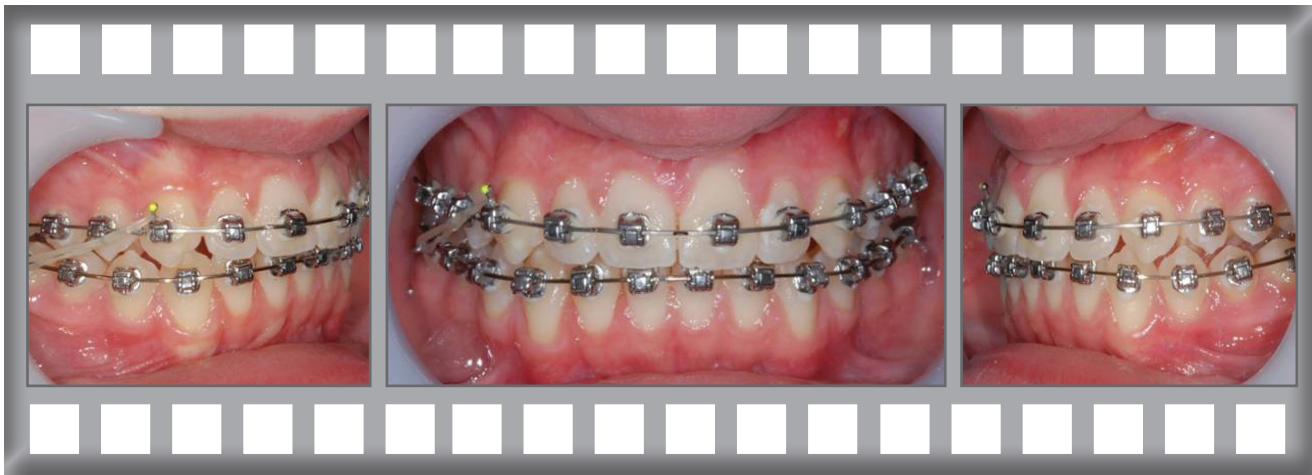

Dr Horobin used the Damon Q system.

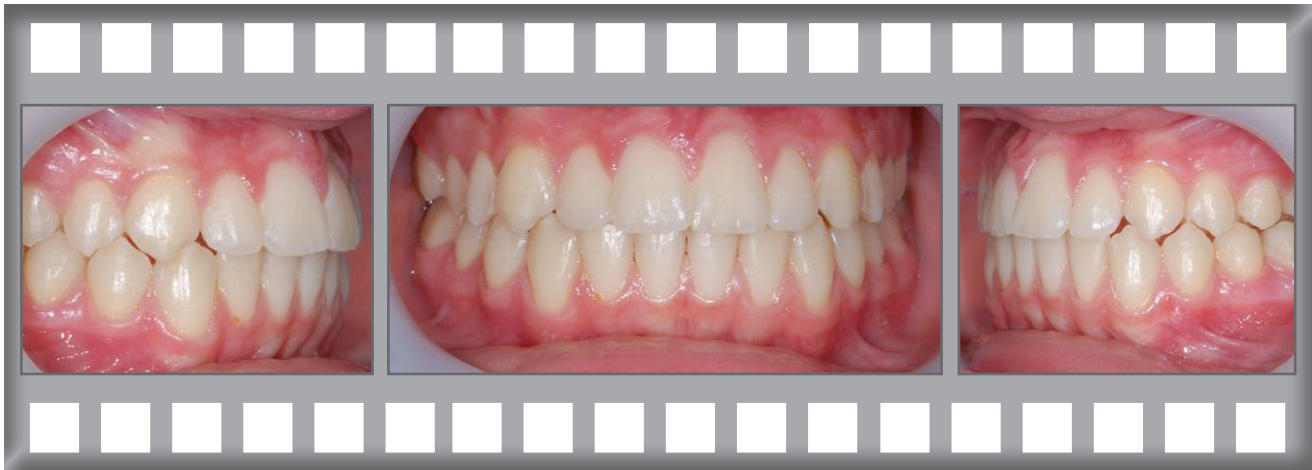Progress after 2 months.



Progress after 6 months.



The finished result after just 10 months.

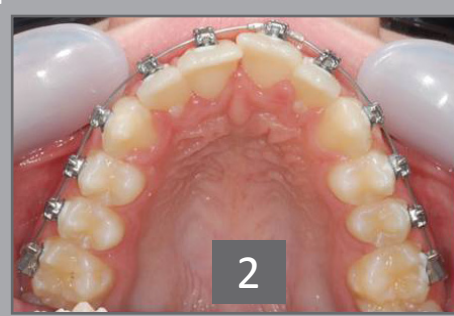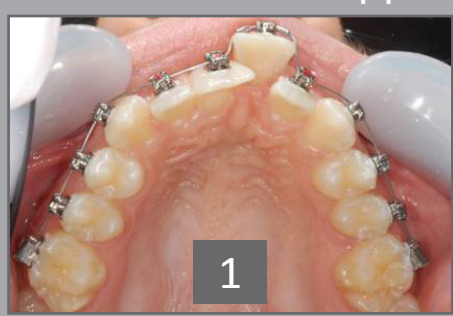




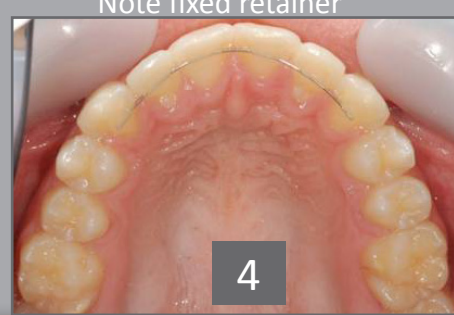
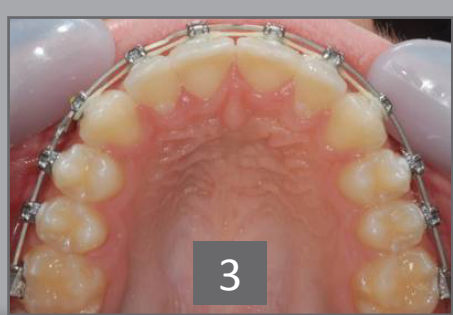Phoebe was delighted with her result.

Treatment was complete after 10 months using the Damon Q system.

Upper arch Sequence



Note fixed retainer



Front Sequence

