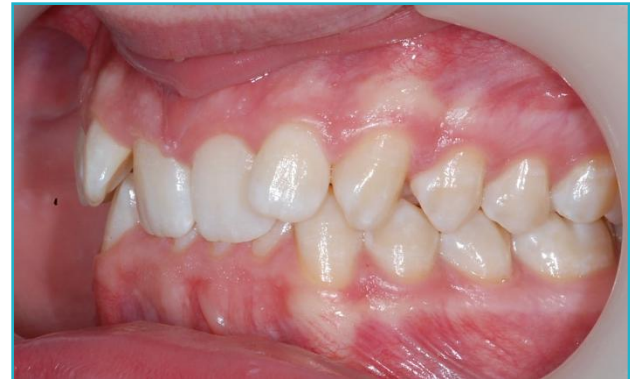
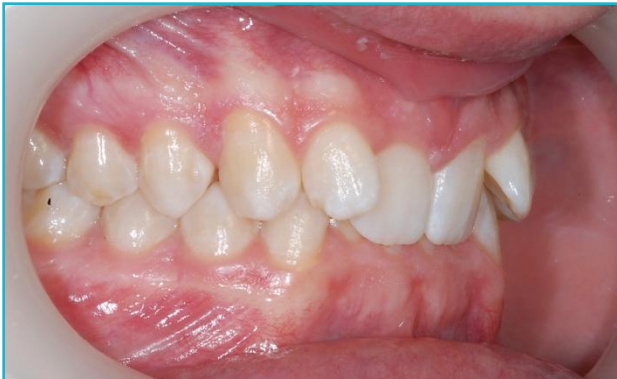
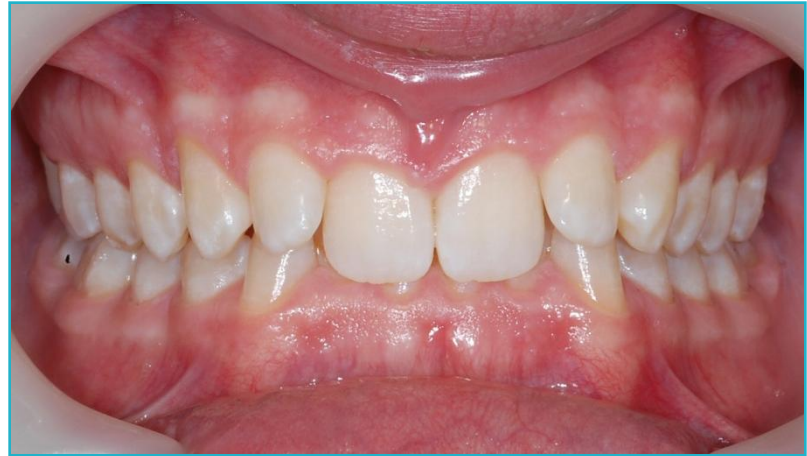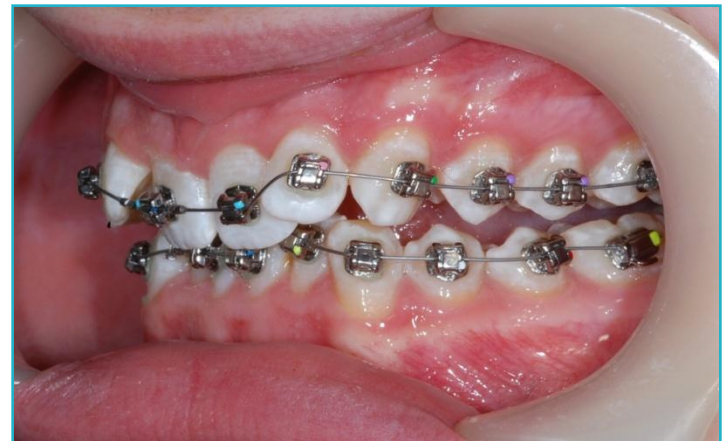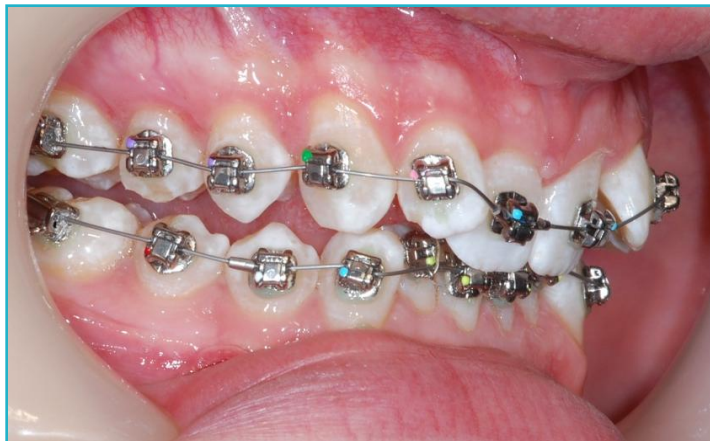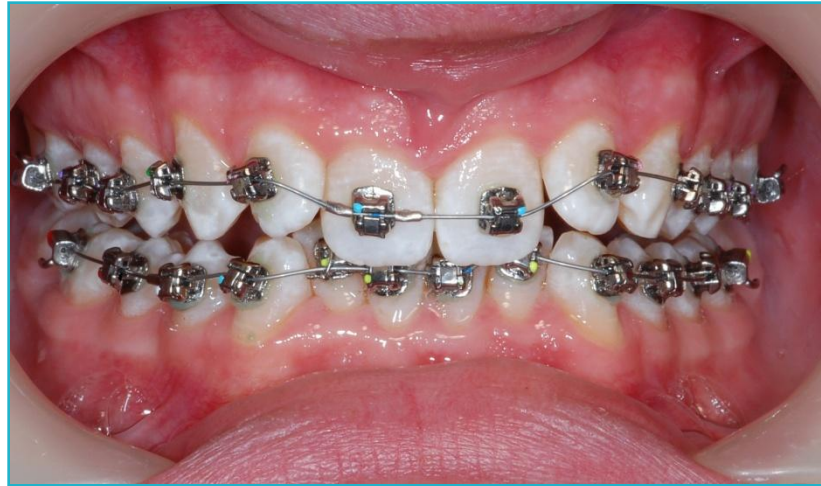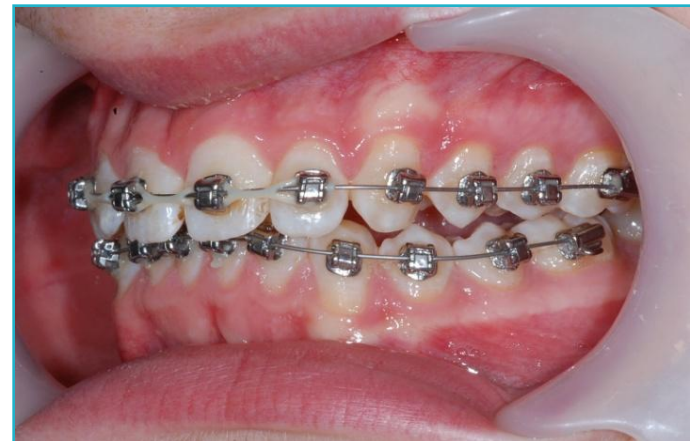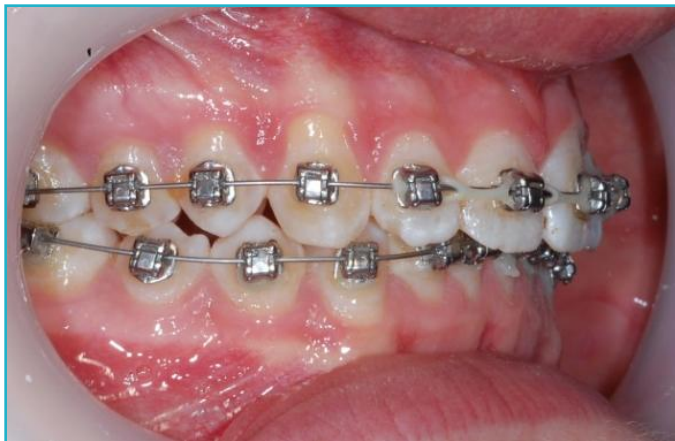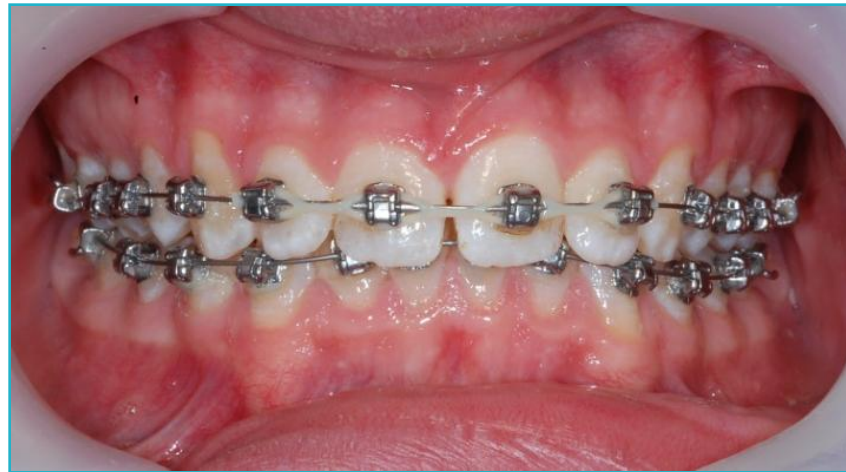**Joshua presented at 16 years of age,  
concerned about his irregular front  
teeth.**



**Dr Horobin used the Damon Q Brace, without extractions.**

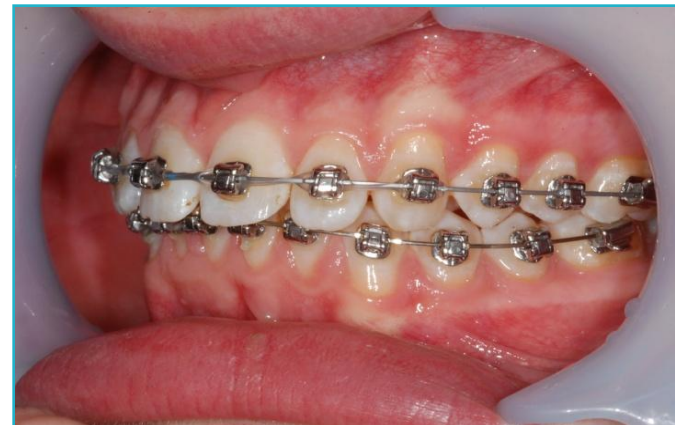
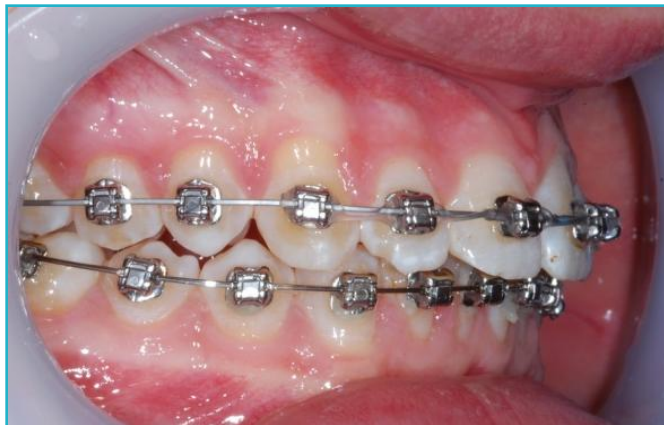
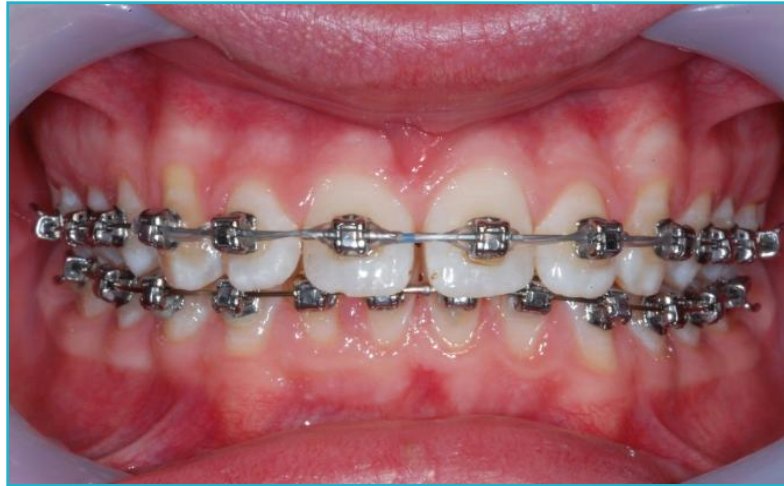## Progress after 3 months

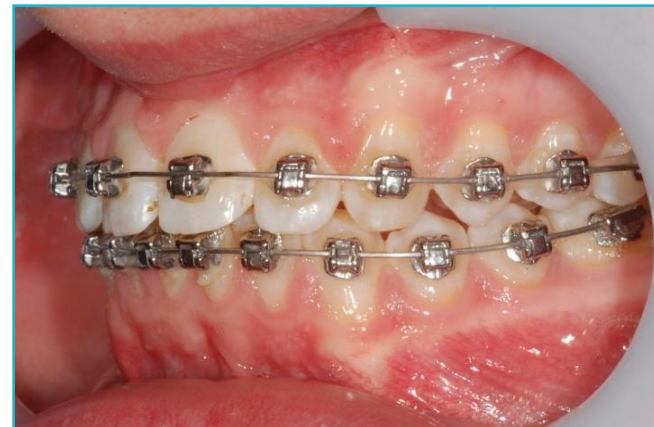
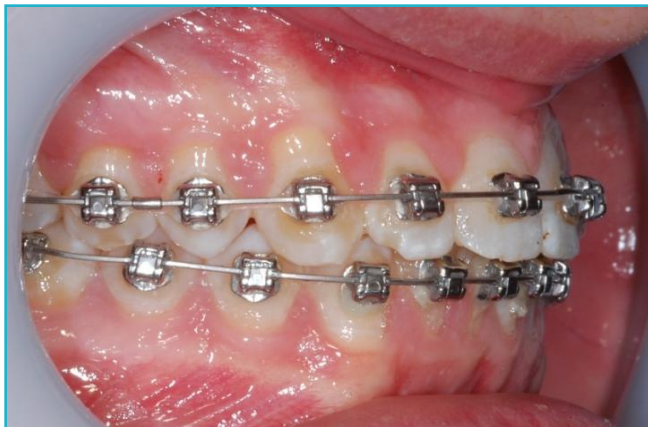
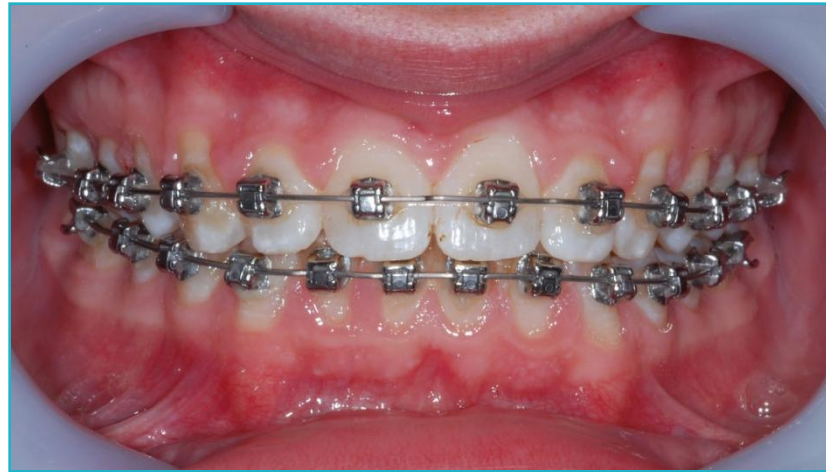


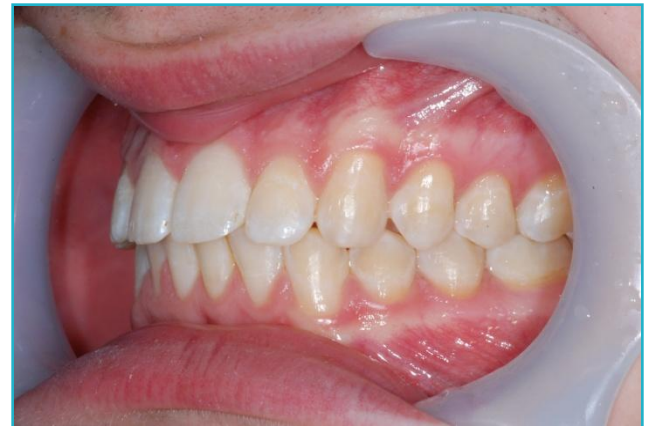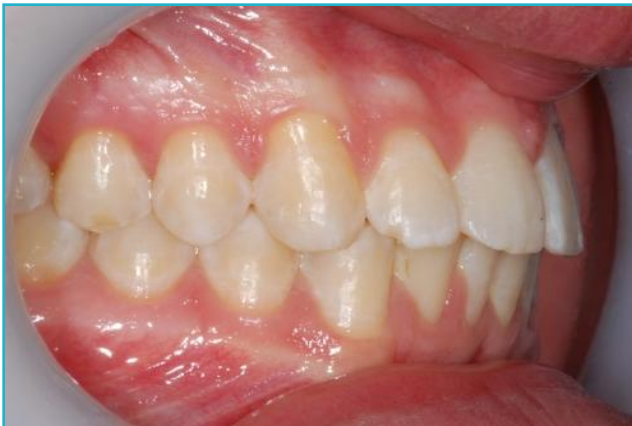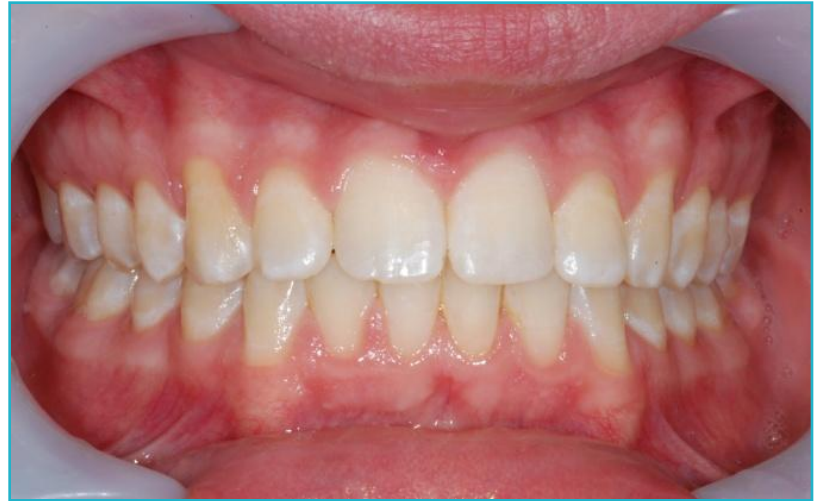## Progress after 8 months



## Progress after 13 months

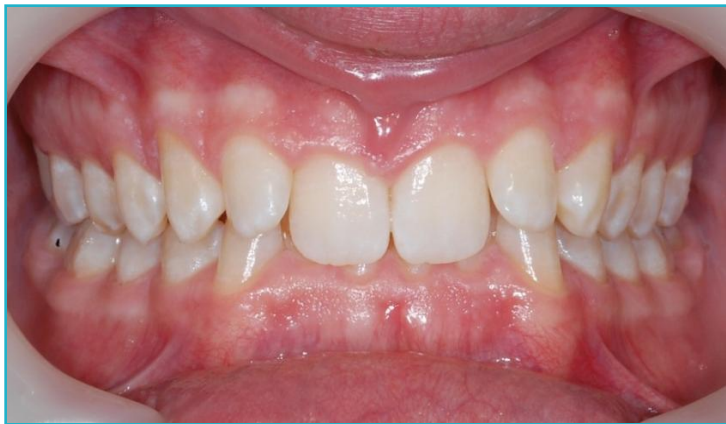

## Finished Result after 14 months

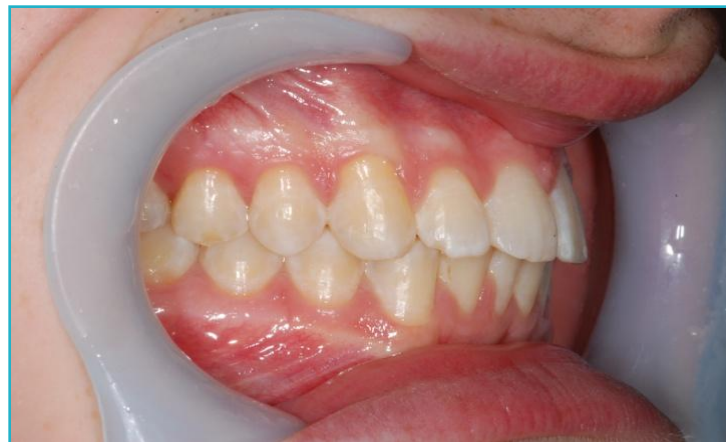
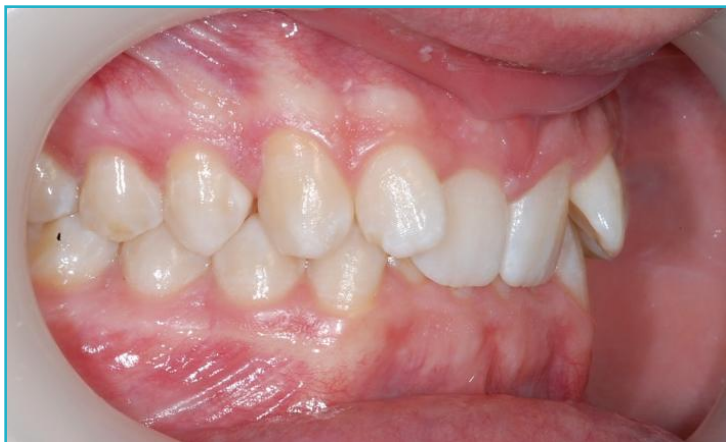
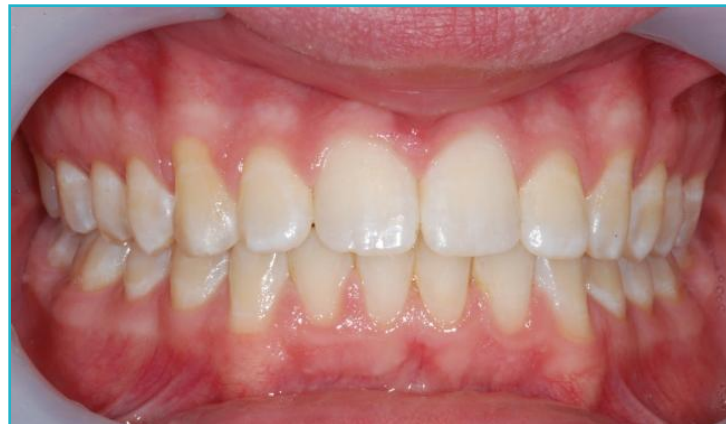

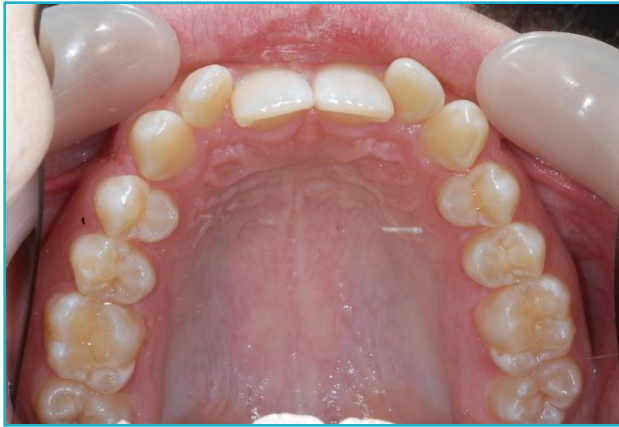**Before**



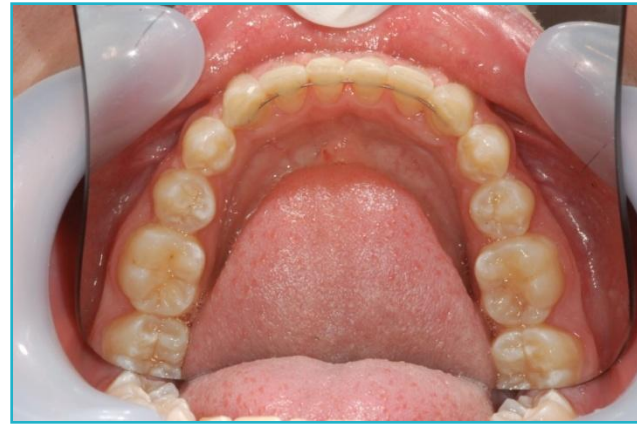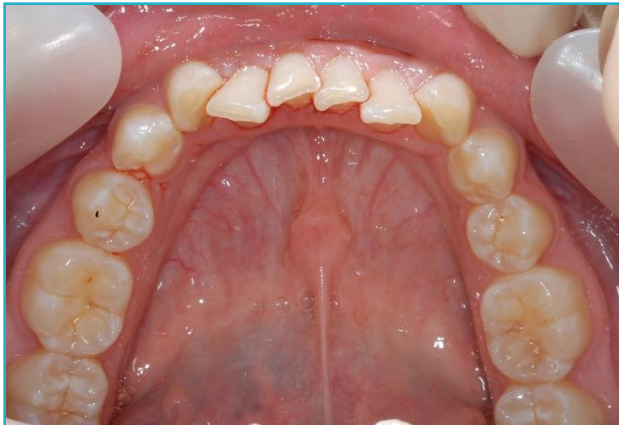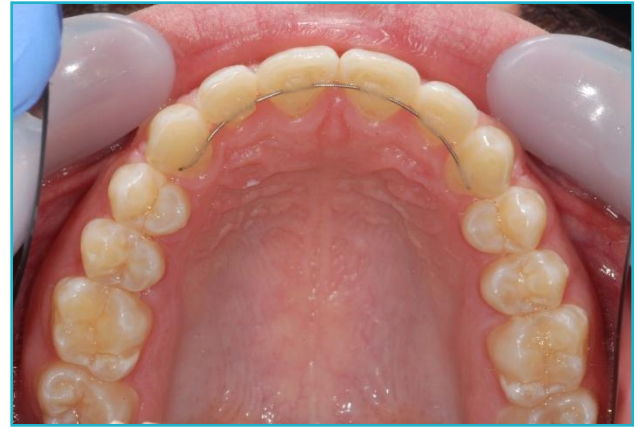**After**



**Before**

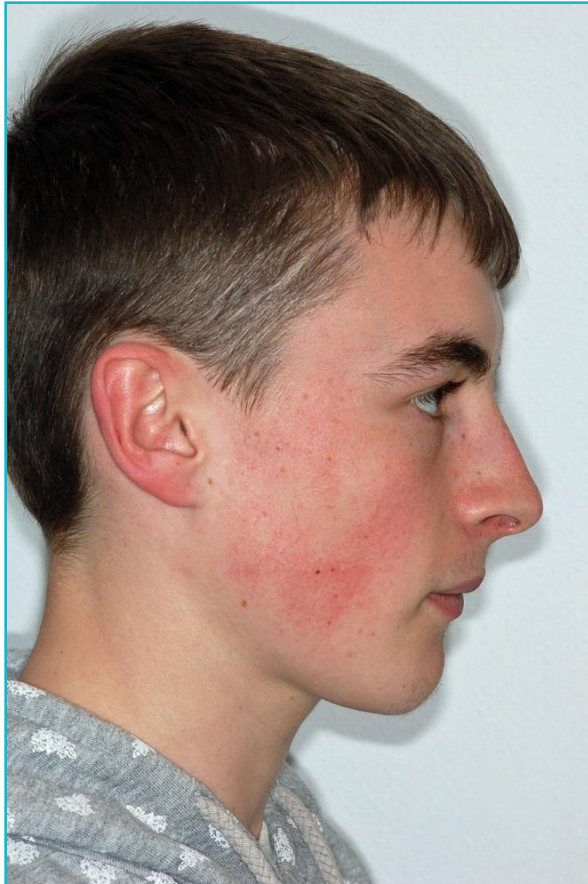


**After**

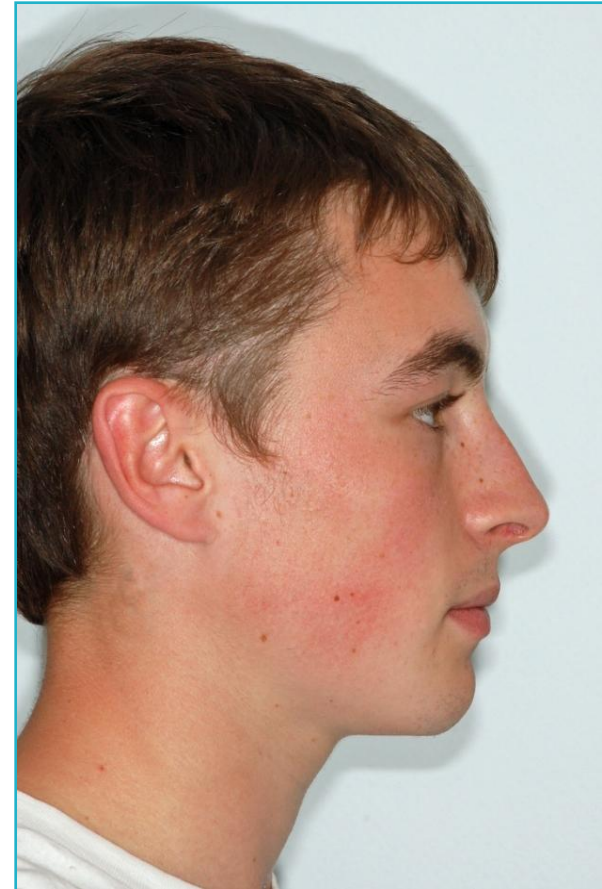



**Before**

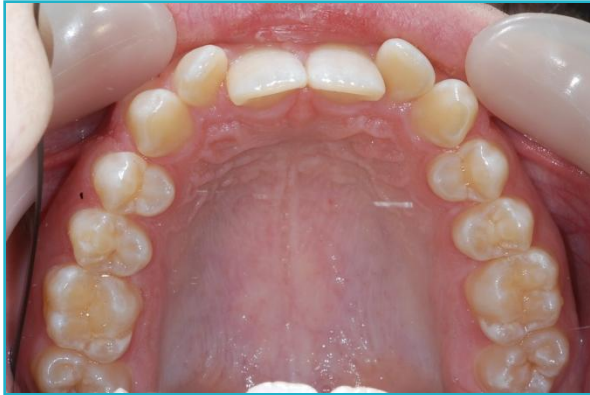

**After**

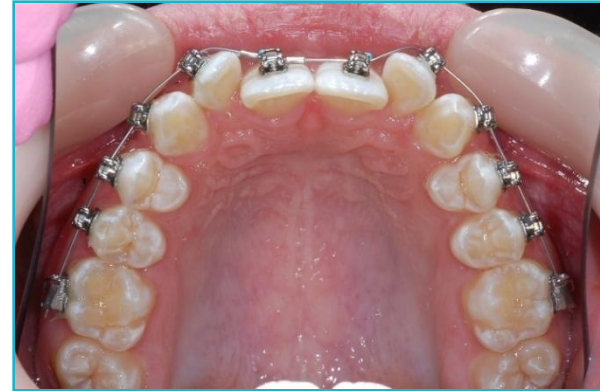

**Note the improved profile**

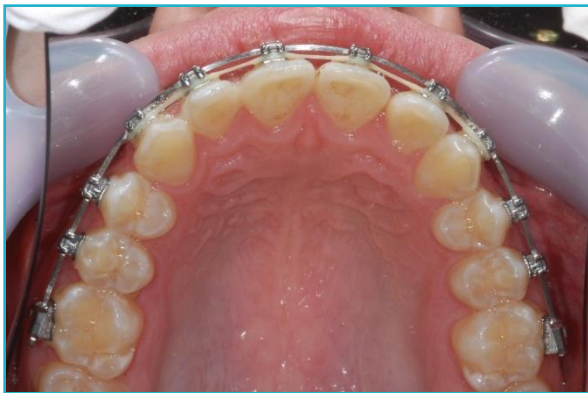## Upper arch sequence



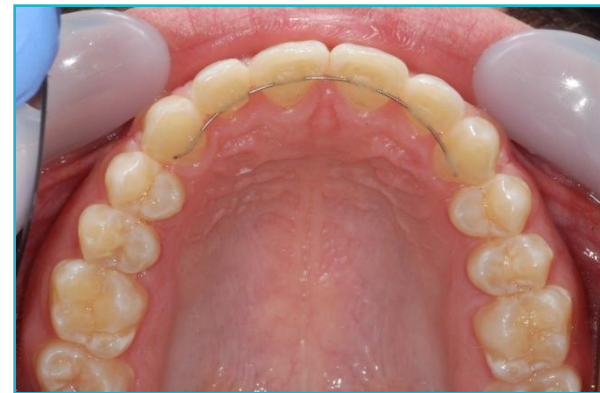1



2

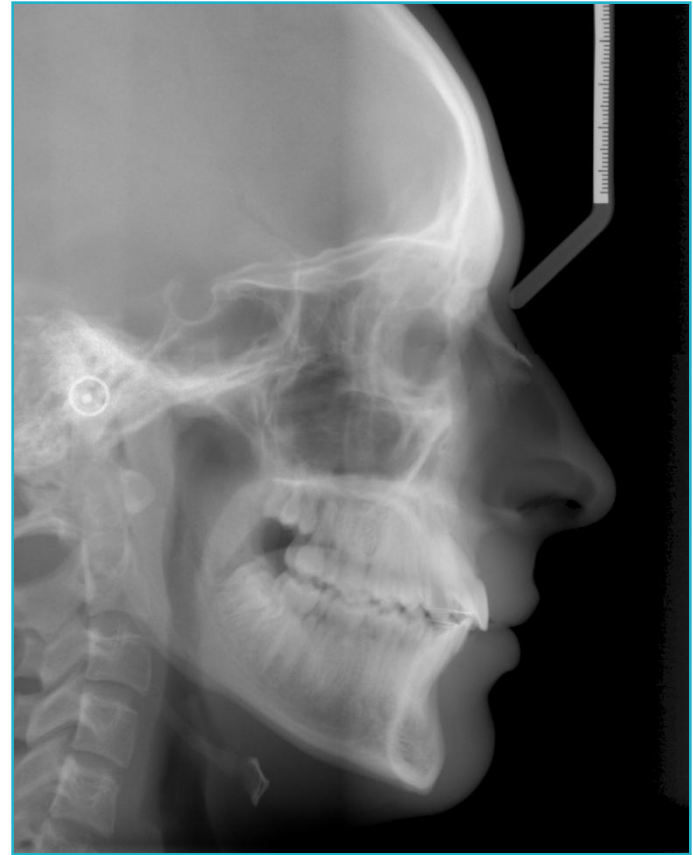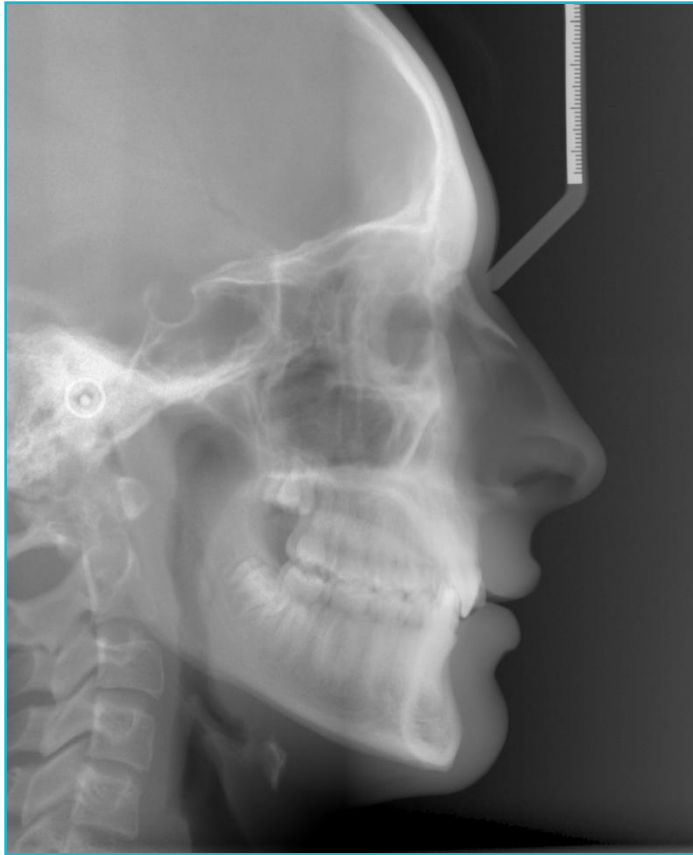


3



4

## Before and after Lateral Skull Radiographs



**Note the change in incisor inclination**



**Before**



**After**



Smile Created by



*Confidence in your smile*