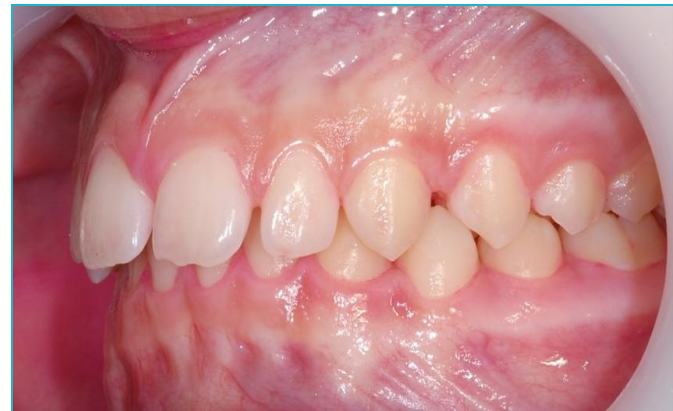
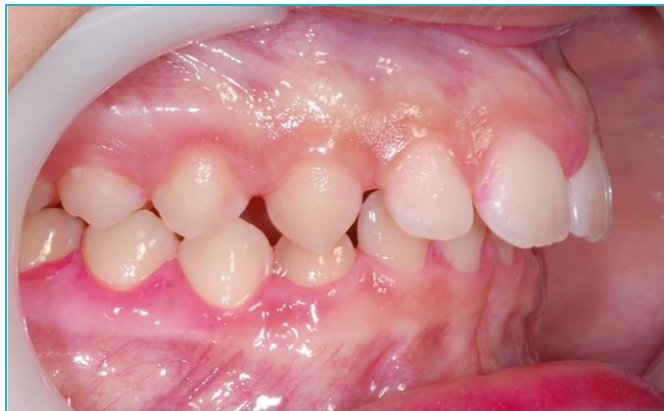
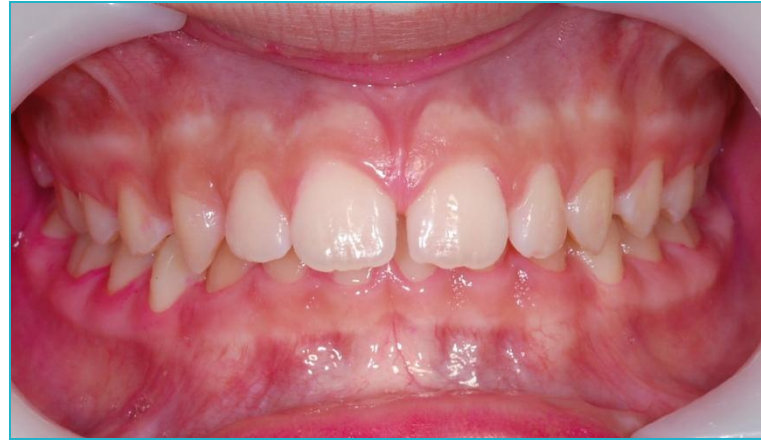
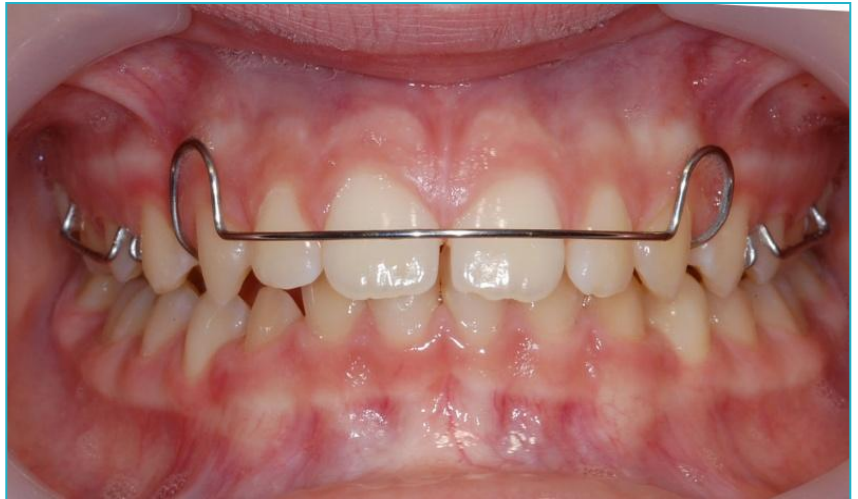
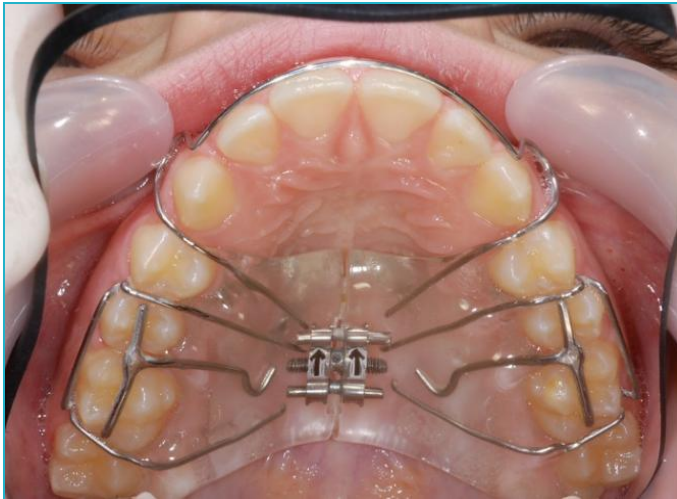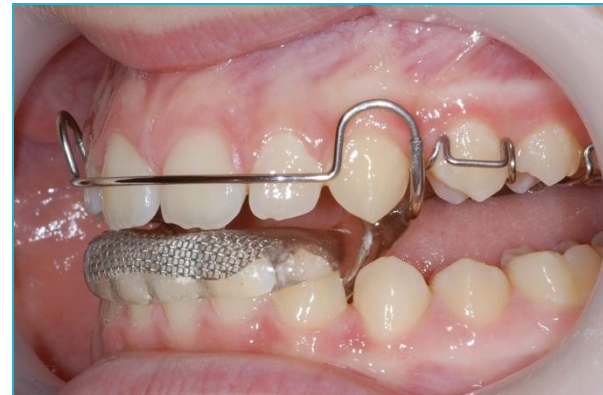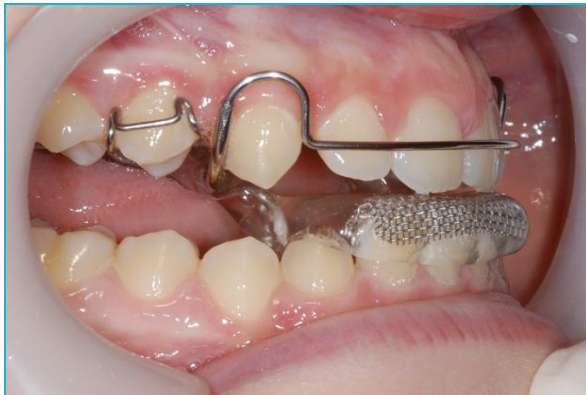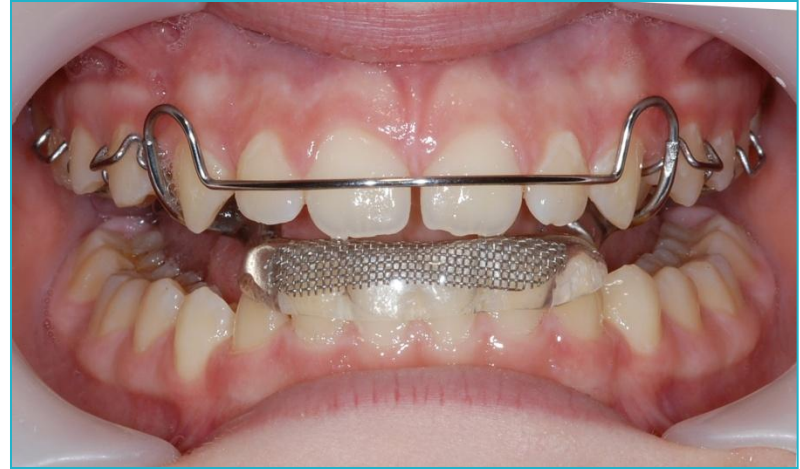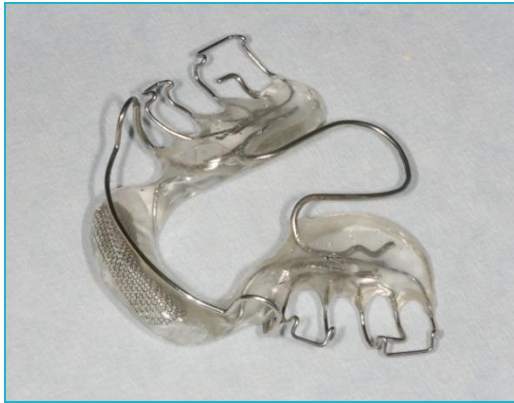At 10 years of age, James was concerned about his prominent upper teeth



Treatment began with a removable expansion plate

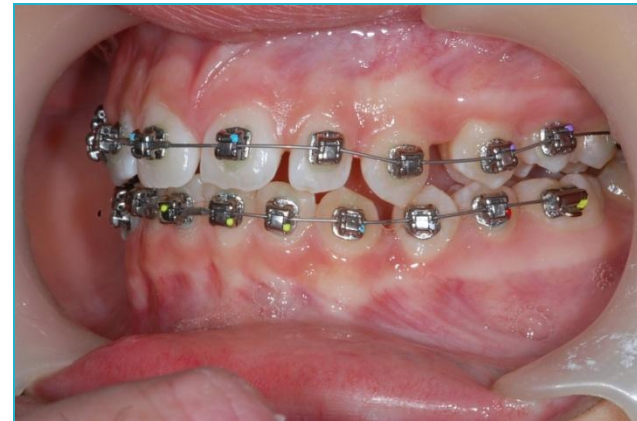
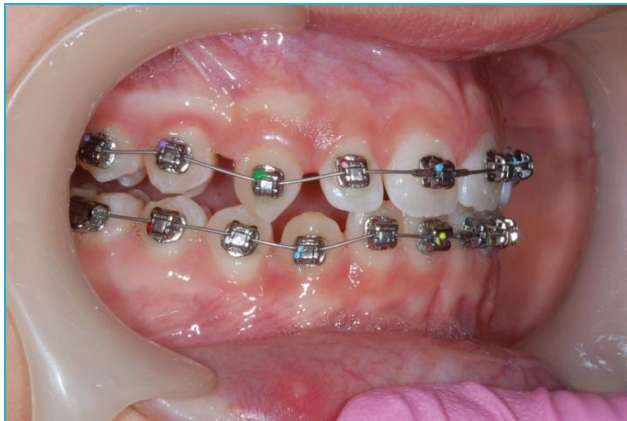
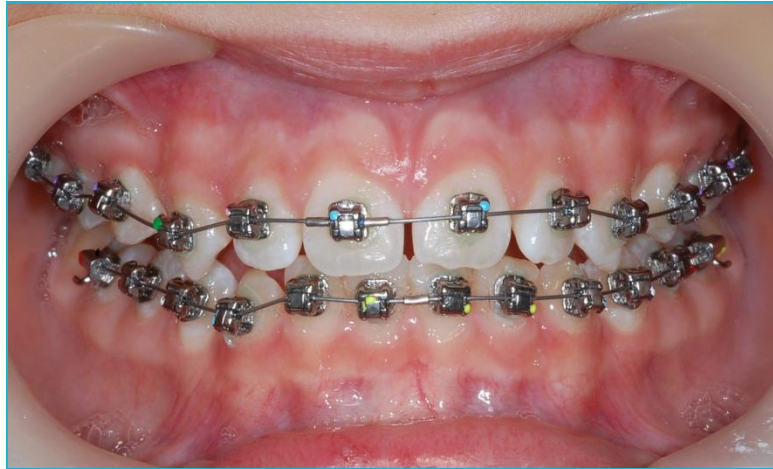Treatment continued with an Orthopaedic appliance

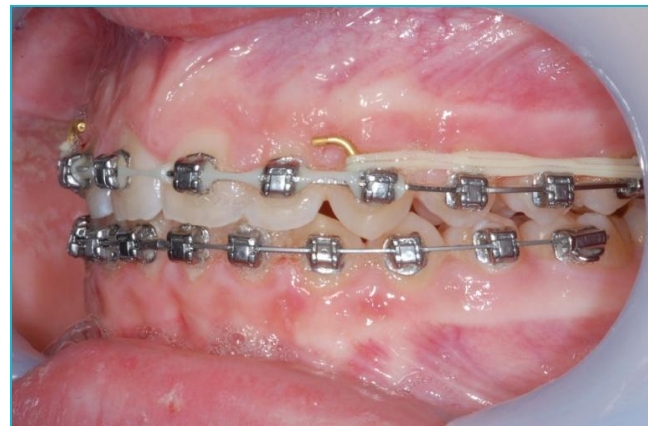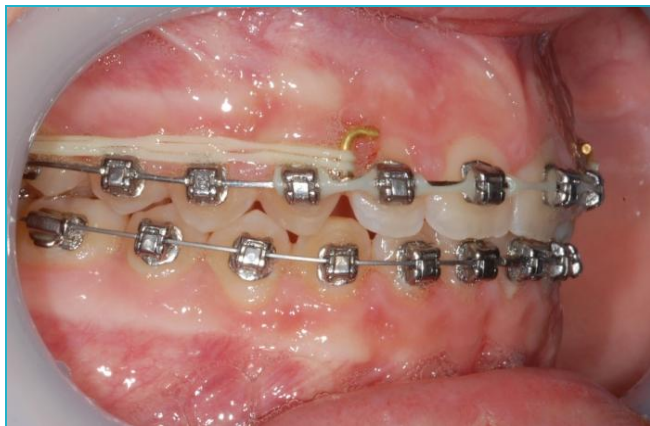

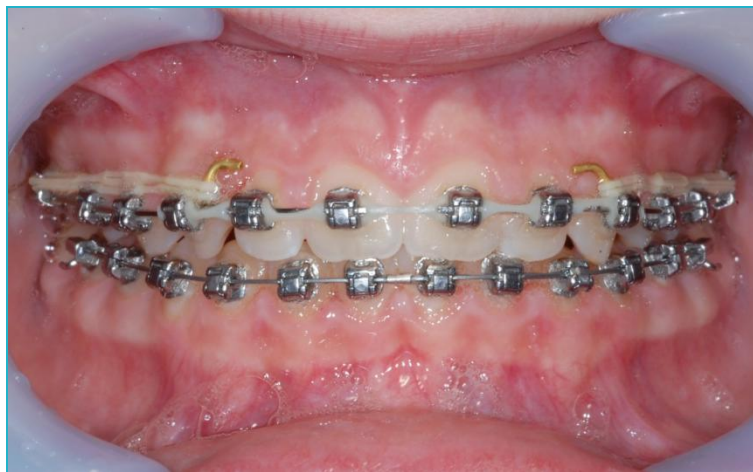
This encourages the lower jaw to grow forward and retracts the upper front teeth

And then with the fixed Damon Q brace

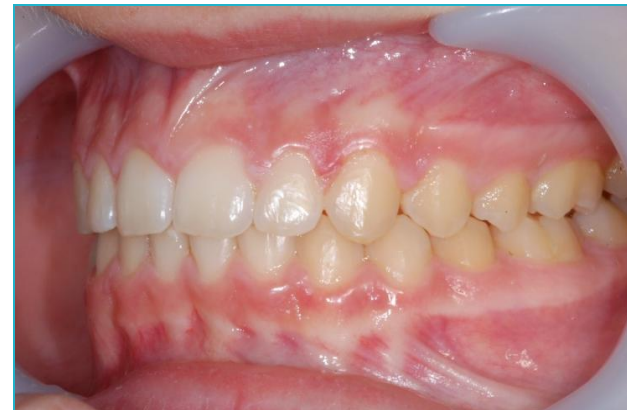
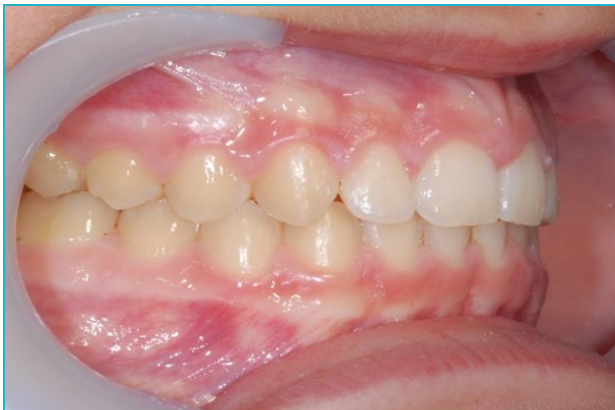
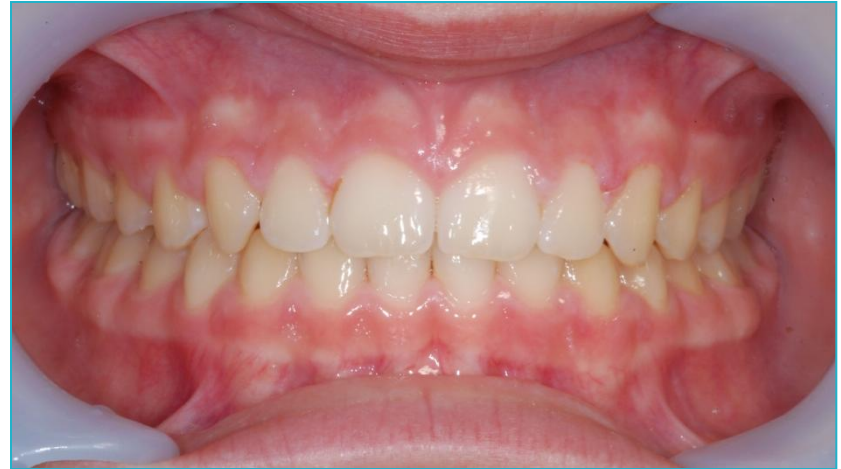After 9 months with the Damon brace



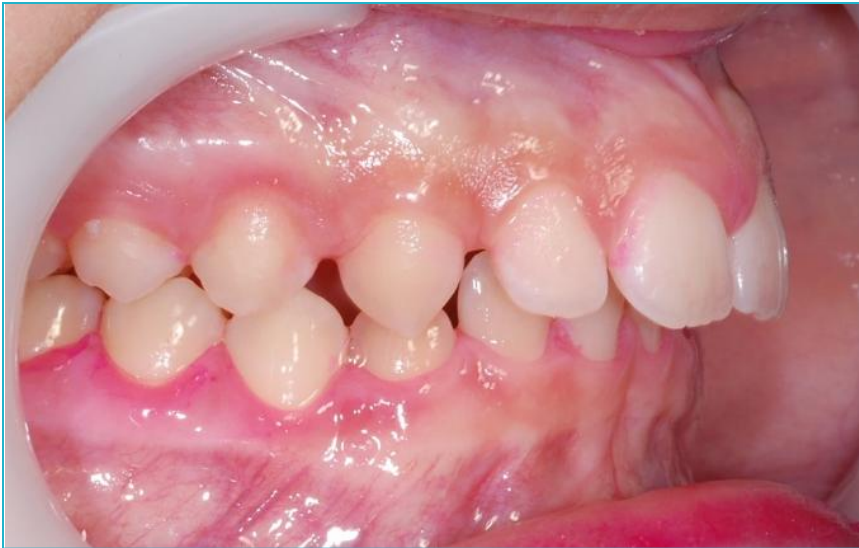

The finished result

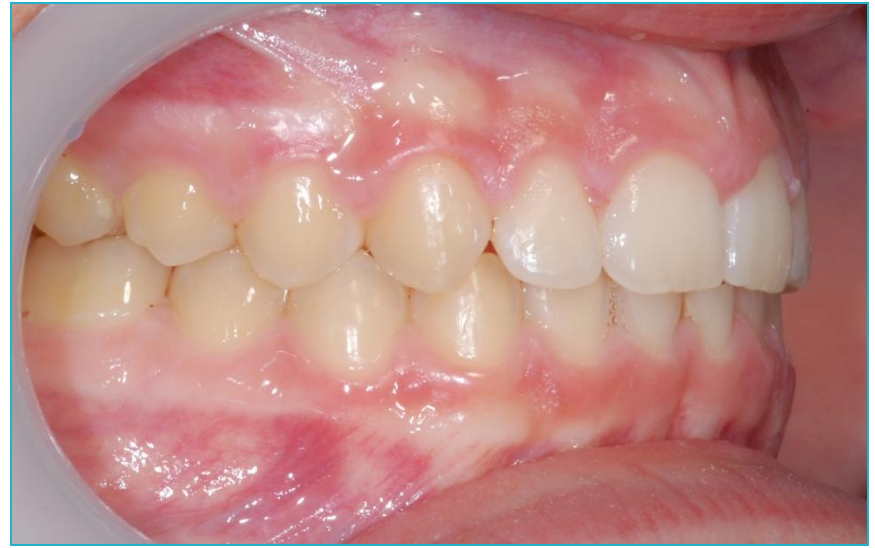

A total of 19 months treatment

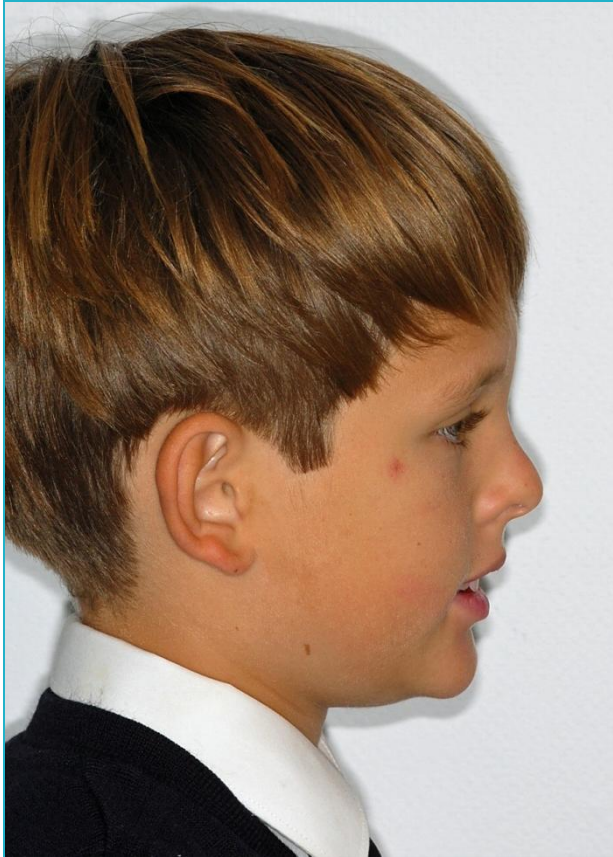Before



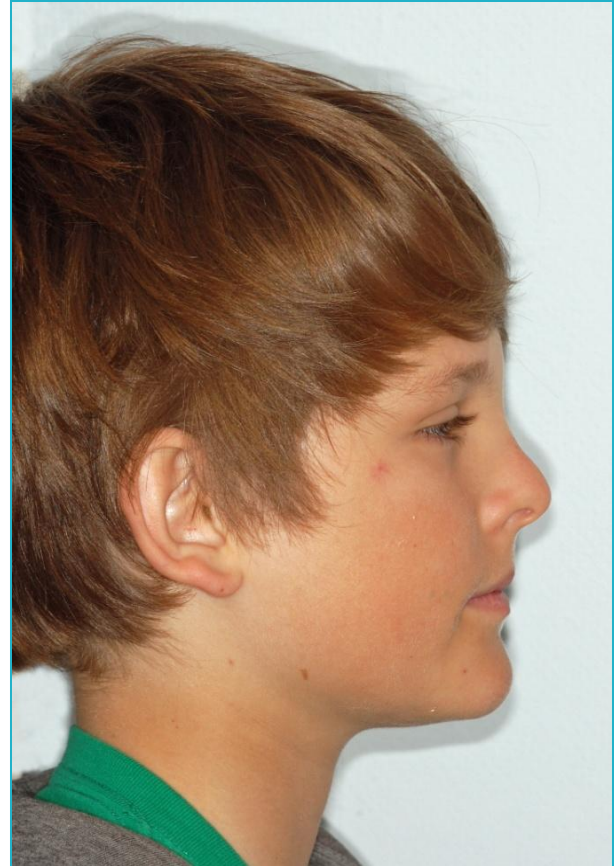
After



Profile change

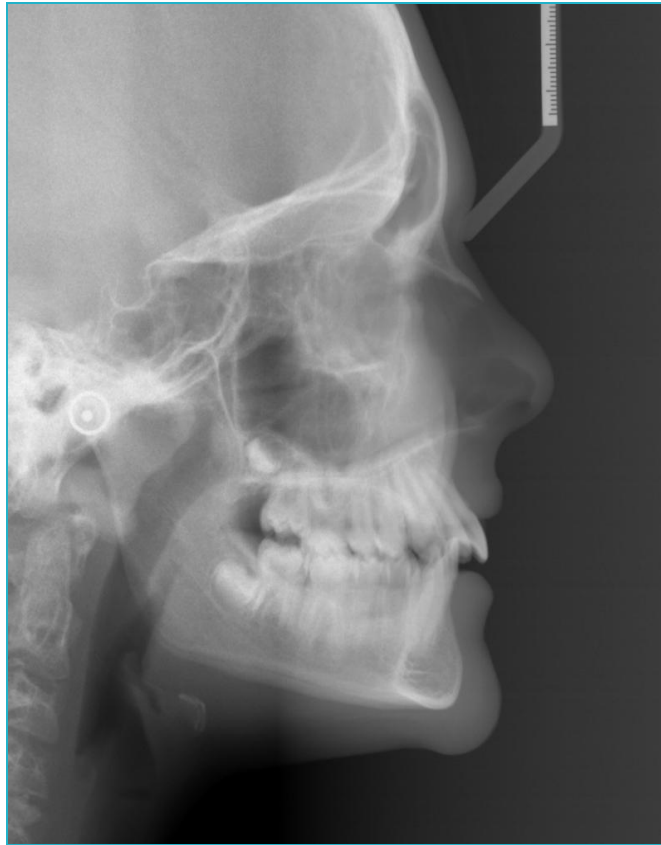

Before

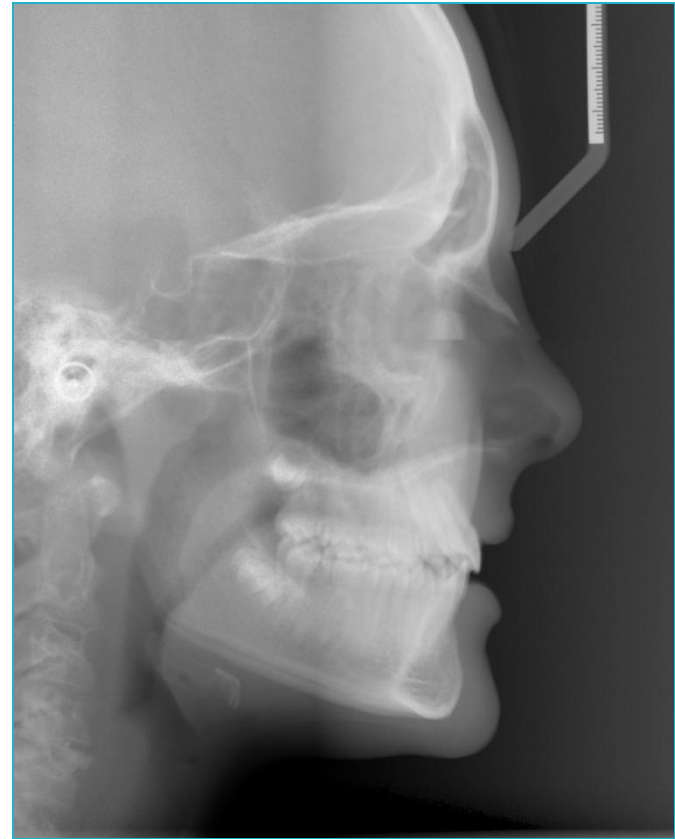

After

Before



After



Before



After



Smile Created by



Confidence in your smile