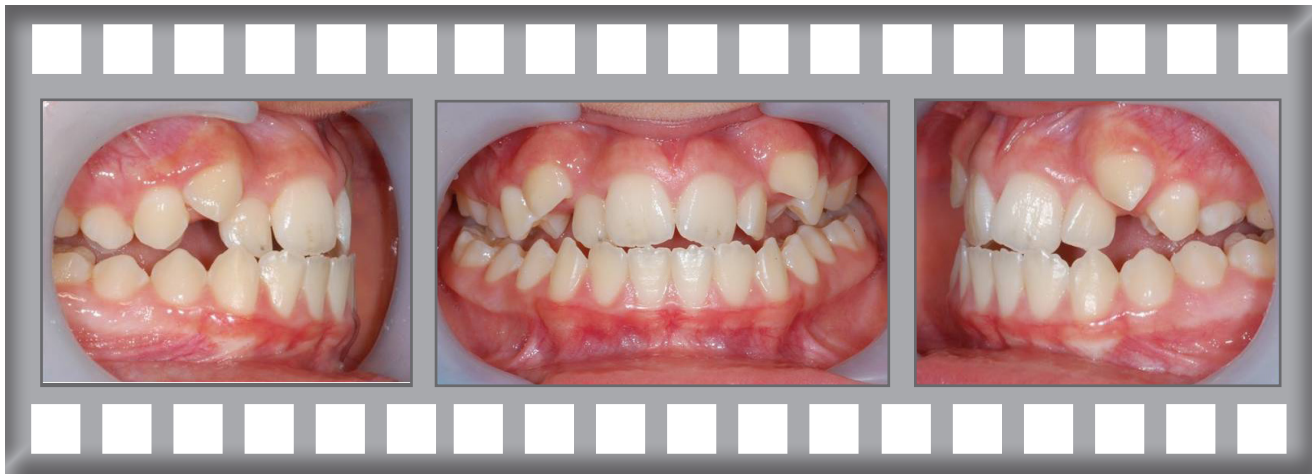

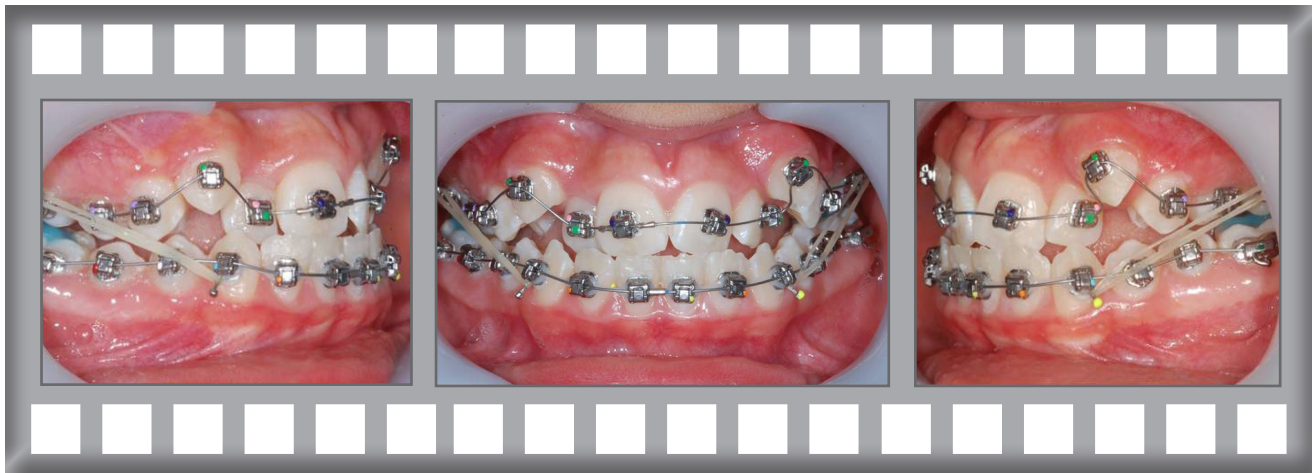## Damon Q

Christopher was concerned about his crowded upper teeth.

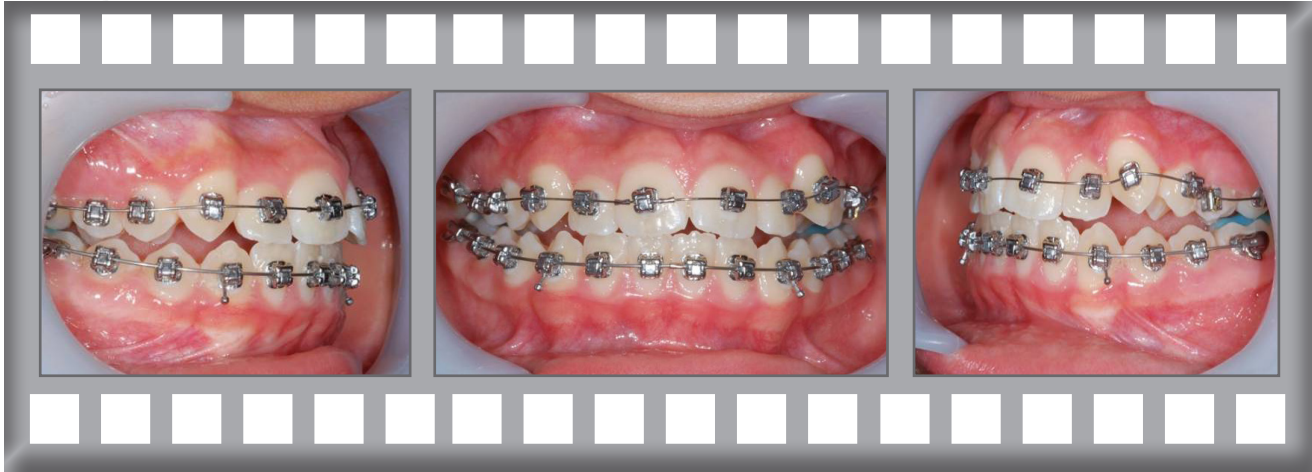
Treatment was complete after 19 months using the Damon Q system without extractions.



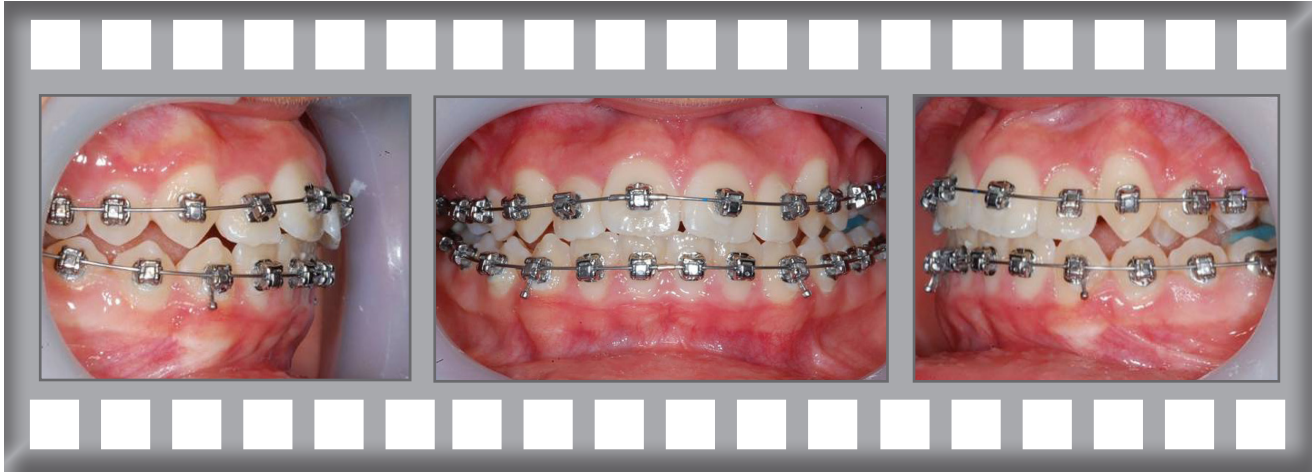Dr Horobin used Damon Q upper and lower fixed braces with no extractions.



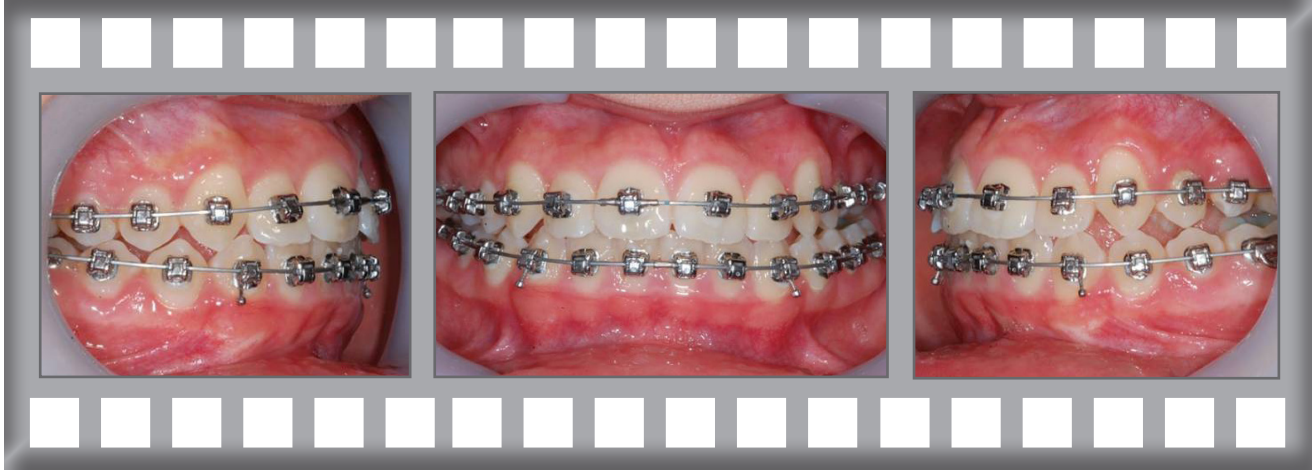Progress after 3 months.



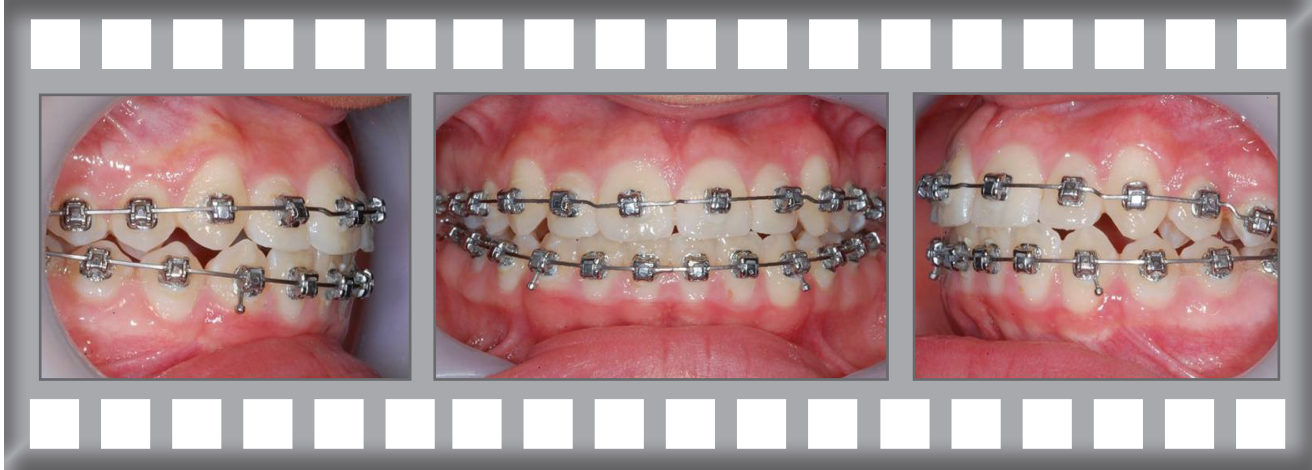
Progress after 6 months.



Progress after 10 months.



Progress after 18 months.



# Damon Q Case History

Christopher was delighted with his result.

Treatment was complete after 19 months using the Damon Q system without extractions.

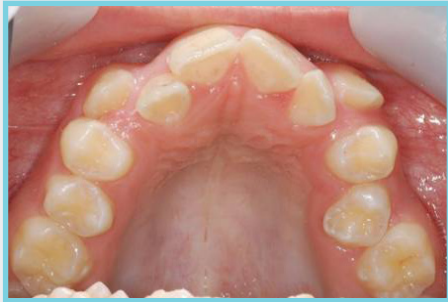

*After*

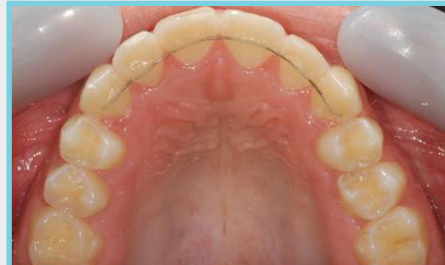

*Before*

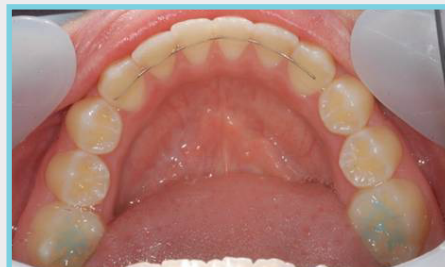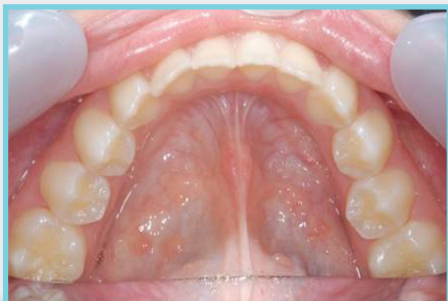BEFORE



AFTER

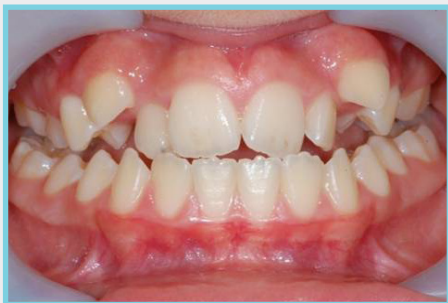

Note Fixed Retainer



Note Fixed Retainer

BEFORE



AFTER

