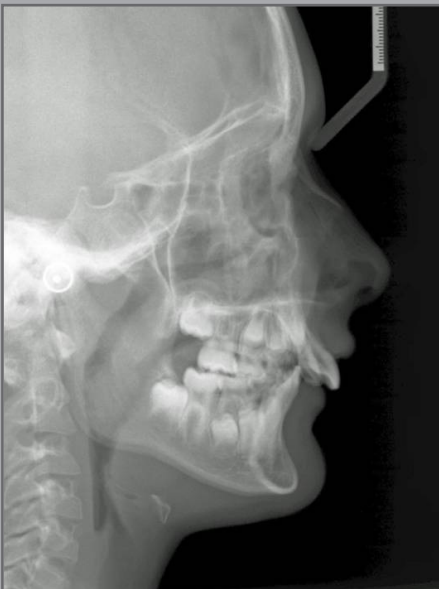
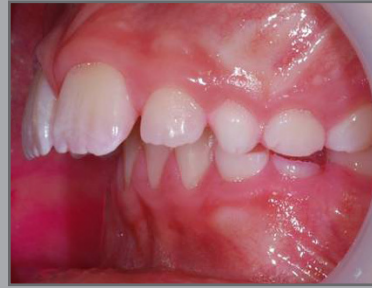
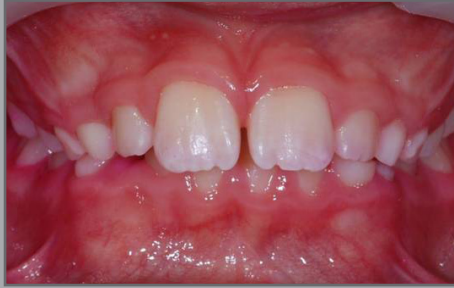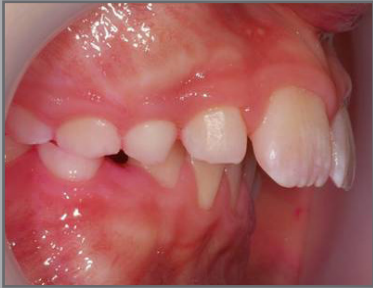Two Phase Treatment

Charles presented at 9 years, concerned about his prominent front teeth. The upper teeth were proclined and prominent. Orthodontic treatment was complete after 3 years using removable and fixed appliances, without extractions.

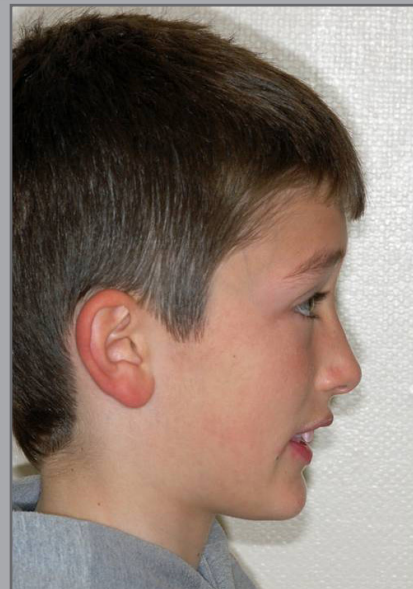

Charles

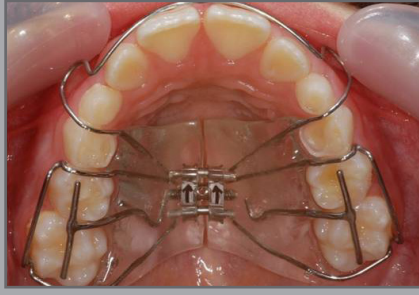
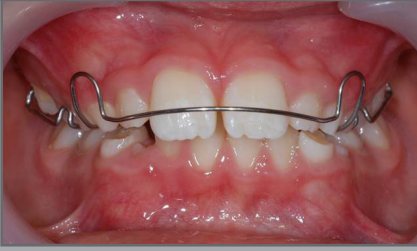

The upper teeth
were proclined
and prominent

Overjet increased
to 11mm.



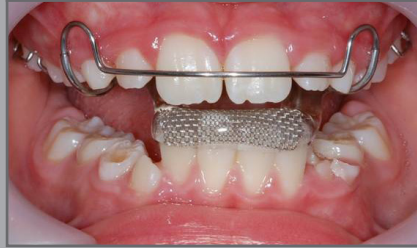Stage One



Stage 1
Removable expansion
plate.

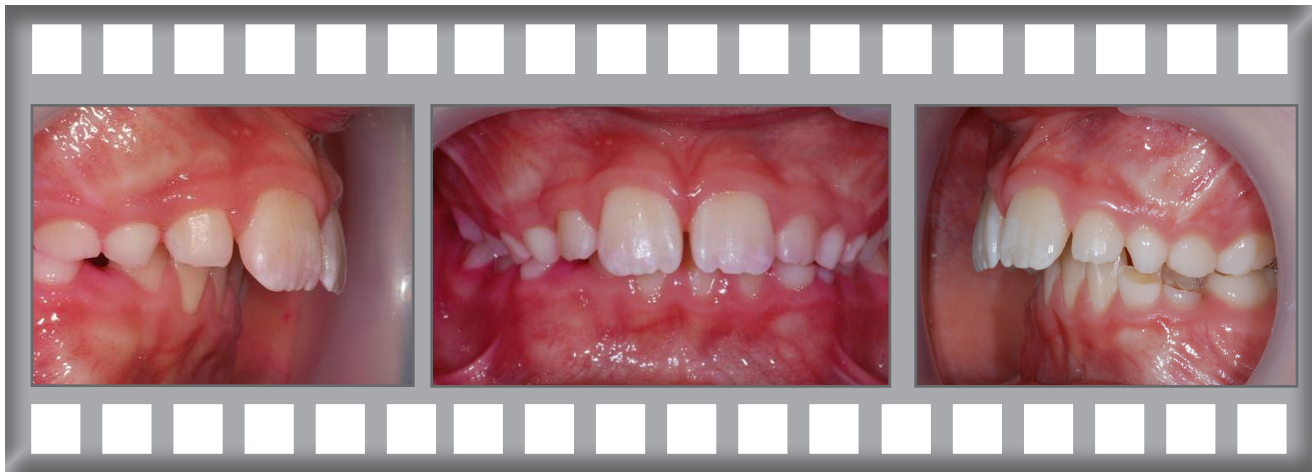In the mixed dentition.

Stage Two

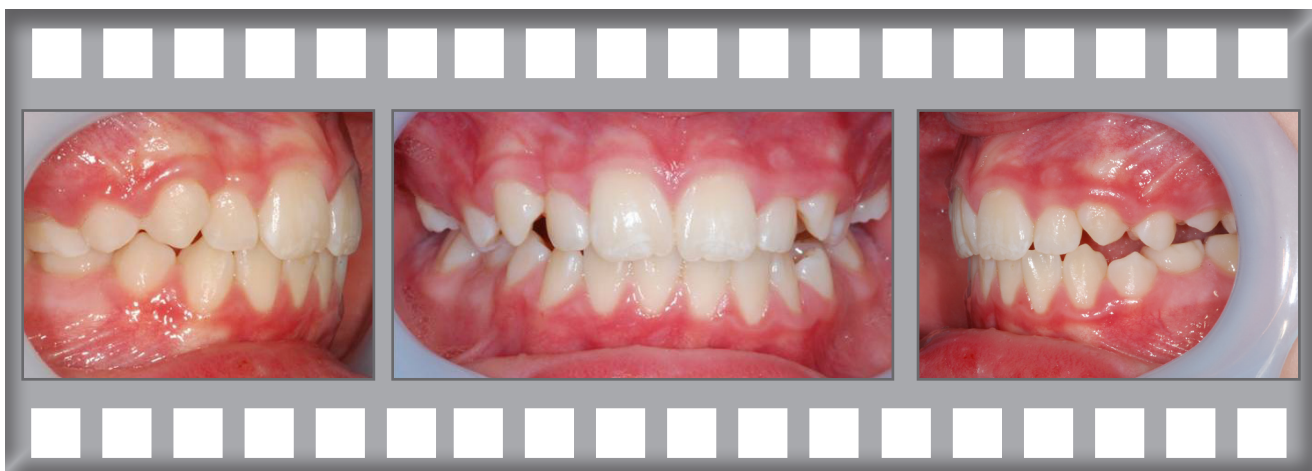

Stage 2
Orthopaedic appliance.
This brace held the
lower jaw forwards,
encouraging it to grow
forwards.

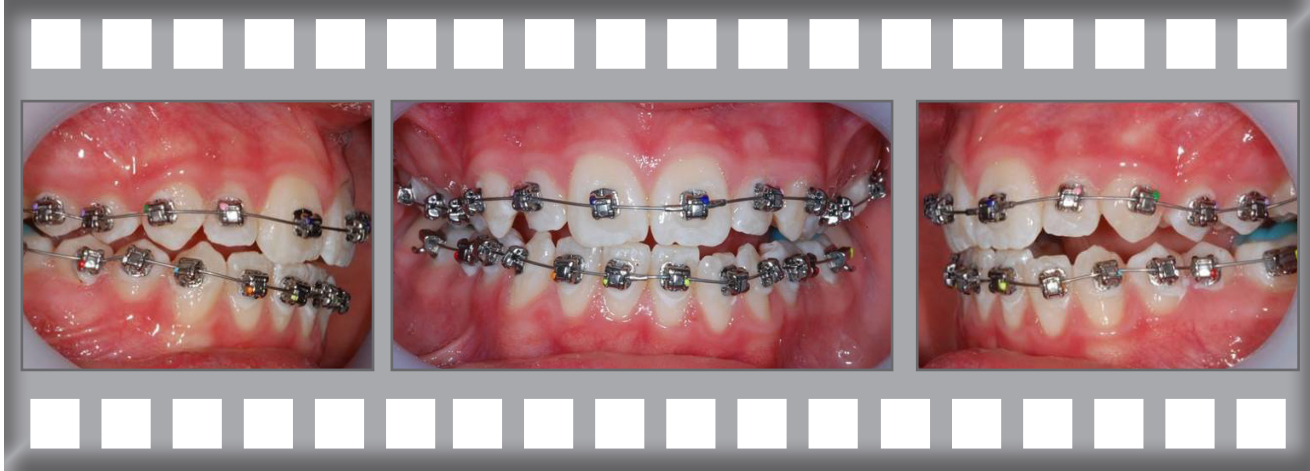Before stage 2.



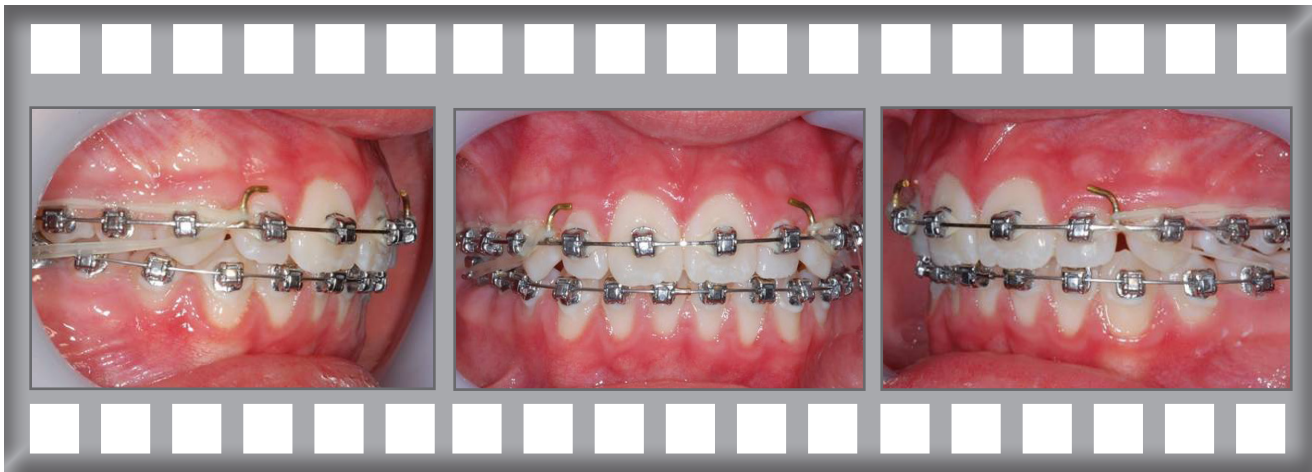
After stage 2.



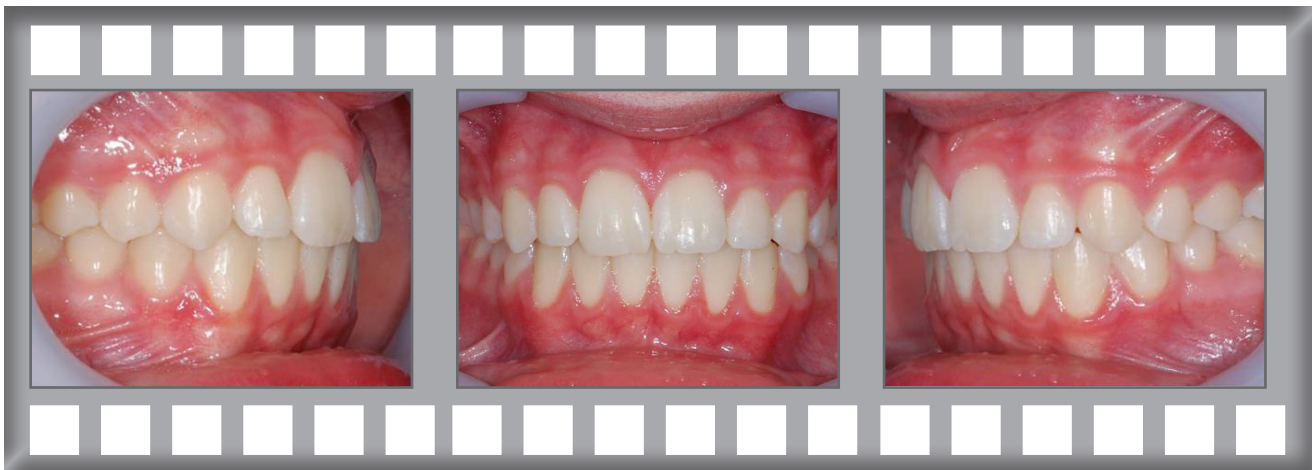Stage 3 - Damon Q fixed appliance to finish in the adult dentition



After 7 months with the Damon Q brace.



The finished result.





Before



After

Charles was delighted with his result.

Treatment was complete using Orthopaedic appliances and Damon Q without extractions

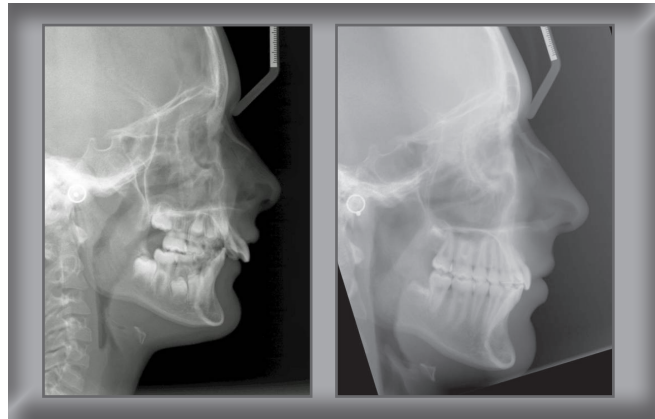
Two Phase Treatment:-

Mixed dentition – 12 months with removables

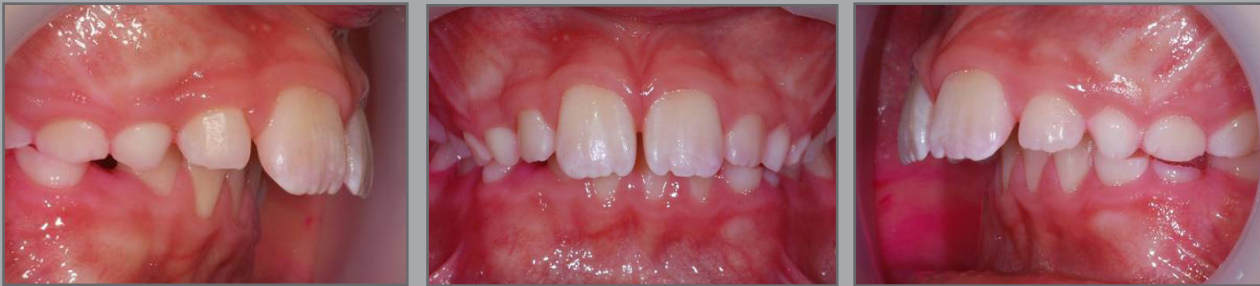-Gap -

Adult dentition – 11 months with Damon Q fixed

Total time – 3 years 5 months



Before treatment.



After orthodontic treatment.

