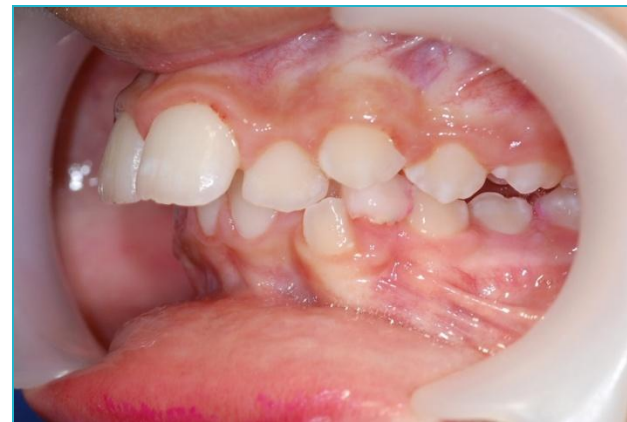
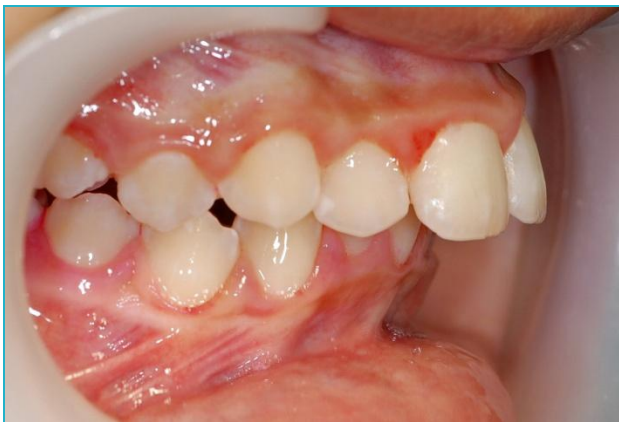
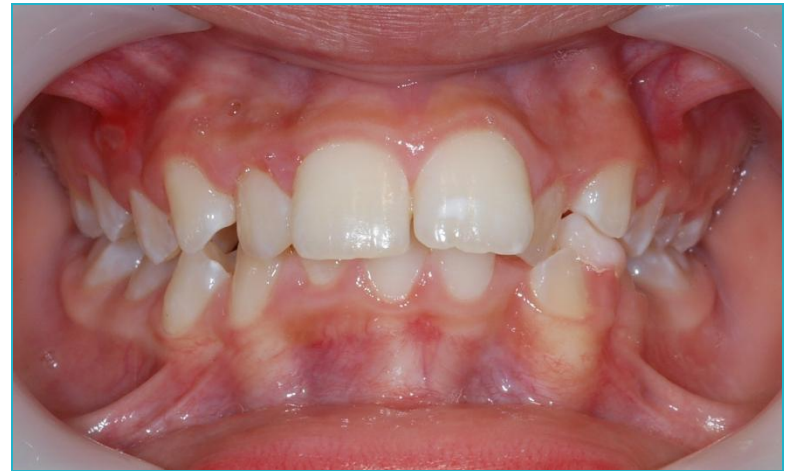
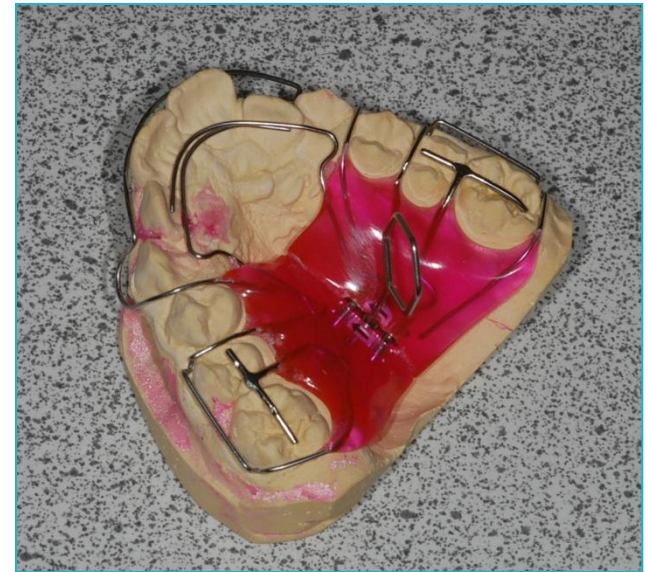
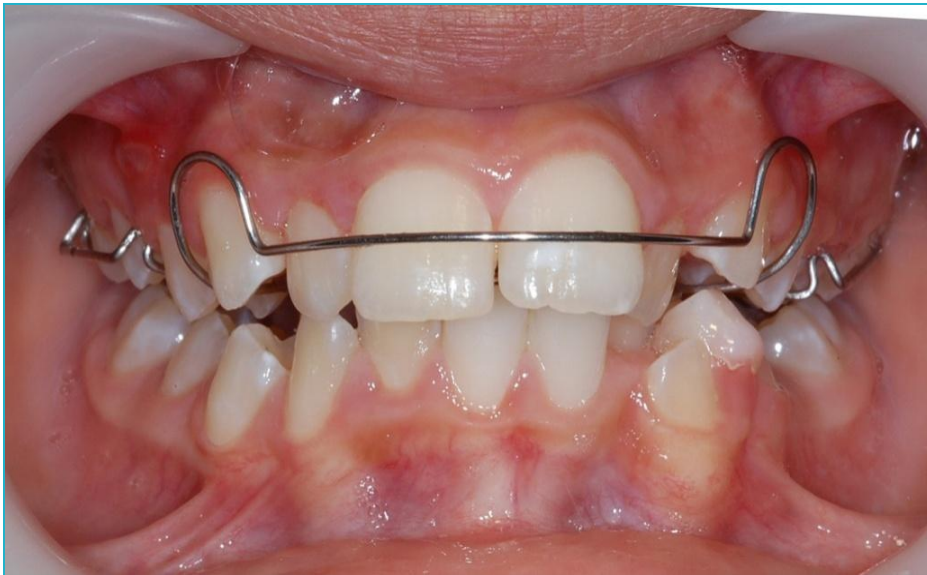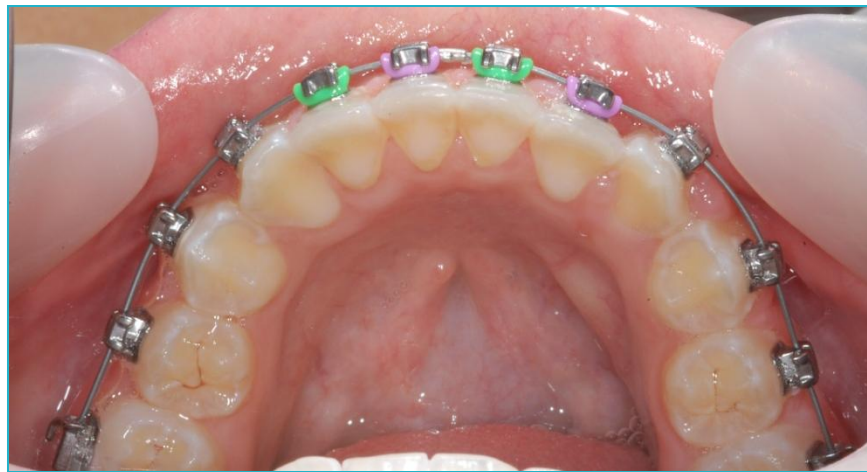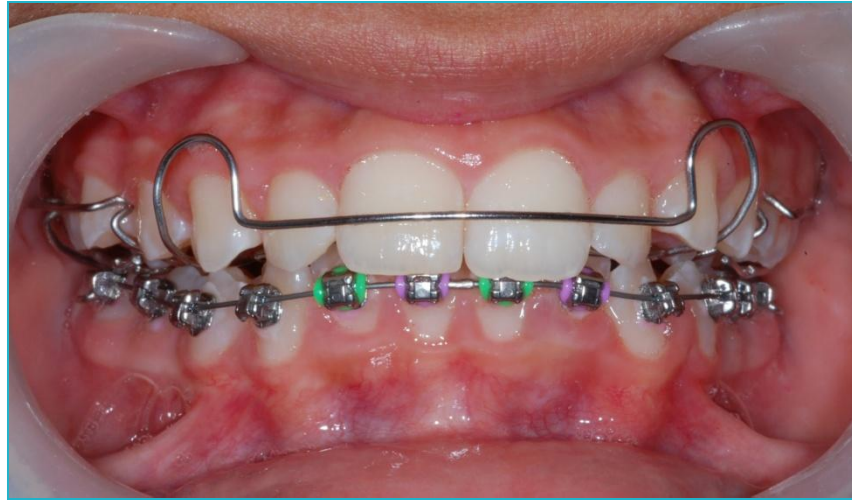At 10 years of age, Alexandra was concerned about her prominent upper teeth.



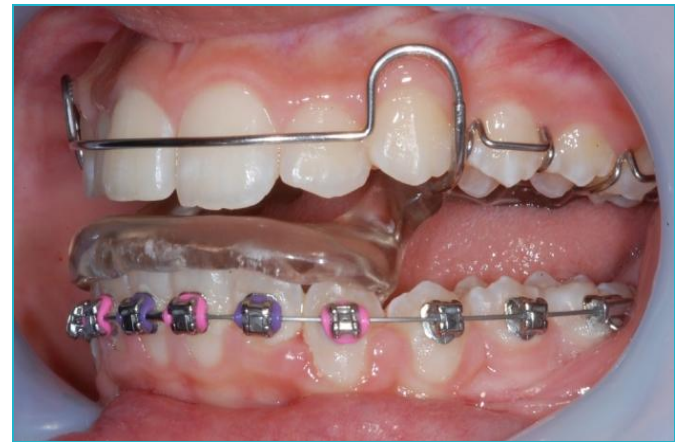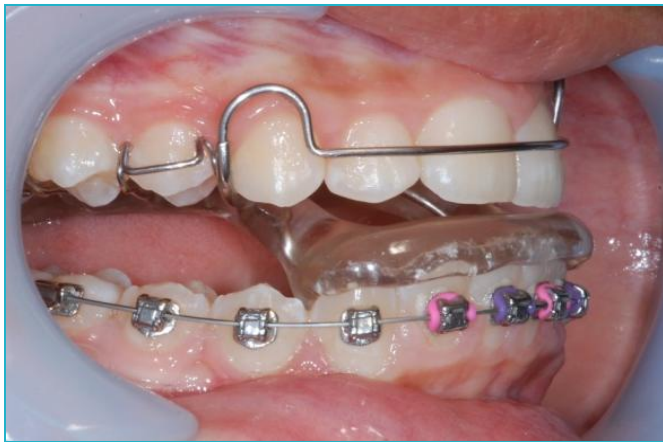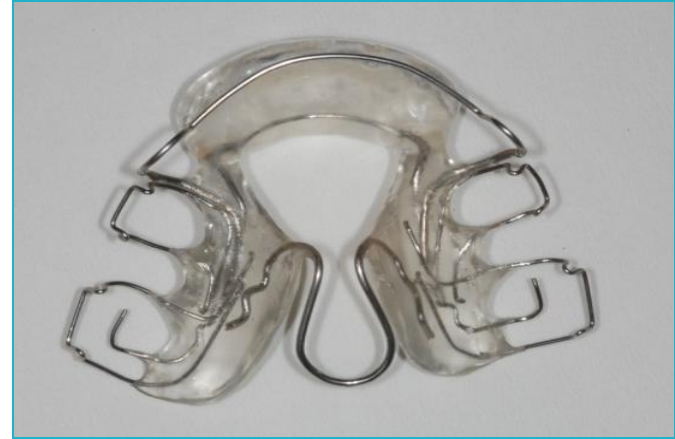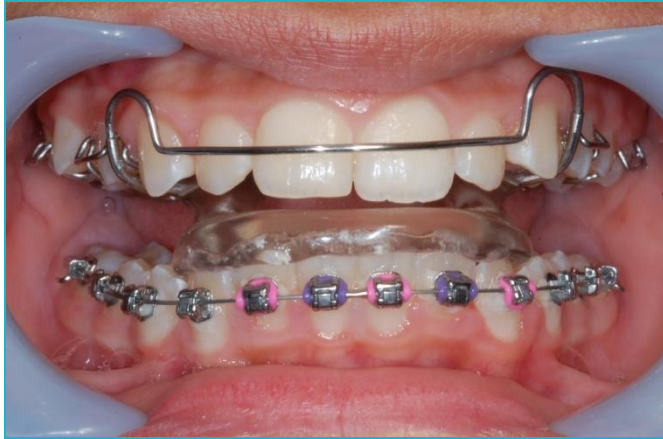Treatment began with a removable expansion plate



A lower fixed brace was added

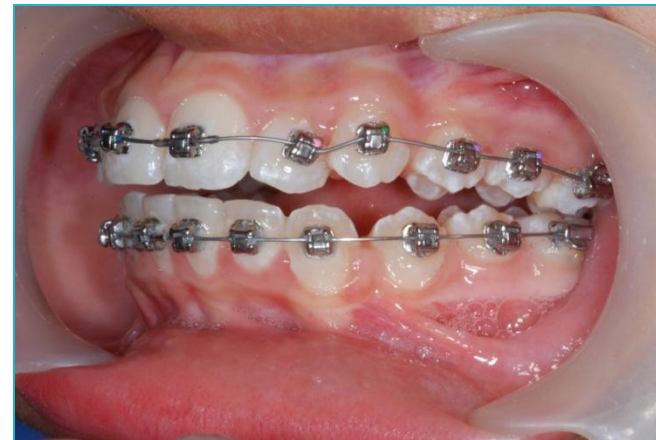
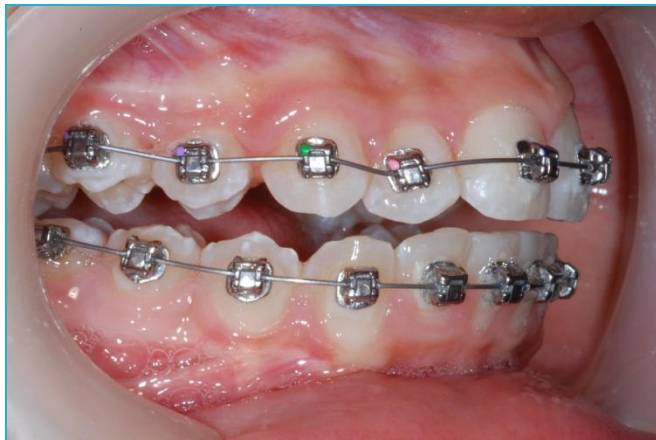
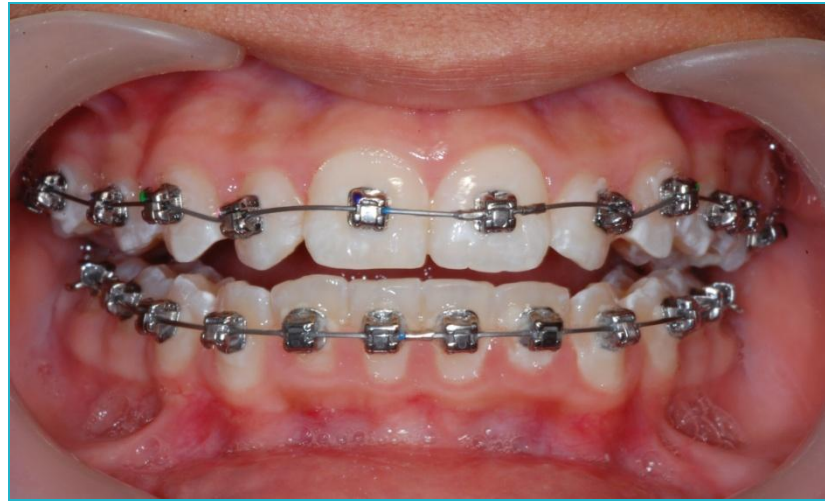Treatment continued with an Orthopaedic appliance

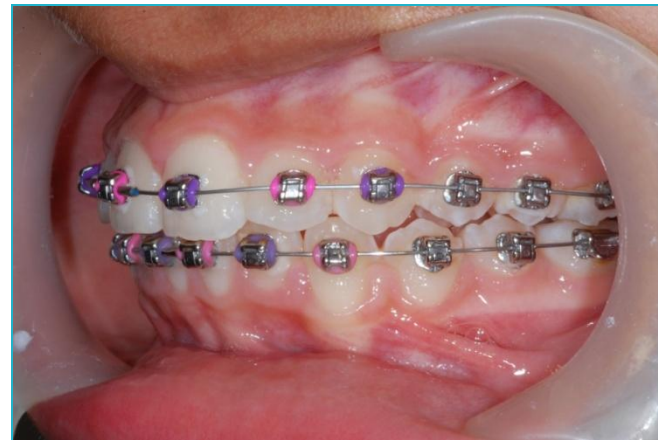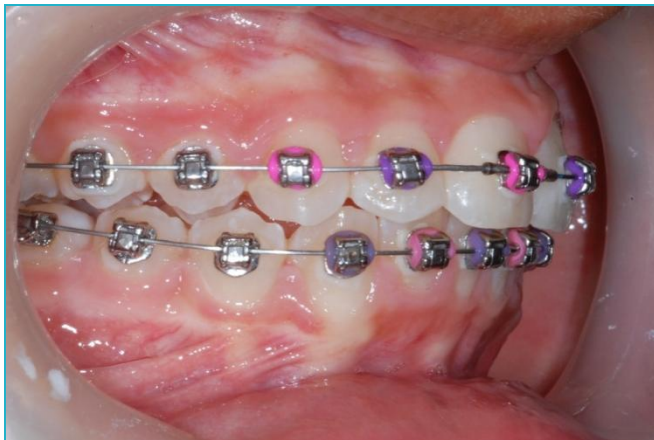

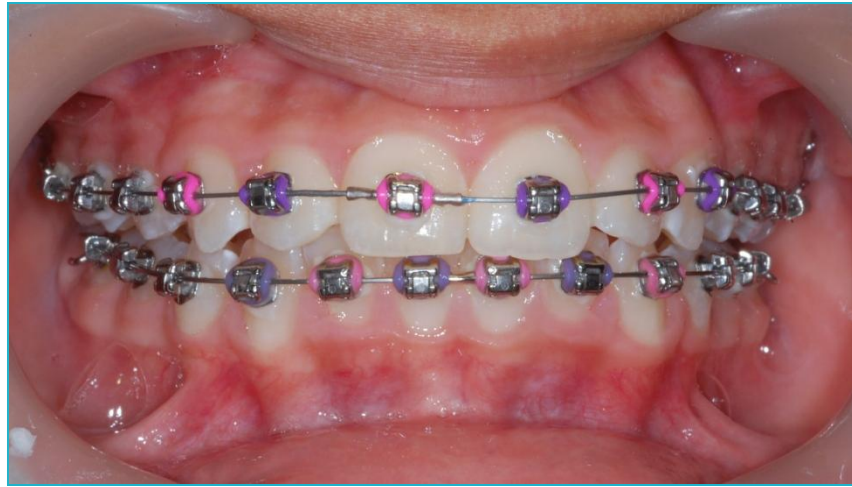
This encourages the lower jaw to grow forward and retracts the upper front teeth

And then with the fixed Damon Q brace

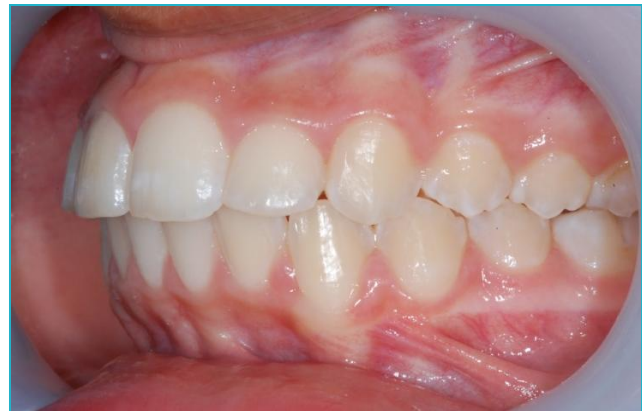
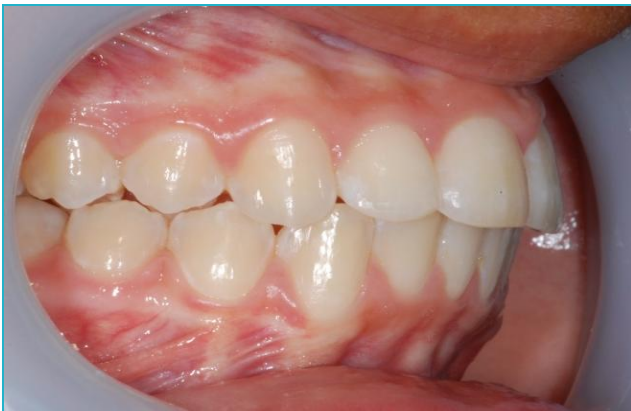
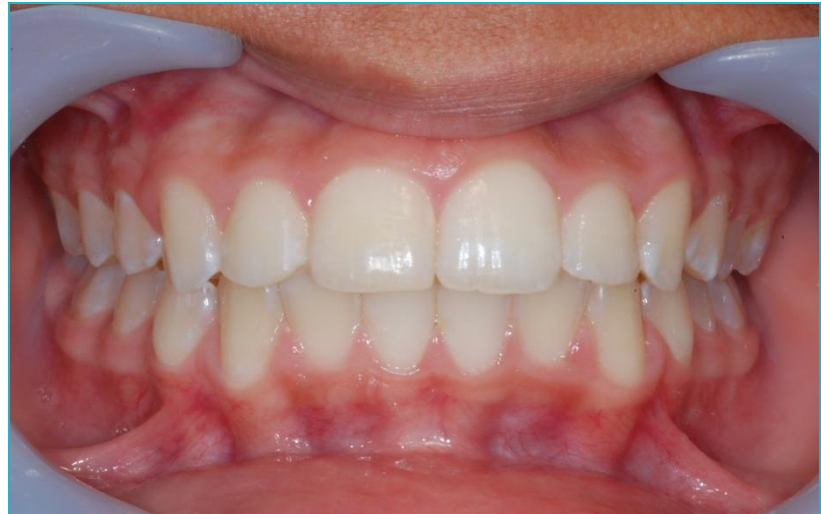After 2 months with the Damon brace



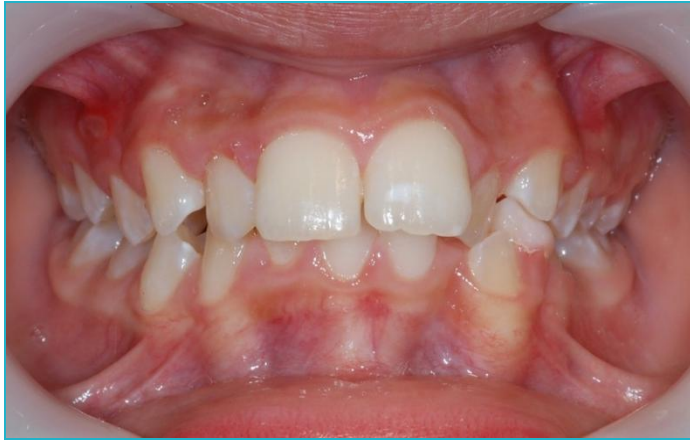

The finished result

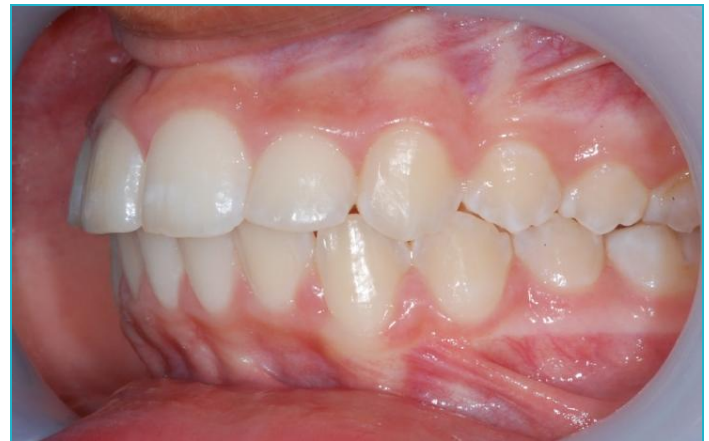
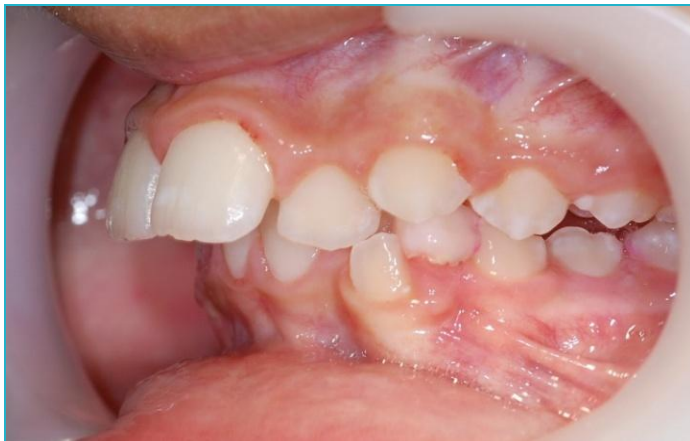
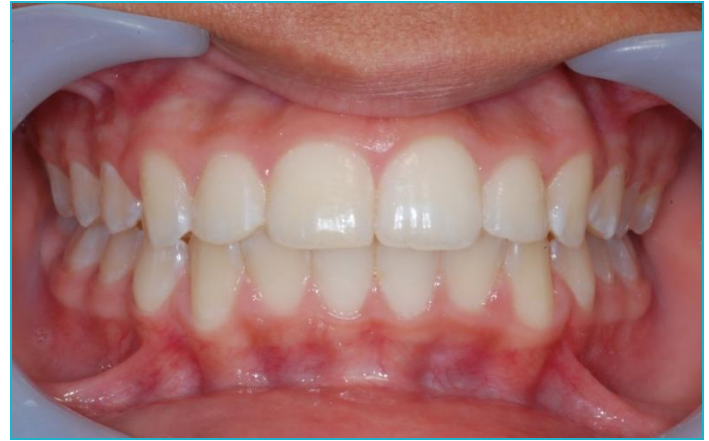A total of 19 months treatment

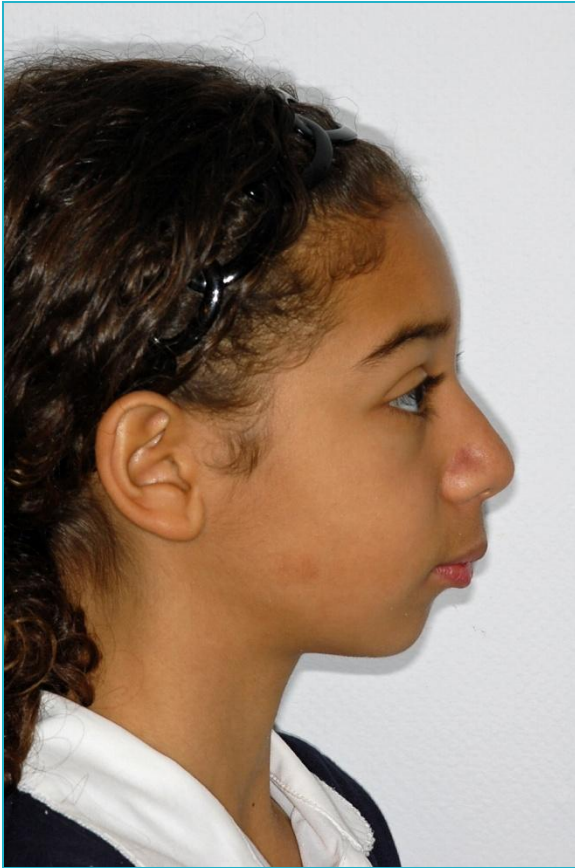Before



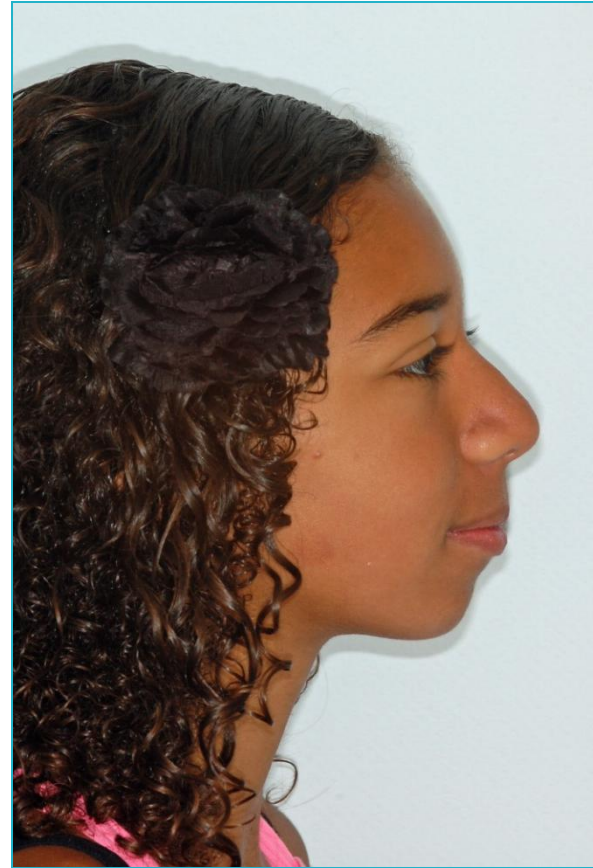After



Profile change

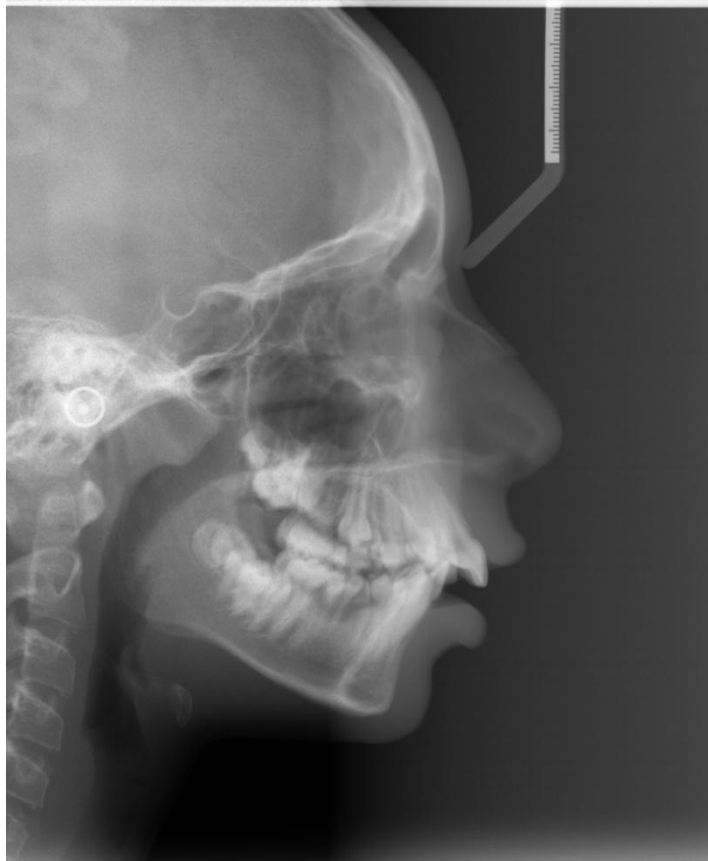

Before

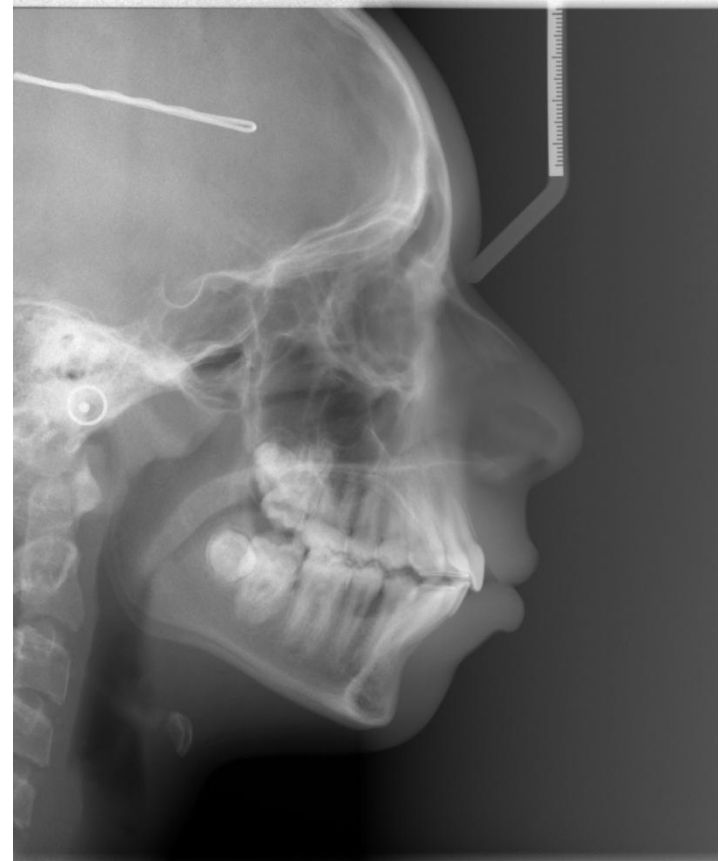


After

Before



After



Before



After



Smile Created By



Confidence in your smile