

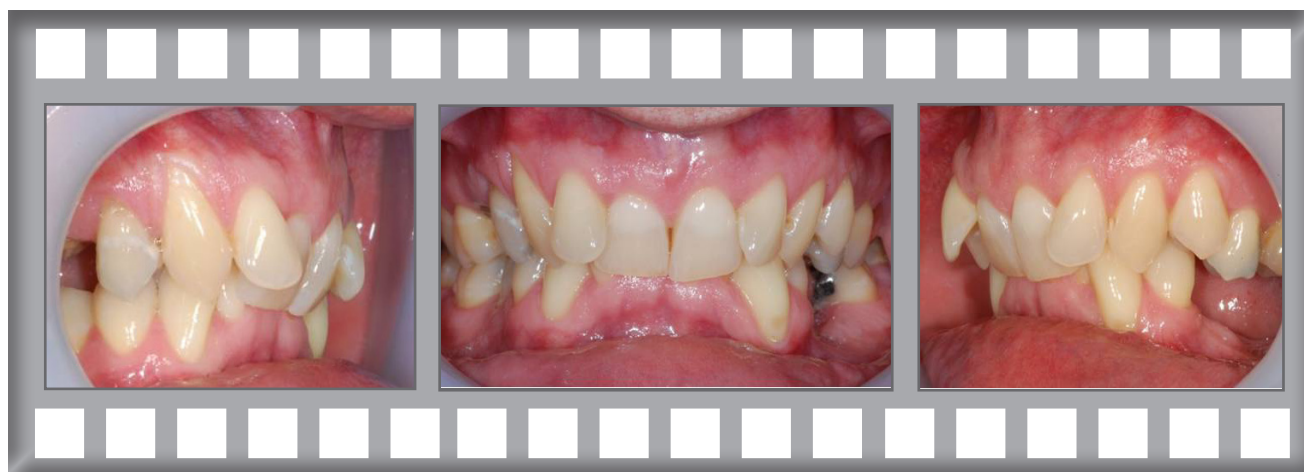Damon Clear

At 41 Steve was concerned about his irregular front teeth.

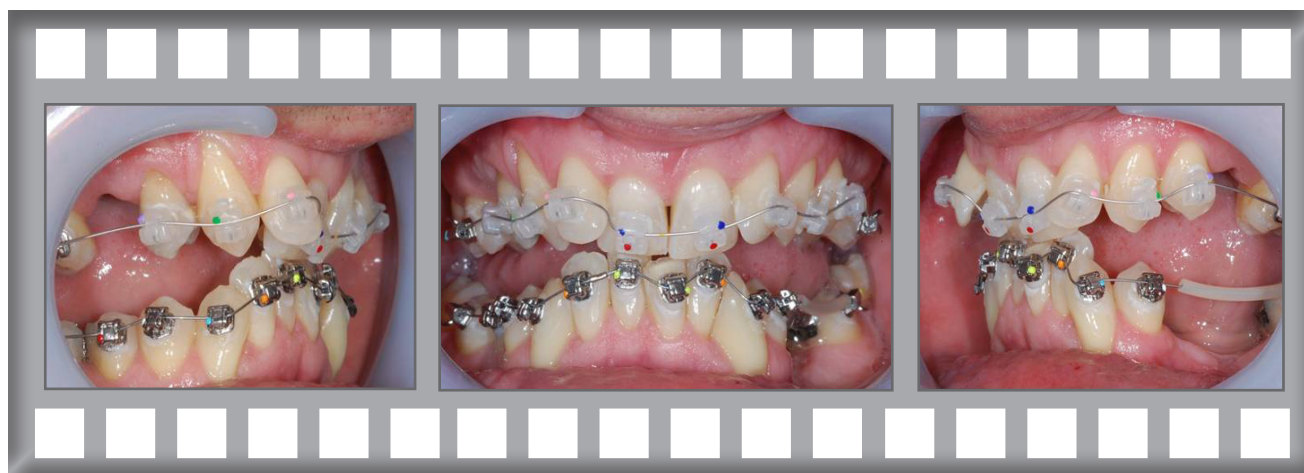Treatment was complete after 21 months using the Damon Clear system.



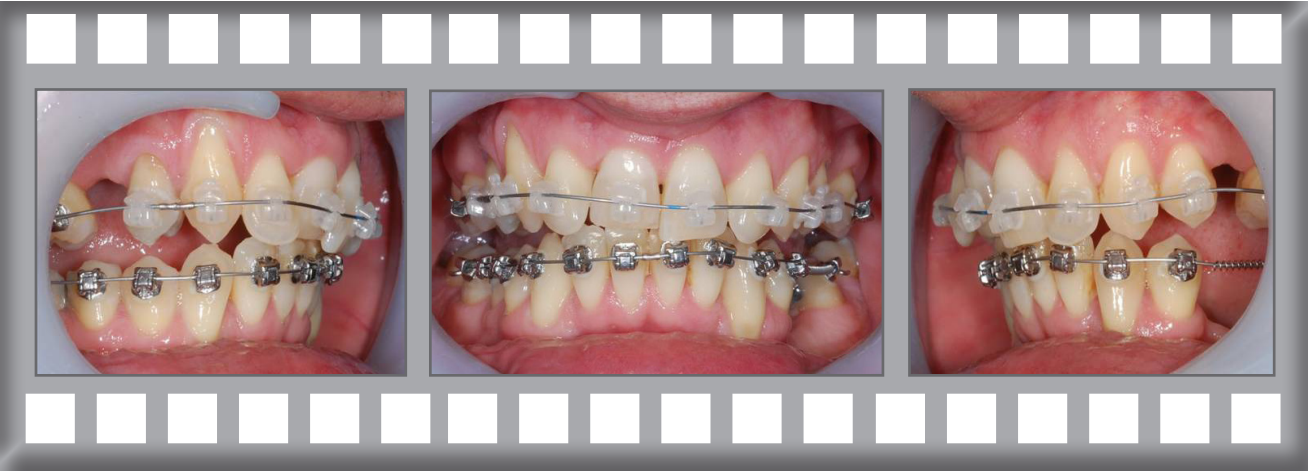Steve



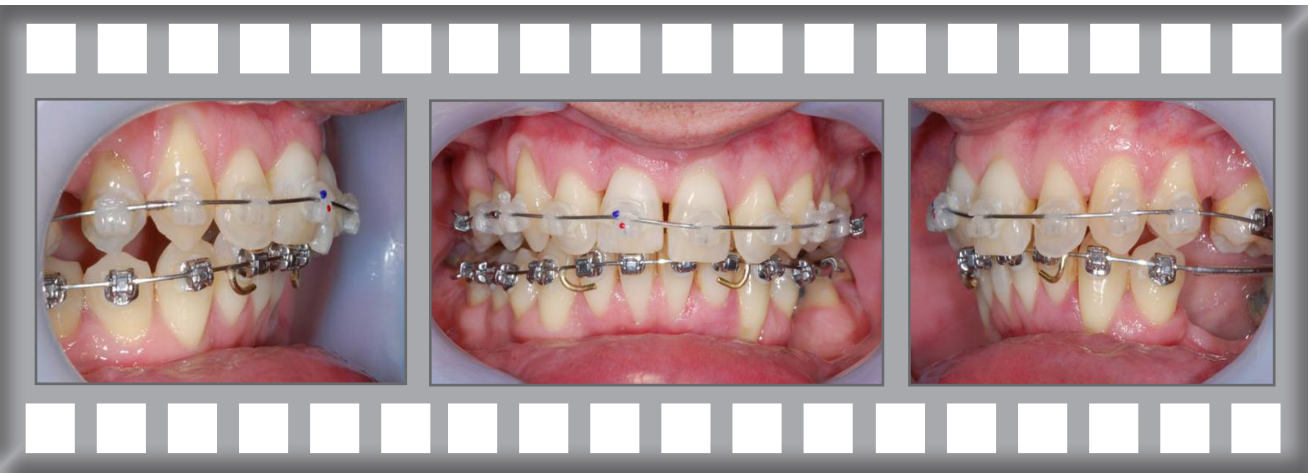
Dr Horobin used Damon Clear upper and lower fixed braces.



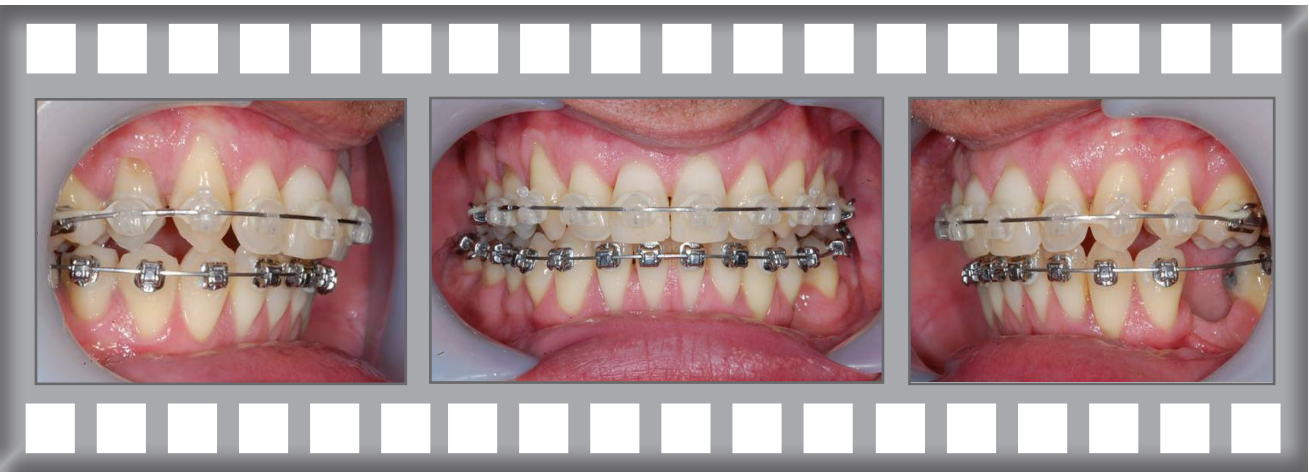Progress after 4 months.



Progress after 8 months.



Progress after 21 months.



Damon Clear Case History



Before

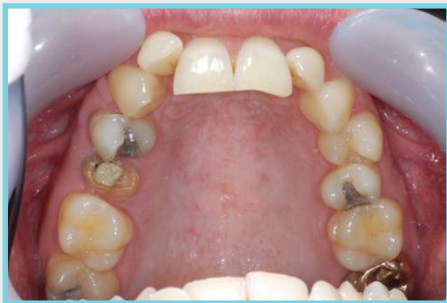

After

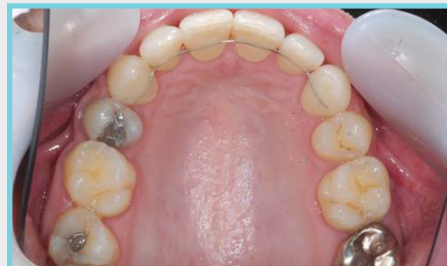Steve was delighted with his result.

Treatment was complete after 21 months using the Damon Clear system.

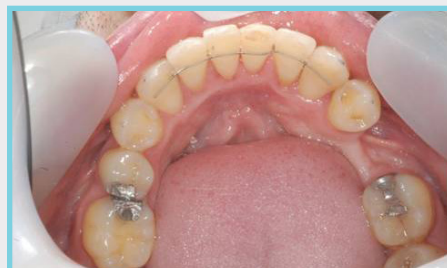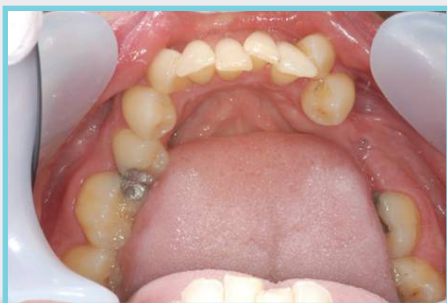BEFORE



AFTER

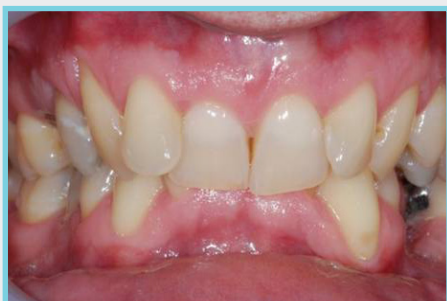

Note Fixed Retainer



Note Fixed Retainer

BEFORE



AFTER

