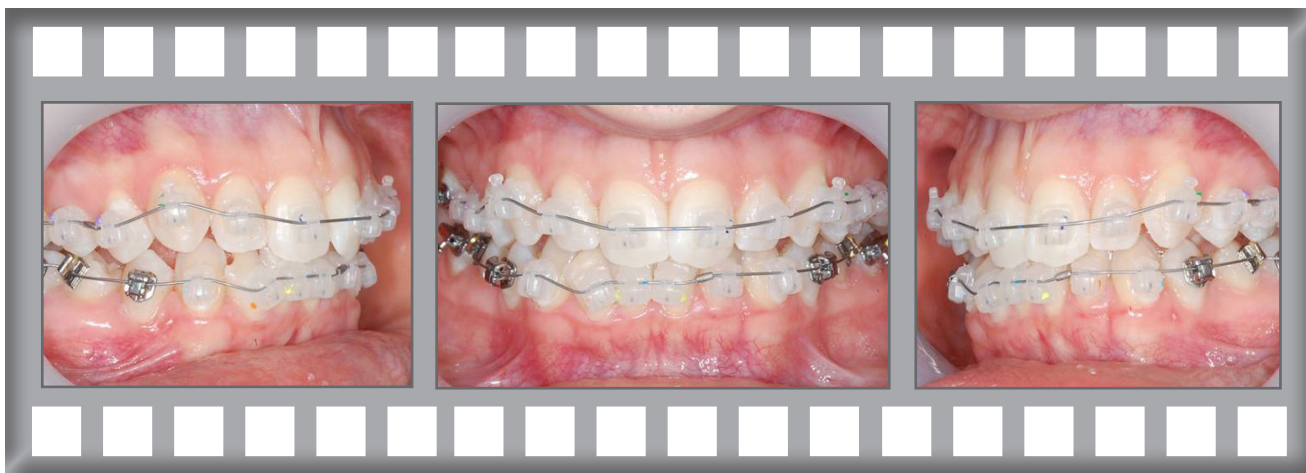


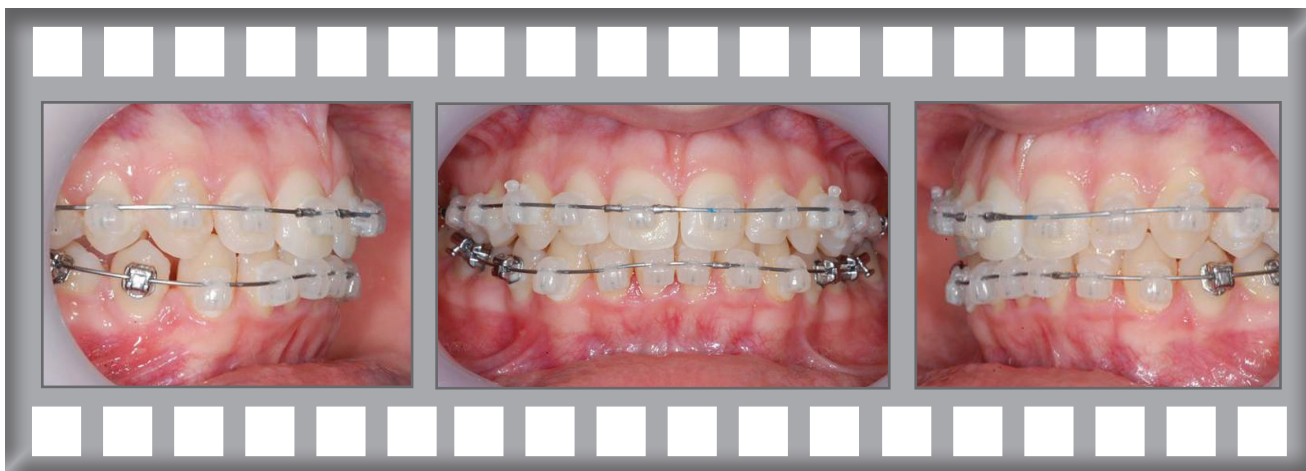## Damon Clear

At 23 Holly was concerned about the slight malalignment of her anterior teeth.

Treatment was complete after 10 months using the Damon Clear system.



Dr Horobin used Damon Clear upper and lower fixed braces.



Progress after 3 months.



Before

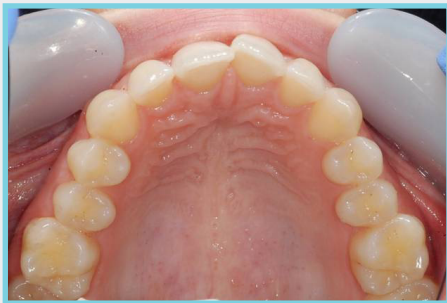

After

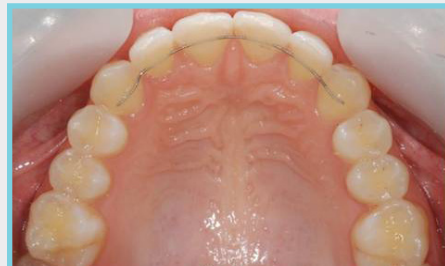Holly was delighted with her result.

Treatment was complete after 10 months using the Damon Clear system without extractions.

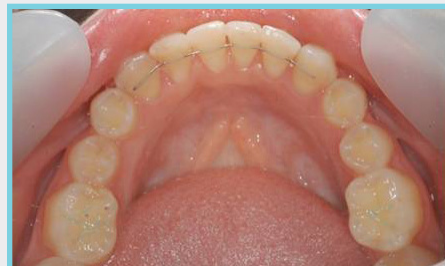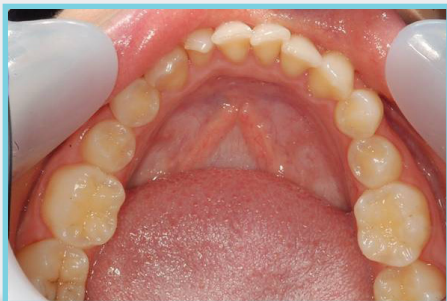BEFORE



AFTER

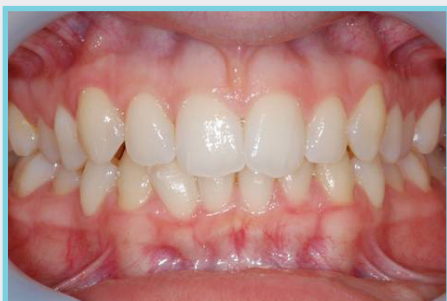

Note Fixed Retainer

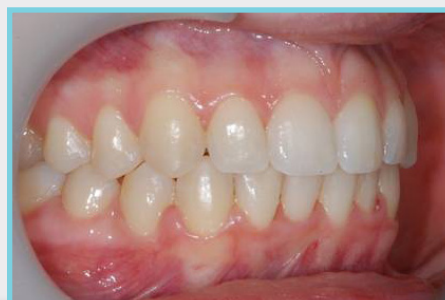
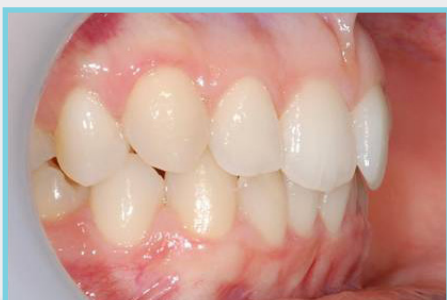
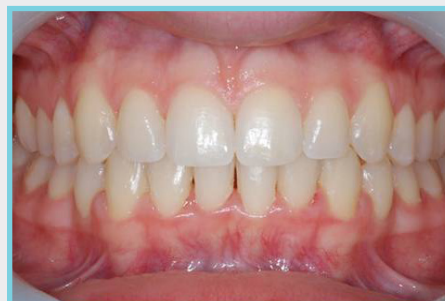Note Fixed Retainer

BEFORE



AFTER



# Damon Clear Case History