

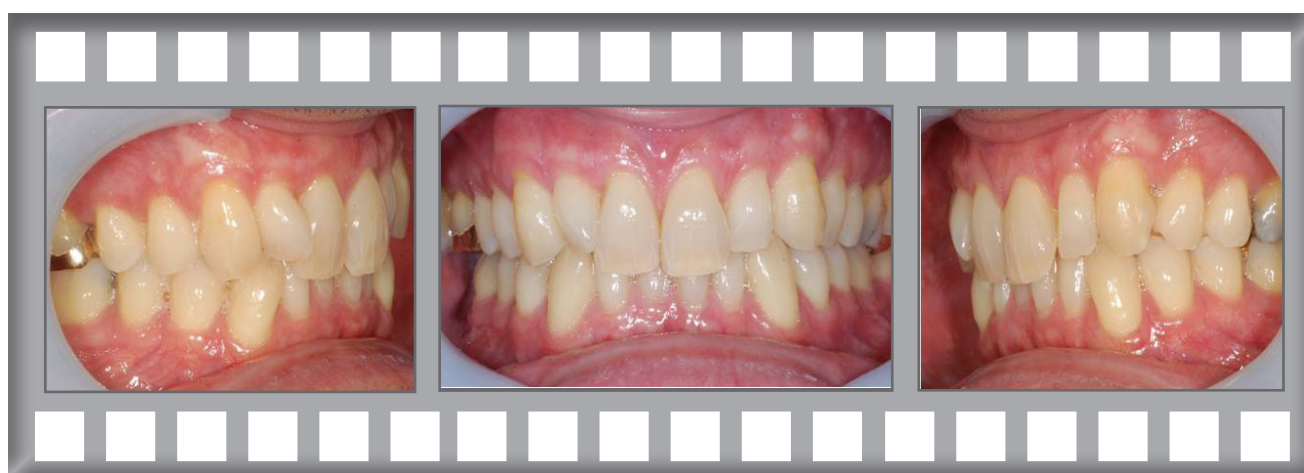Damon Clear

At 55 our principal Orthodontist was concerned about his own irregular teeth.

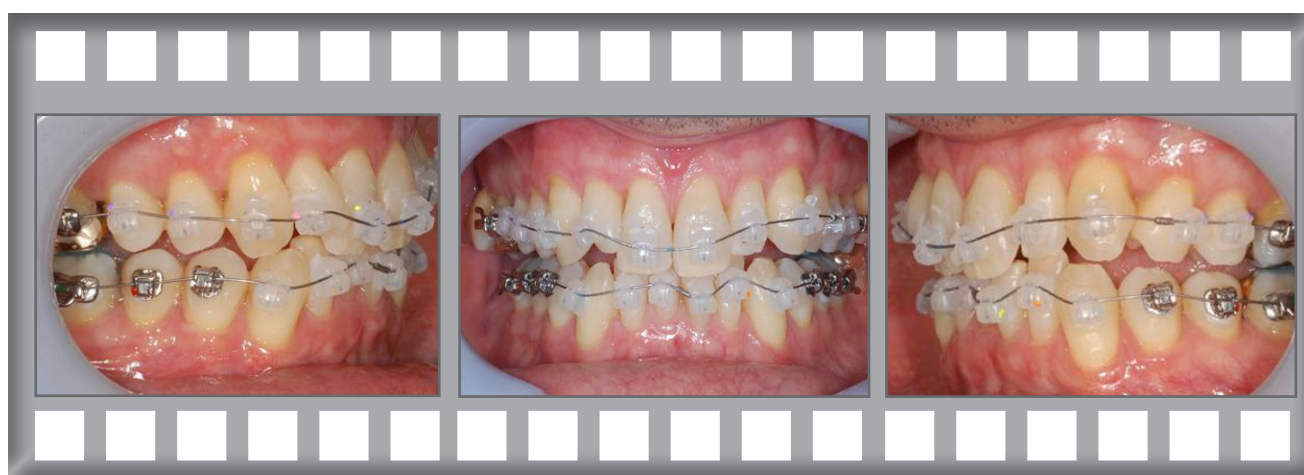Dr Horobin used the Damon Clear brace (on himself!) without extractions.



David

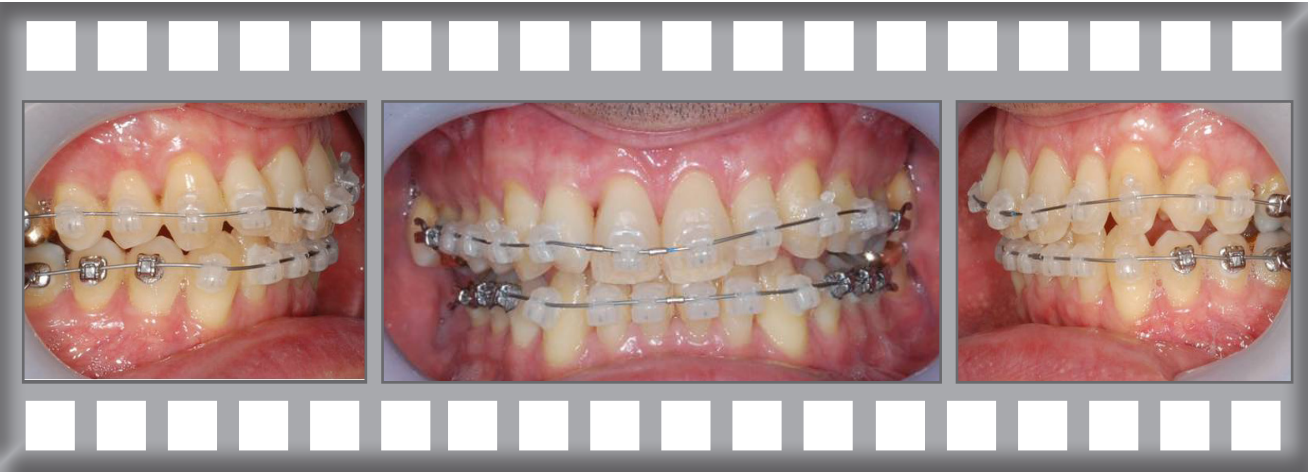


The lower teeth were irregular and the uppers were slightly twisted.

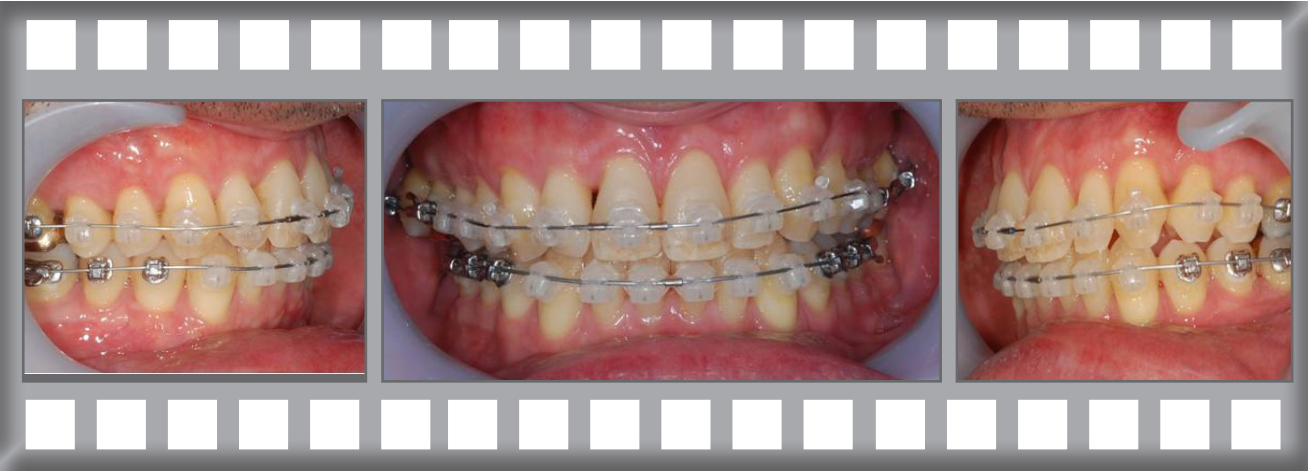


Dr Horobin used the Damon Clear system.

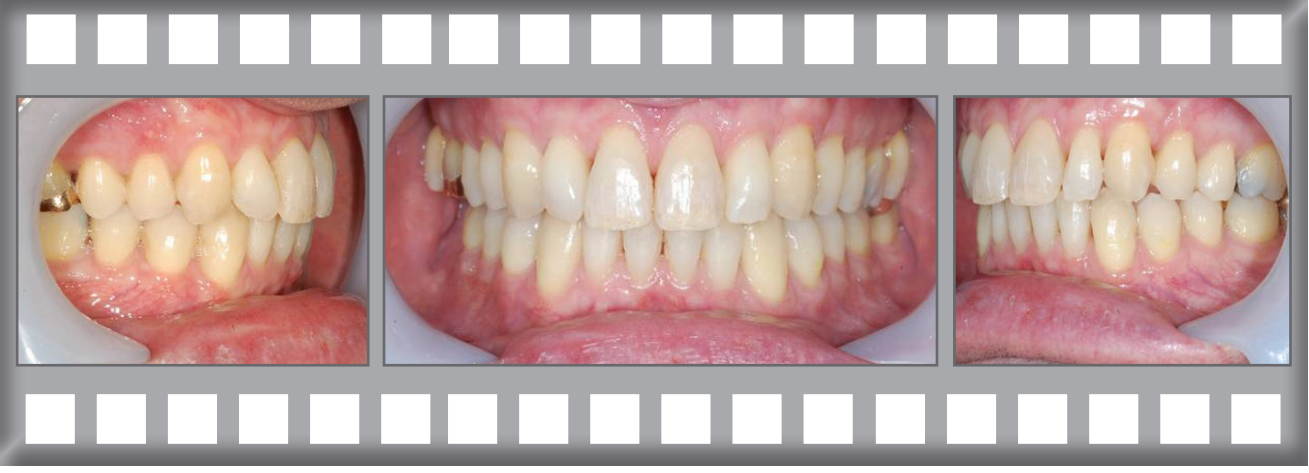Progress after 2 months.



Progress after 4 months.



The finished result after just 8 months.



Damon Clear Case History



Before

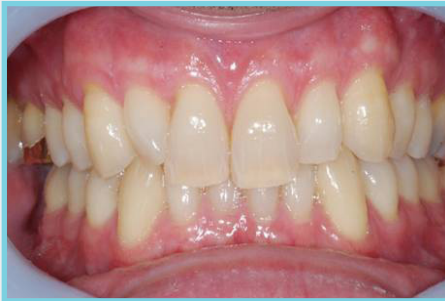

After

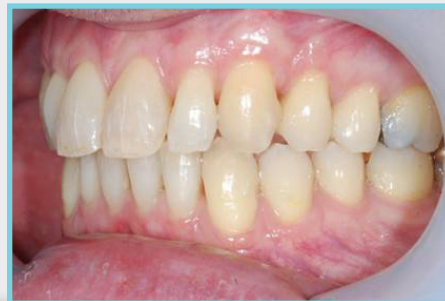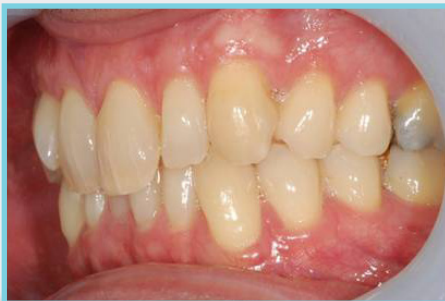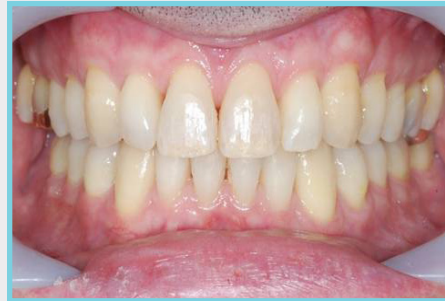Treatment was complete after 8 months using the Damon Clear system without extractions.

With grateful thanks to Sarah and Marie, two of our Therapists, who carried out the treatment.

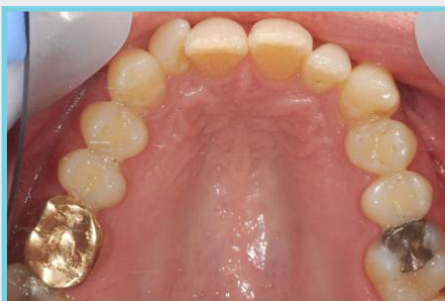Before



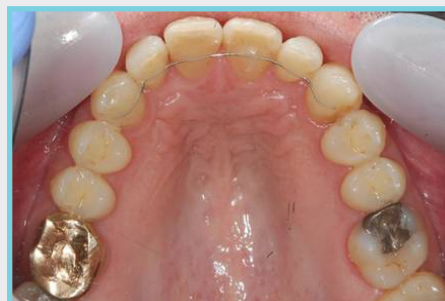After



Before



After



Note fixed retainers

