

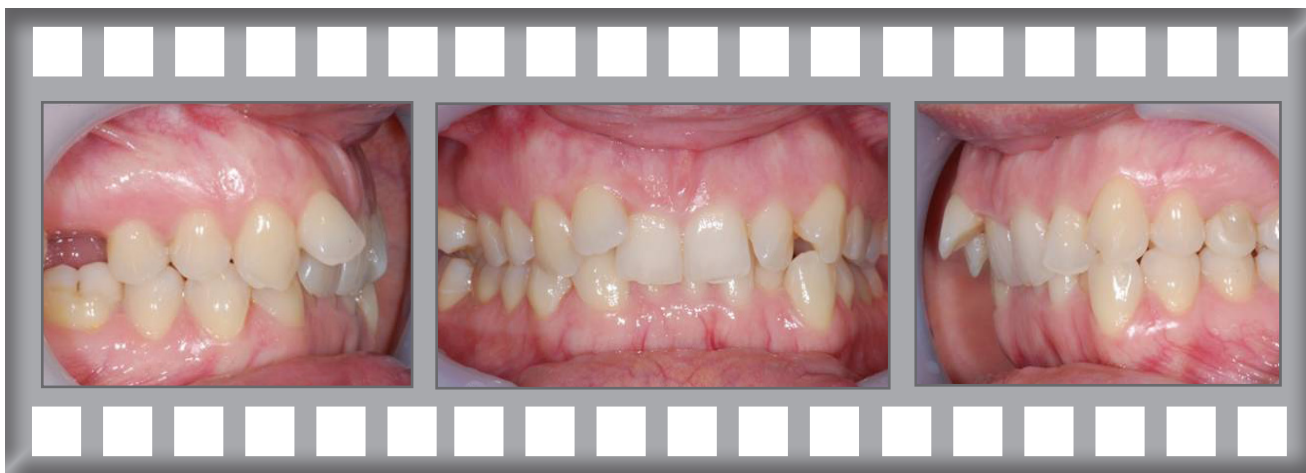Damon Clear

At 35 Andrea was concerned about her irregular front teeth.

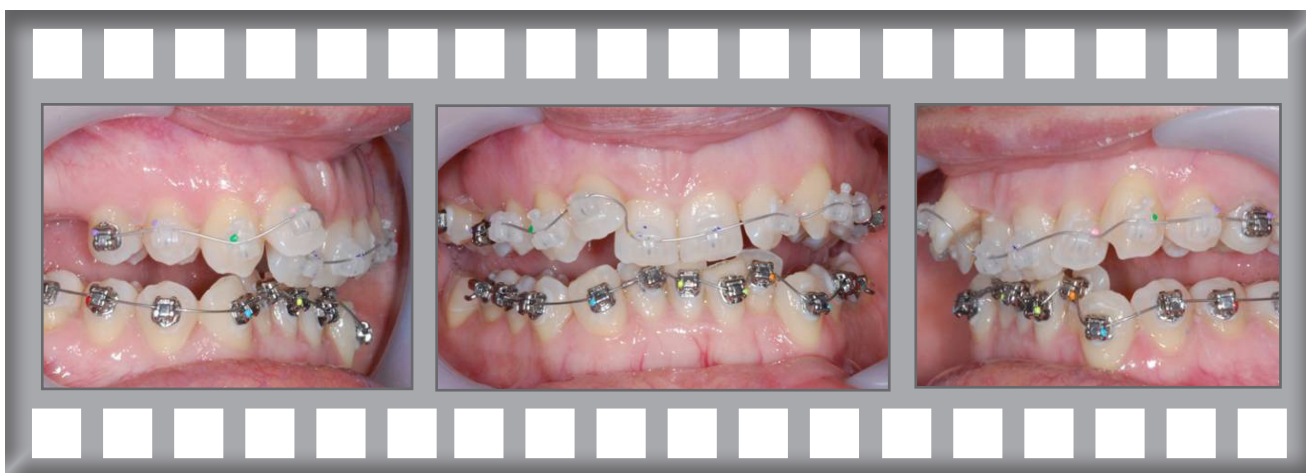Treatment was complete after 21 months using the Damon Clear system.



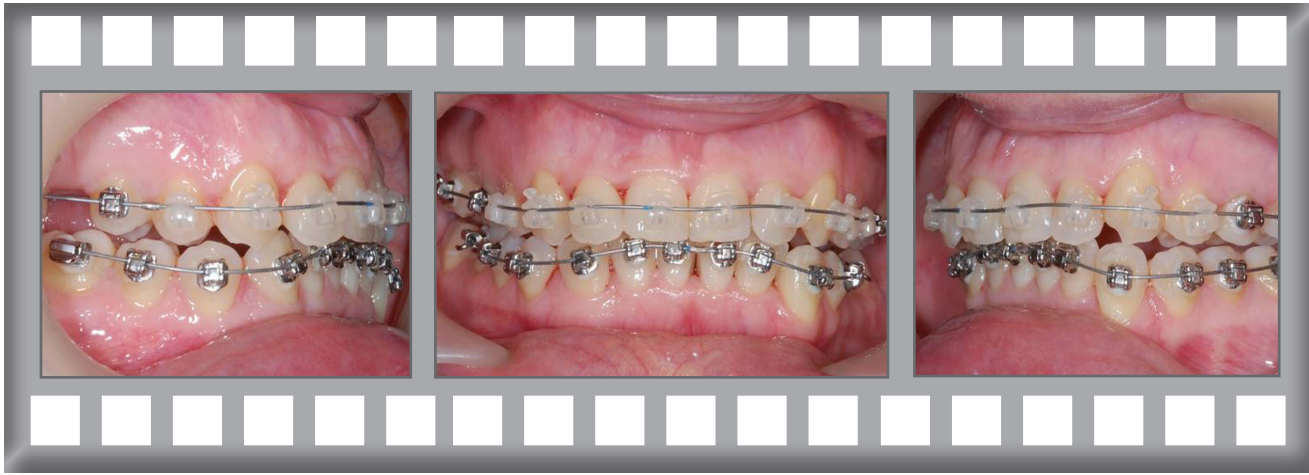Andrea



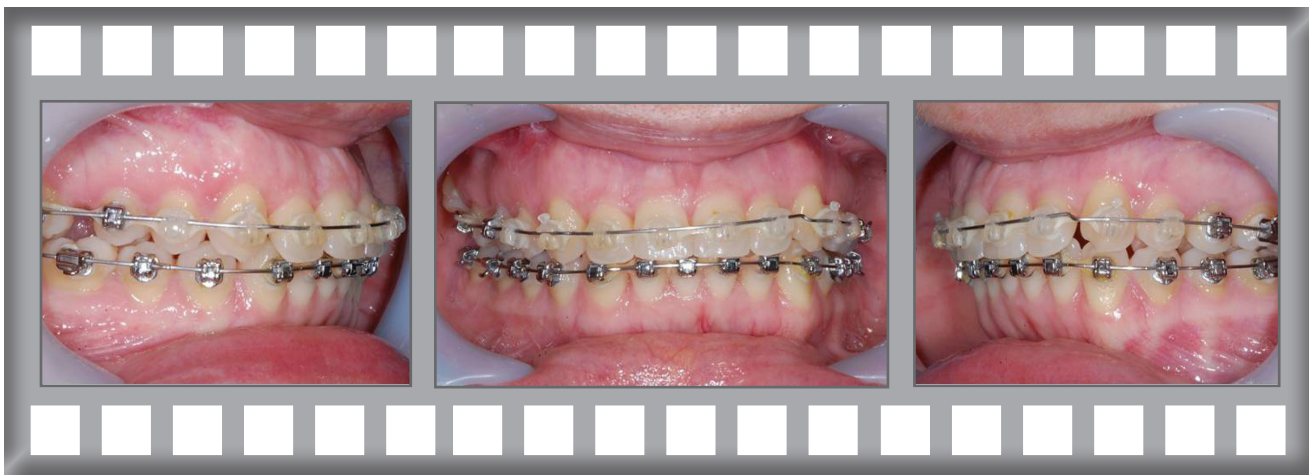
Dr Horobin used Damon Clear upper and lower fixed braces with no extractions.



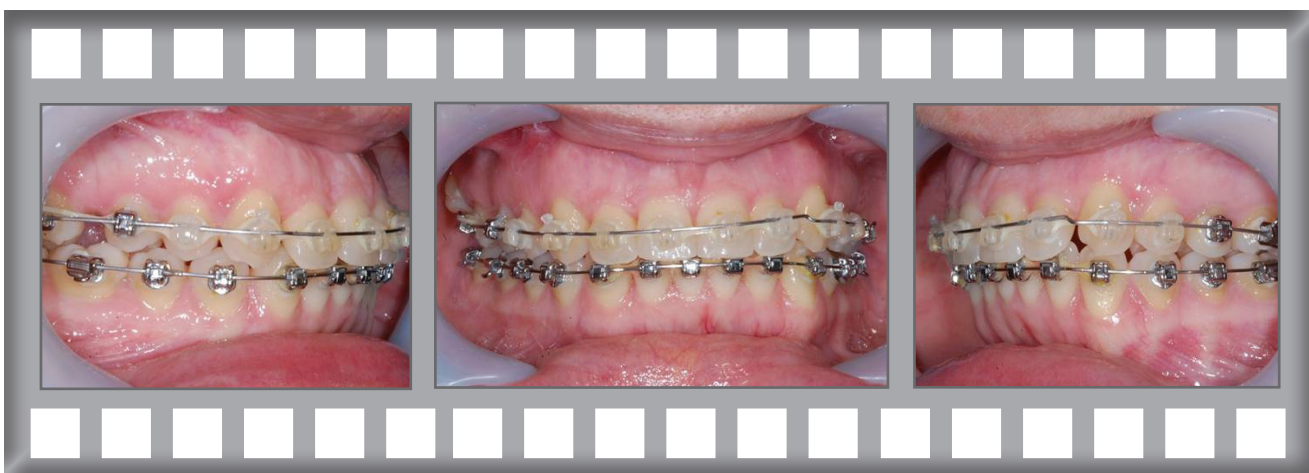
Progress after 3 months.



Progress after 13 months.



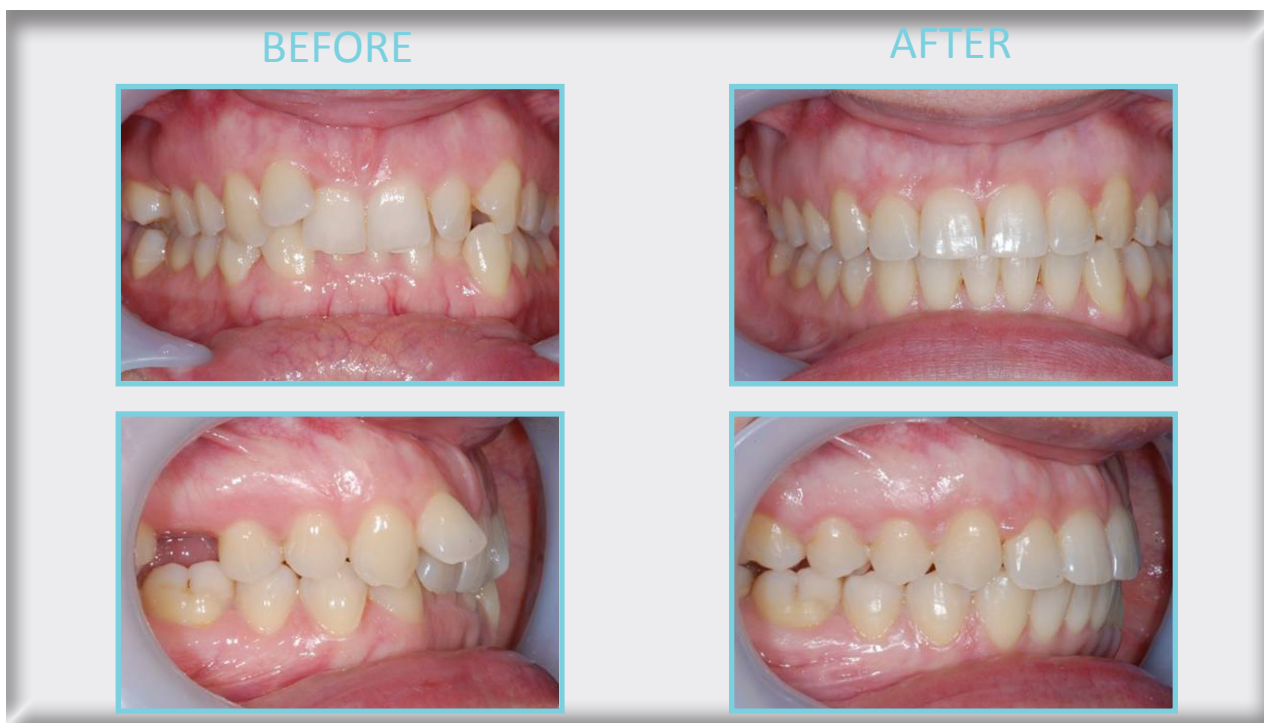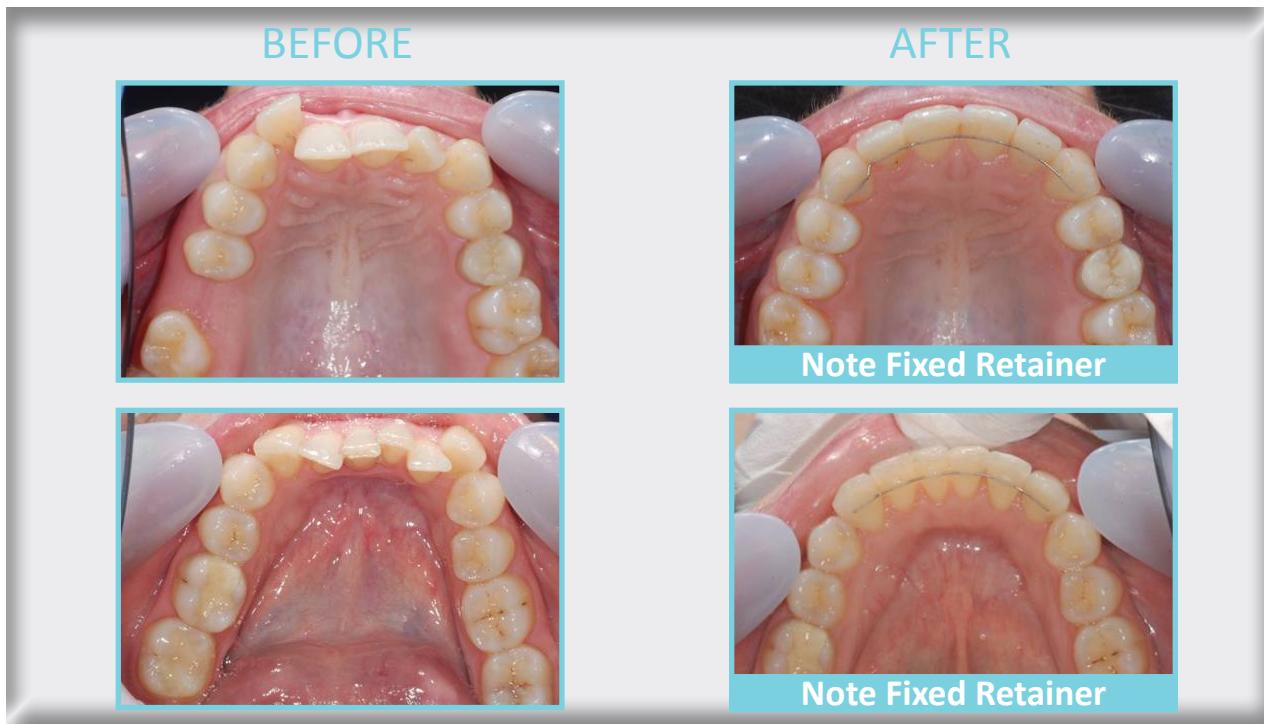
Progress after 16 months.





Andrea was delighted with her result.

Treatment was complete after 21 months using the Damon Clear system without extractions.



Damon Clear Case History